



## Case report

### Venting incision of cornea and intracameral air repairs Descemet membrane detachment three months after phacoemulsification surgery

Mae-Lynn Catherine Bastion<sup>1</sup> , Yiing Cheong Wong<sup>2,3</sup>, Aida Zairani Zahidin<sup>4</sup>

<sup>1</sup> Department of Ophthalmology, National University of Malaysia Medical Centre, Kuala Lumpur, Malaysia

<sup>2</sup> Muthusamy Virtual University

<sup>3</sup> Wong Yiing Cheong Specialist Eye Centre, Kuala Lumpur, Malaysia

<sup>4</sup> Gleneagles Hospital Kuala Lumpur, Kuala Lumpur, Malaysia

#### ARTICLE INFO

##### Article history

Received 19 February 2019

Accepted 5 February 2020

Available online 26 May 2020

##### Keywords

Intraocular injections

Anterior chamber

Corneal injuries

##### Doi

<https://doi.org/10.29089/2020.20.00106>

##### User license

This work is licensed under a Creative Commons Attribution – NonCommercial – NoDerivatives 4.0 International License.



#### ABSTRACT

**Introduction:** Cataract surgery is one of the most commonly performed operations in the world. Descemet membrane detachment (DMD) is a potentially blinding complication of this operation.

**Aim:** To describe the successful treatment of DMD three months after initial surgery.

**Case study:** Retrospective case review.

**Results and discussion:** A 69-year-old bilateral pseudophakic man presented with persistent blurring of vision in his left eye despite having undergone left eye cataract surgery for phacomorphic glaucoma 10 weeks previously. Examination and anterior segment optical coherence tomography (AS-OCT) showed left descemet detachment involving the visual axis. Despite the long duration, he underwent left cornea venting incision combined with intracameral air injection which successfully improved the cornea clarity and reattached the descemet on AS-OCT. When this was combined with treatment for cystoid macula oedema, he was able to attain best corrected visual acuity of 6/6-2, N5 3 months after the cornea venting procedure.

**Conclusions:** Treatment with cornea venting incision combined with air injection is an effective method of reattaching the descemet membrane in late presentation of DMD.

## 1. INTRODUCTION

Descemet membrane detachment (DMD) was first described by Weve in 1927.<sup>1</sup> It is a serious complication of surgical procedures involving anterior chamber manipulation because DMD is potentially blinding when the area of detachment involves the visual axis. It is most commonly seen now in patients who have undergone cataract surgery. Undiagnosed it can lead to cornea decompensation, cornea oedema and scarring.<sup>2</sup> DMD which does not involve the visual axis can be observed and rarely progresses.

Risk factors for DMD include extracapsular cataract surgery, manual small incision cataract surgery and cases performed by trainees.<sup>3</sup> DMD which appears as persistent corneal oedema post-surgery can be mistaken for early bullous keratopathy which delays the diagnosis and treatment.

Late onset DMD has also been described. Gatzoufas et al. describe a case of bilateral DMD that occurred 4 weeks after consecutive uneventful cataract surgery.<sup>4</sup> This was successfully repaired with gas injection. Unusually late presentation has also been described by Morkin M et al. in a patient who had cataract surgery almost 11 months previously. This patient eventually required penetrating keratoplasty as gas injection was not successful.<sup>5</sup> The treatment for DMD later than 4 weeks after initial surgery is still unclear.

## 2. AIM

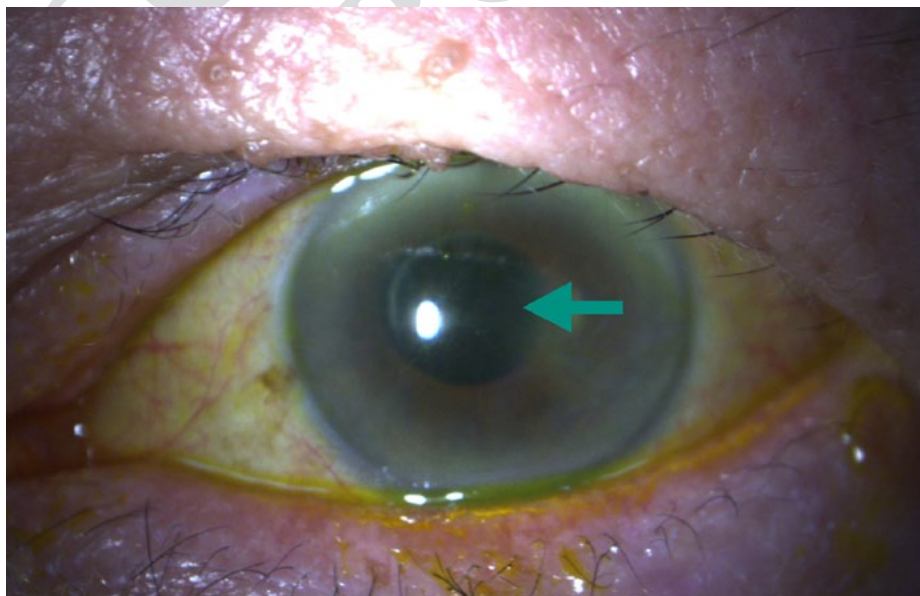
Hence the aim of this retrospective case report is to describe a case of successful treatment of DMD as long as 3 months after initial surgery.

## 3. CASE STUDY

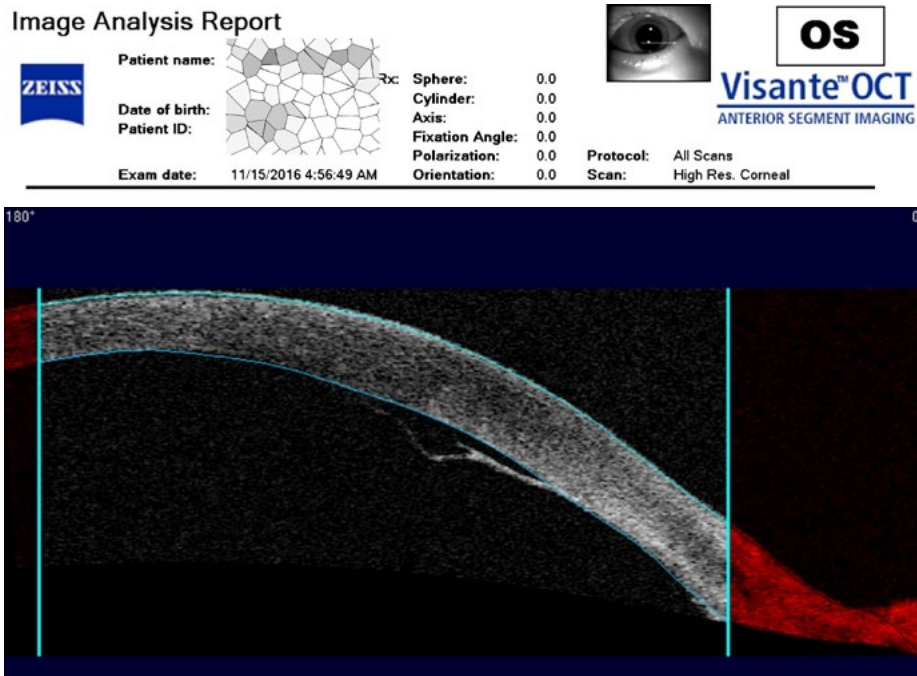
A 69-year old Chinese man, presented with left eye persistent blurring of vision 10 weeks after uneventful left phacoemulsification surgery with lens implantation. The blurring of vision had worsened and then remained constant. Prior to the cataract surgery he had complained of left eye severe eye pain and swelling for 3 days suggestive of phacomorphic glaucoma. He had also undergone right uneventful phacoemulsification surgery with intraocular lens implant 6 years previously with good postoperative vision. Prior to the right eye surgery, he complained of painless progressive blurring of right eye vision for 6 months. He was otherwise well with no known medical illness. He was not on any anti-glaucoma medications.

On examination, his vision was 6/9.5, N8 oculus dexter (OD) and 6/19, N36 oculus sinister (OS). Examination of the right eye showed a clear cornea with Descemet fold seen at the main incision. There was however no cornea oedema or guttata. Examination of the left cornea revealed Descemet's detachment extending from the main cornea incision situated temporally with localised, central cornea oedema and descemet fold (Figure 1). There was no anterior chamber inflammation and intraocular pressures were normal. Both intraocular lenses appeared stable. At this point, the rest of the ocular examination was also normal.

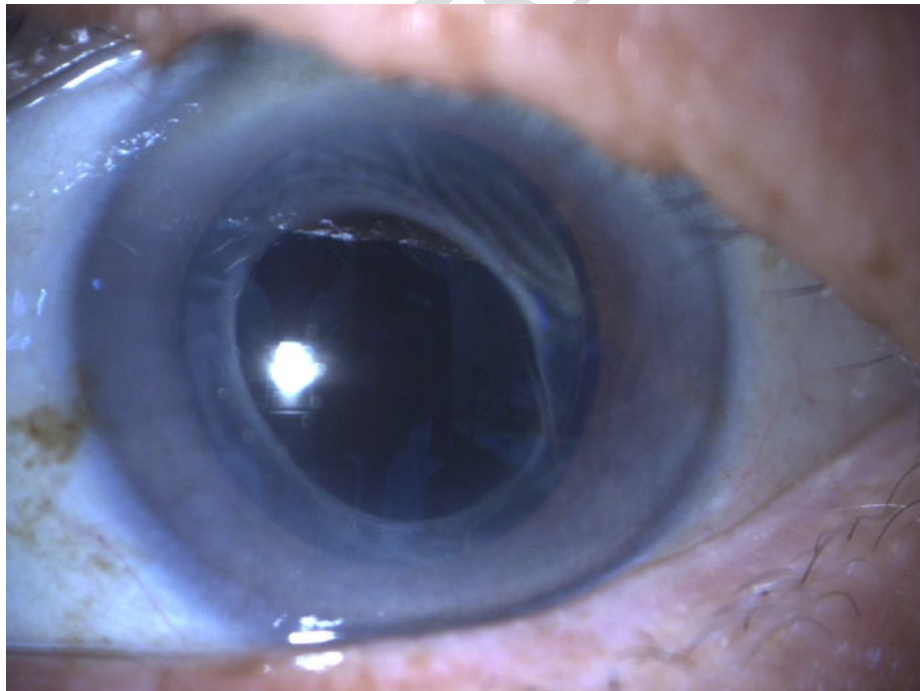
Anterior segment optical coherence tomography (ASOCT) confirmed the presence of a persistent DMD with planar configuration (Figure 2). He then underwent left eye cornea venting incision with air injection following the technique first described by Weng et al. in 2017.<sup>6</sup> Given the long duration prior to treatment, the pre-descemet fluid was expected to be viscous. This technique was selected as it had been successful in a case of severe DMD with one failed descemetotomy.



**Figure 1.** Anterior segment photograph of the left eye showing DMD extending from the main cornea incision situated temporally with localised, central cornea involvement with oedema and fold in the Descemet (blue arrow). Rest of the cornea is clear and there is an intraocular lens visible behind the pupil which is pharmacologically mid-dilated.



**Figure 2. ASOCT report showing persistent DMD with planar configuration at the temporal aspect of the left eye.**



**Figure 3. Anterior segment photograph of the left eye at 2 months follow up showing clearer cornea and resolution of detachment and oedema.**

The procedure was performed as follows. The anterior chamber was completely filled with filtered air via a limbal paracentesis created with a 15 degree blade (Alcon Model: 8065921501, Texas, USA) located 180 degrees from the location of the detachment, in this case, at 10:00 o'clock. This is followed by puncture of the peripheral cornea using a 23-gauge needle at the area of greatest fluid depth overlying the detachment to drain the pre-descemetic fluid. A small

amount of fluid was noted to ooze from this partial thickness incision. The anterior chamber air is topped up once more. Half an hour later, the intracameral air is partially released via the paracentesis to avoid pupillary block and the patient is instructed to remain supine for 24 h.

The patient was monitored for complications of the intracameral air bubble which could result in pupillary block and appositional angle closure which were not observed. He

was treated with routine postoperative topical antibiotics, guttae ciprofloxacin HCl 0.3% QDS (Ciloxan, Alcon, Texas, USA) and topical steroids, guttae dexamethasone 0.1% QDS (Maxidex, Alcon, Texas, USA).

Day 5 postoperatively, his visual acuity had improved to 6/15, N36 OS as the air bubble had completely resorbed by this time. However, the slit lamp examination showed there was a small bubble of retained fluid and the cornea was still hazy in the periphery. Unfortunately, at one month follow-up his vision was 6/60, N48, despite the cornea clarity improving in the center with minimal residual fluid in the area of DMD. A macula spectral domain OCT (SDOCT) was performed to investigate this visual deterioration and left cystoid macula oedema (CMO) was detected with central foveal thickness of 500  $\mu\text{m}$ . He was treated with topical nonsteroidal anti-inflammatory agent, guttae ketorolac bromethamine 0.5% TDS (Acular, Allergan, Dublin, Ireland) for 12 weeks. By 2 months following the procedure, his vision had improved and there was clear cornea with no obvious fold seen clinically and a small stromal scar where the venting had been performed (Figure 3). Repeat macula SDOCT showed normal fovea contour with central foveal thickness of 313  $\mu\text{m}$ . Best corrected visual acuity 3 months after the treatment was 6/6 minus 2, N5.

#### 4. RESULTS AND DISCUSSION

The incidence of DMD following phacoemulsification is 0.04% which is lower than other types of cataract surgery with larger incisions.<sup>3</sup> Risk factors in this man, we postulate to include corneal oedema and hazy cornea due to raised intraocular pressure secondary to cataractous lens during the phacoemulsification surgery. Another risk factor is a possible predisposition for DMD as the cornea incision in his asymptomatic right eye also had a small Descemet fold with detachment. Bilateral DMD have been described previously in literature.<sup>7</sup> According to Kansal et al., some patients may have an abnormality in the fibrillary stromal attachment to Descemet membrane predisposing them to DMD.<sup>7</sup>

DMD is usually detected early and is best treated early. Conventional treatment is intracameral filtered air injection during the surgery or in the immediate postoperative period especially if the detachment is large or involves the visual axis.<sup>1</sup> Small detachments near the wound may be observed. However even small detachments which involve the visual axis such as in this patient will impair the vision and need further action.

It can be diagnosed clinically by careful high magnification examination of the cornea at the slit lamp with a narrow beam of light focused to examine the layers of the cornea. However, it may also be difficult to diagnose clinically if the cornea is very oedematous. In such situations, ASOCT is extremely useful to confirm the diagnosis and monitor the treatment response. A suspicion of the condition is also important as it may be misdiagnosed as postoperative corneal oedema or even cornea decompensation resulting in

unnecessary cornea transplant surgery. This is particularly well illustrated by this case in which the treatment was only instituted in the 3rd postoperative month.

Successful conservative treatments for DMD include observation,<sup>8</sup> isoexpansile concentrations of sulphur hexafluoride ( $\text{SF}_6$ ) (20%)<sup>9</sup> or carbon perfluoropropane ( $\text{C}_3\text{F}_8$ ) (14%) injected intracamerally,<sup>2</sup> air injection, viscoelastic injection<sup>8</sup> and most recently, air or gas in combination with cornea venting incisions.<sup>6</sup> In the presence of rolled Descemet membrane, observation is not likely to be successful and intervention with viscoelastic such as 1.8% sodium hyaluronate in combination with air injection may be necessary to unroll the flap.<sup>8</sup> Failure of these more conservative measures would necessitate cornea transplantation.

$\text{SF}_6$  gas has also been used in descemetopexy following DMD.<sup>4,5</sup> Morkin et al. used 0.25 mL of 100 %  $\text{SF}_6$  in an attempt to repair the DMD but this was unsuccessful in the case they described. Generally concentrations of 15%–20%  $\text{SF}_6$  have been used to provide longer tamponade.<sup>4,9</sup> However, more recent literature suggests that it is effective in DMD detected early and less so in DMD detected later. A retrospective case series of 60 patients by Jain et al. found a 95-percent success rate for air or gas injection for DMD.<sup>10</sup> The study concluded that air was preferred because it seemed more efficacious than  $\text{C}_3\text{F}_8$  gas and reduced the risk of pupillary block.<sup>7</sup> Poorer visual outcome was associated significantly in this study with prolonged duration between DMD detection and descemetopexy. Our case illustrates that even late cases are amenable to successful treatment with air.

Another large series by Odayappan looking at air tamponade alone found a success rate of 71%.<sup>3</sup> A series on DMD by Sharma et al. proposed an anterior segment based OCT treatment algorithm.<sup>8</sup> Based on this algorithm, planar configuration of DMD on ASOCT in superior aspect of the cornea should be repaired with air injection. In our case, the detachment was peripheral and at the midsection of the cornea. Hence this algorithm could not be immediately applied. Furthermore, the onset was late.

Cornea venting incision was first described by Weng et al. in 2017 as a treatment for DMD and used in combination with air intracameral tamponade.<sup>6</sup> This alternative technique was described for severe DMD with one failed air descemetopexy. Cornea venting incision allows the trapped pre-descemet membrane fluid to be drained. Weng et al. successfully reattached the Descemet membrane in a 74-year-old woman who had one failed air descemetopexy for large DMD a week after phacoemulsification surgery.<sup>6</sup>

In this case, under sterile conditions, an anterior chamber (AC) limbal paracentesis was performed with a 23-gauge needle at 9:00 o'clock where there was no DMD. The AC is filled with air after some aqueous humour is gently expressed through this paracentesis. Then using the ASOCT result as a guide, another paracentesis at the highest point of the detached Descemet membrane was made with a 23-gauge needle as a venting incision. The needle stopped as soon as it penetrated the corneal stroma. Sterilized air

was again injected into the anterior chamber through the initial incision. The pre-descemetic fluid was noted to flow out through the venting incision. Half an hour later, some air was removed to prevent pupillary block postoperatively. The paracentesis wounds were unsutured. Dexamethasone 2 mg in 0.5 mL was injected subconjunctivally at the end of the procedure. Postoperatively, the patient was kept supine for the first 24 h.<sup>6</sup> Topical antibiotics and topical corticosteroids were administered postoperatively similarly to our case. Bhatia and Gupta described one case of DMD successfully repaired 3 weeks after surgery using Weng's technique after thrice failure of pneumatic descemetotomy.<sup>11</sup> Our case suggests that this method using air tamponade is successful as late as 12 weeks after surgery and should be attempted as a first procedure. Furthermore it is very simple to perform although care is needed to ensure the needle does not penetrate beyond the descemet layer. Although intraoperative anterior segment OCT is not available in our centre, this could represent a potential role for this investigation.

The outcomes for DMD treatment have been described to be effective with good visual outcome if the patient receives prompt treatment.<sup>11</sup> Our case suggests that late treatment in the third postoperative month is also amenable to existing treatment measures. However, unlike DMD that is seen immediately postoperatively, late detection of DMD means there is likely to be a fluid pocket which needs to be released before the DMD can be treated. This is why cornea venting incisions provide the added chance for success and should be performed. The air provides an internal tamponade force to reappose the layers and to cause egression of the trapped fluid.

Complications of air descemetotomy such as persistent DMD, corneal decompensation, appositional angle closure, pupillary block and uveitis were not seen in our case.<sup>3</sup> However, immediate reattachment of the DM was also not observed in our patient. Reattachment with alleviation of symptoms was only seen at 2 months after the procedure. This could be due to longer duration before intervention resulting in more viscous fluid. The late improvement in vision could also be due to the contribution of CMO which was detected only at a month after the procedure. Fortunately this was also successfully treated with NSAIDs. Nevertheless, the clearer cornea with treated CMO enabled the patient to get excellent postoperative vision at 2 months. Previous literature describes a mean duration of  $16.0 \pm 7.1$  days to resolution of DMD.<sup>12</sup> It is prudent to observe patients and re-intervene only when worsening detachment is seen on ASOCT.

## 5. CONCLUSIONS

- (1) DMD is a complication of phacoemulsification surgery despite the small incision size.
- (2) DMD causes blurred vision when it extends to involve the visual axis.
- (3) ASOCT is a very useful investigation for cornea oedema post cataract surgery regardless of the duration as it can diagnose DMD.

- (4) Treatment with cornea venting incision combined with air injection is an effective method of reattaching the Descemet membrane.
- (5) DMD can be repaired as late as three months after the initial surgery with cornea venting incision combined with air injection.

## Conflict of interest

No conflict of interest.

## Funding

None declared.

## Ethics

Patient's informed consent is obtained and kept in the patient's medical folder. Ethics committee approval was not required or sought as this is a retrospective single case report with no identifiers in the report.

## References

- 1 Assia EI, Levkovich-Verbin H, Blumenthal M. Management of Descemet's membrane detachment. *J Cataract Refract Surg.* 1995;21(6):714–717. [https://doi.org/10.1016/S0886-3350\(13\)80573-1](https://doi.org/10.1016/S0886-3350(13)80573-1).
- 2 Macsai MS, Gainer KM, Chisholm L. Repair of Descemet's membrane detachment with perfluoropropane (C3F8). *Cornea.* 1998;17(2):129–134. <https://doi.org/10.1097/00003226-199803000-00002>.
- 3 Odayappan A, Shivananda N, Ramakrishnan S, Krishnan T, Nachiappan S, Krishnamurthy S. A retrospective study on the incidence of post-cataract surgery Descemet's membrane detachment and outcome of air descemetotomy. *Br J Ophthalmol.* 2018;102(2):182–186. <https://doi.org/10.1136/bjophthalmol-2016-309766>.
- 4 Gatziofias Z, Schirra F, Löw U, Walter S, Lang M, Seitz B. Spontaneous bilateral late-onset Descemet membrane detachment after successful cataract surgery. *J Cataract Refract Surg.* 2009;35(4):778–7781. <https://doi.org/10.1016/j.jcrs.2008.09.034>.
- 5 Morkin MI, Hussain RM, Young RC, Ravin T, Dubovy SR, Alfonso EC. Unusually delayed presentation of persistent Descemet's membrane tear and detachment after cataract surgery. *Clin Ophthalmol.* 2014;8:1629–1632. <https://doi.org/10.2147/OPHTH.S65520>.
- 6 Weng Y, Ren YP, Zhang L, Huang XD, Shen-Tu XC. An alternative technique for Descemet's membrane detachment following phacoemulsification: case report and review of literature. *BMC Ophthalmol.* 2017;29:17(1):109. <https://doi.org/10.1186/s12886-017-0506-3>.
- 7 Kansal S, Sugar J. Consecutive Descemet membrane detachment after successive phacoemulsification. *Cornea.* 2001;20(6):670–671. <https://doi.org/10.1097/00003226-200108000-00025>.
- 8 Sonmez K, Ozcan PY, Altintas AG. Surgical repair of scrolled descemet's membrane detachment with intracameral injection of 1.8% sodium hyaluronate. *Int Ophthalmol.* 2011;31(5):421–423. <https://doi.org/10.1007/s10792-011-9473-5>.

- <sup>9</sup> Ellis DR, Cohen KL. Sulfur hexafluoride gas in the repair of Descemet's membrane detachment. *Cornea*. 1995;14(4): 436–437. <https://doi.org/10.1097/00003226-199507000-00014>.
- <sup>10</sup> Jain R, Murthy SI, Basu S, Ali MH, Sangwan VS. Anatomic and visual outcomes of descemetopexy in post-cataract surgery descemet's membrane detachment. *Ophthalmology*. 2011;120(7):1366-72. <https://doi.org/10.1016/j.ophtha.2012.12.043>.
- <sup>11</sup> Sharma N, Gupta S, Maharana P, Shanmugam P, Nagpal R, Vajpayee RB. Anterior Segment Optical Coherence Tomography-Guided Management Algorithm for Descemet Membrane Detachment After Intraocular Surgery. *Cornea*. 2015;34(9):1170–1174. <https://doi.org/10.1097/ICO.0000000000000514>.
- <sup>12</sup> Bhatia HK, Gupta R. Delayed-onset descemet membrane detachment after uneventful cataract surgery treated by corneal venting incision with air tamponade: a case report. *BMC Ophthalmol*. 2016;16:35. <https://dx.doi.org/10.1186%2Fs12886-016-0212-6>.

CORRECTED  
PROOF