




Case report

Granulomatosis with polyangiitis preceded with pyoderma gangrenosum in 41-year-old man

Ewa Malinowska¹, Agnieszka Owczarczyk-Saczonek² , Aleksandra Znajewska-Pander², Luiza Kańczuga-Koda³, Anna Doboszyńska¹, Waldemar Juliusz Placek²

¹ Department of Pulmonology, Faculty of Health Sciences, Collegium Medicum, University of Warmia and Mazury in Olsztyn, Poland

² Department of Dermatology, Sexually Transmitted Diseases and Clinical Immunology, School of Medicine, Collegium Medicum, University of Warmia and Mazury in Olsztyn, Poland

³ Pathomorphology Institute, The Białystok Oncology Centre, Poland

ARTICLE INFO

Article history

Received 12 January 2020

Accepted 9 February 2020

Available online 29 May 2020

Keywords

Granulomatosis with polyangiitis
Pyoderma gangrenosum
Diffuse alveolar hemorrhage

Doi

<https://doi.org/10.29089/2020.20.00107>

User license

This work is licensed under a Creative Commons Attribution – NonCommercial – NoDerivatives 4.0 International License.



ABSTRACT

Introduction: A coexistence of pyoderma gangrenosum (PG) and granulomatosis with polyangiitis (GPA) is observed extremely rarely. Some authors believe that skin ulcers like-PG may be a cutaneous manifestation of the GPA. They highlight the difficulties in assessing the histopathological picture: lack of clear diagnostic criteria for PG and recommendation to repeat biopsy in order to determine the proper diagnosis.

Aim: This article presents the case of 41-year-old man with GPA preceded with PG.

Case study: We present the case of 41-year-old male with GPA (with the occurrence of bleeding into the alveoli, bleeding from the lower gastrointestinal tract and renal involvement) preceded with PG. He also had pathergy test positive. The patient was treated with cyclophosphamide and corticosteroid with improvement.

Results and discussion: The presence of c-anti-neutrophil cytoplasmic antibodies (c-ANCA) levels, despite the classic image of PG with a characteristic histology, requires special observation of patients who may develop systemic GPA. Such patients should have frequent assessments of internal organ involvement. ANCA control is recommended since their concentrations correlate with disease activity. They may affect the re-activation and chemotaxis of neutrophils.

Conclusions: The presence of c-ANCA levels, despite the classic image of PG with a characteristic histology, requires special observation of patients who may develop systemic GPA.

*Corresponding author: Agnieszka Owczarczyk-Saczonek, Department of Dermatology, Sexually Transmitted Diseases and Clinical Immunology, School of Medicine, Collegium Medicum, University of Warmia and Mazury in Olsztyn, Wojska Polskiego 30, 10-229 Olsztyn, Poland. Phone: +4889 6786670.
E-mail address: agane@wp.pl.*

1. INTRODUCTION

Granulomatosis with polyangiitis (GPA) is a rare inflammatory disease of small and medium caliber vessels, which belongs to the group of anti-neutrophil cytoplasmic antibodies (ANCA)-associated vasculitis (AAV). AAV is a group of rare and potentially life-threatening diseases comprising 3 main conditions: GPA, microscopic polyangiitis (MPA), and eosinophilic GPA (EGPA).¹ GPA, formerly known as Wegener's granulomatosis is a systemic vasculitis that classically manifests as necrotizing granulomas of the upper and lower respiratory tract, kidneys, and blood vessels. However, it may affect any organ system, including the skin. The most common skin lesions are palpable purpura, necrotic ulcerations, papules and nodules with many histological patterns: leukocytoclastic vasculitis, granulomatous vasculitis, and palisading granulomas.^{2,3} The prevalence of GPA in Europe is 2.1–14.4 cases per million population per year.⁴ Skin lesions in the course of GPA are not characteristic symptoms, but may be present in as many as 15%–50% of cases of the disease and suggest cutaneous GPA as in the case described below.^{5,6}

Pyoderma gangrenosum (PG) is caused by immune system dysfunction, and particularly improper functioning of neutrophils which lead to the formation of skin ulcers. Its occurrence is estimated to be about 3–10 cases per million population per year.^{6,7} The etiology and pathogenesis of PG are not fully understood. This disease is often associated with other diseases such as inflammatory bowel diseases, hematological disorders (myeloma, myelodysplastic syndromes, lymphomas), rheumatic diseases and others. Concomitant systemic disease represents up to 50% of cases.⁷ Pathergy symptom, or the development of pyoderma gangrenosum-like lesions at the site of skin trauma, is demonstrated in 20%–30% of patients. Pathergy may create problems with wound healing, especially after surgical procedures, but it is helpful in diagnosis.⁸

A coexistence of pyoderma gangrenosum and GPA is observed rarely.

2. AIM

This article presents the case of 41-year-old man with GPA (with the occurrence of bleeding into the alveoli, bleeding from the lower gastrointestinal tract and renal involvement) preceded with PG.

3. CASE STUDY

41-year-old man, so far healthy, smoker (about 10 pack-years) was admitted to the Department of Dermatology on January 20, 2016 because of problems of the left shin ulcer healing since November 2015. According to the patient the ulcer was probably the effect of the insect bite. Because of an inflammatory tumor, the patient was referred to the Surgical Clinic, where the lesion was incised, and the doctor recognized the furuncle (Figure 1). The swab revealed *Escherichia coli*, *Morganella morgani* and the patient was treated with metronidazole, amoxicillin, co-trimoxazole orally. Despite surgical treatment, the ulcer was still developing with gradual expanding and no tendency to heal. The patient couldn't move. On the admission to the Department of Dermatology, the ulcerative lesion was 10 × 8 cm in dimension with a violaceous border that over hanged the ulcer bed and it was covered with muco-purulent content (Figure 2).

Laboratory tests revealed some abnormalities: ALT 92 U/L, AST 42 U/L, CRP 33.10 mg/L and erythrocyturia in urine analysis. The levels of creatinine, eGFR and proteinogram was normal. The antibody c-ANCA titer was 1 : 640 and p-ANCA 1 : 1280. The chest X-ray revealed

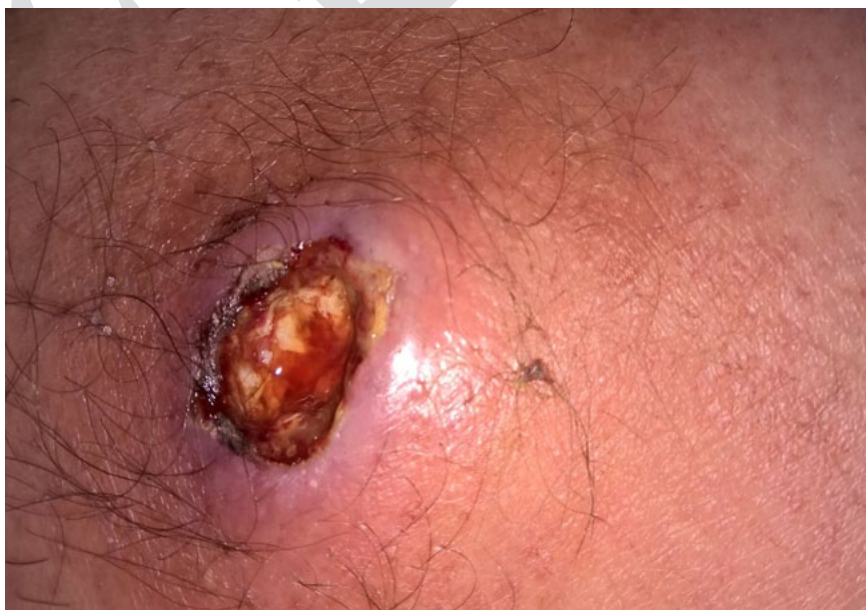

Figure 1. A lesion on the left shin after the surgical incision of a painful nodule in November 2015.

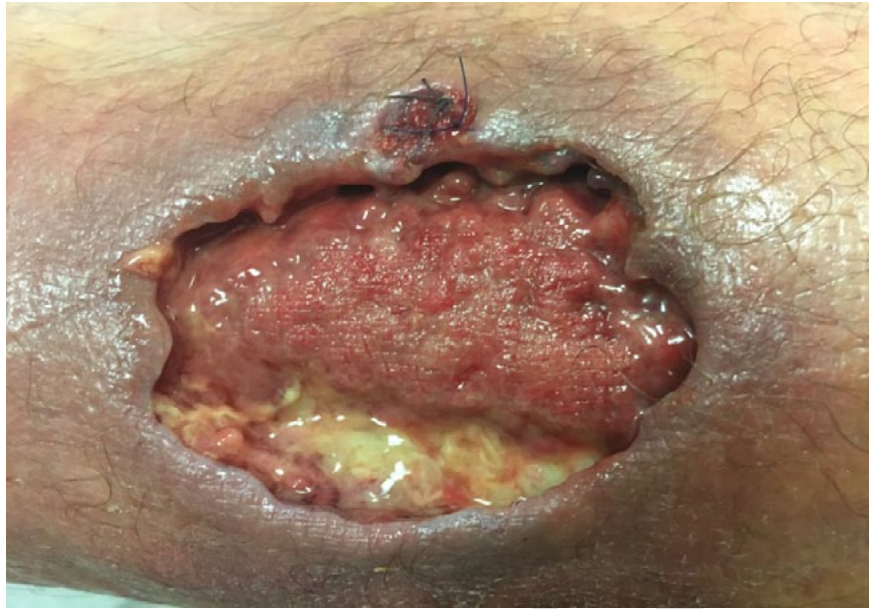

Figure 2. The ulcer during hospitalization in Department Dermatology: the pathergy symptom after biopsy.

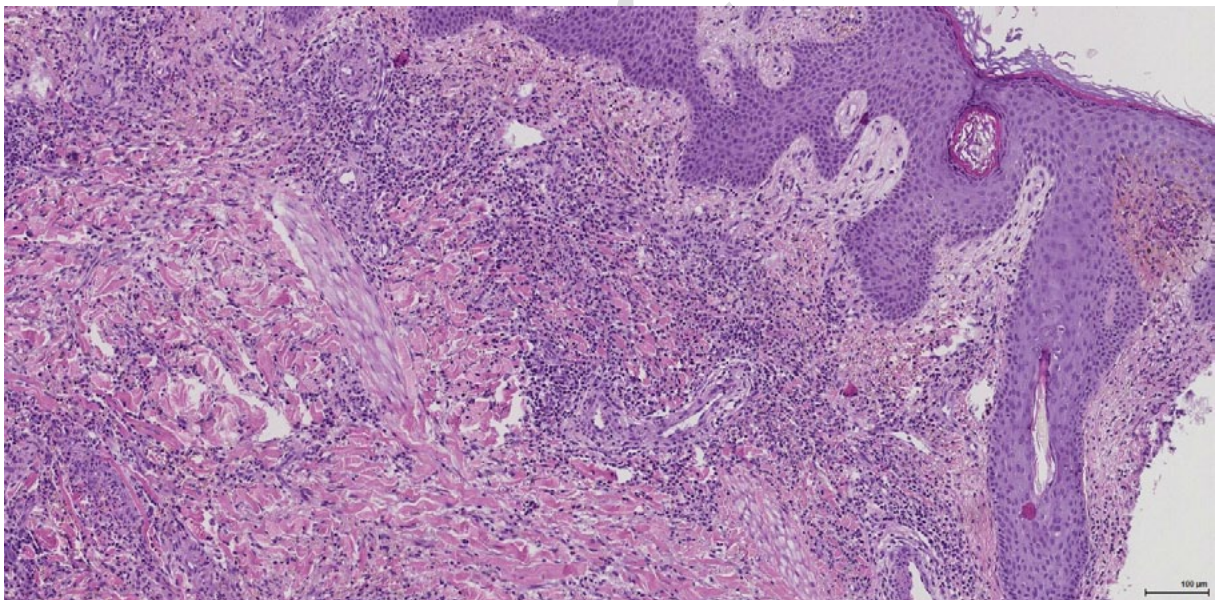


Figure 3. Histopathological result of a biopsy: Dense epidermal and dermal infiltration of inflammatory cells (HE, original magnification 100 \times).

band-like opacities at the base of the lungs, and abdominal ultrasound showed no abnormalities. In histopathological examination acanthosis, inflammatory infiltrates within the dermis with neutrophilic infiltration, lymphocytes, plasma cells, histiocytes and eosinophils, the proliferation of small blood vessels and escape of pigment were found (Figure 3). Moreover, a pathergy symptom was observed after the biopsy (Figure 2). The patient was consulted by a pulmonologist, ENT specialist, nephrologist, rheumatologist – they excluded GPA features.

Based on the clinical picture and histopathological examination pyoderma gangrenosum was diagnosed and patient was treated with cyclosporine 2 \times 100 mg (3 mg/kg),

prednisolone 0.5 mg/kg orally, 2 \times pentoxifylline 300 mg iv and topically with Aquacell Ag dressings.

The patient was discharged on February 10, 2016 with the improvement and the epithelization features in the ulcer with the recommendation of cyclosporine 2 \times 100 mg, methylprednisolone 1 \times 16 mg, pentoxifylline 2 \times 400 mg and topical Varicolast dressings.

On February 29, 2016 the patient was admitted to the Department of Pulmonology because of massive hemoptysis and dyspnea. Physical examination revealed tachypnea 30 breaths/min, tachycardia 110 bpm, auscultation revealed crackles all over the lungs. Laboratory tests showed anemia (Hgb 9.7 g/dL), elevated CRP (37.5 mg/L, N < 5 mg/dL),

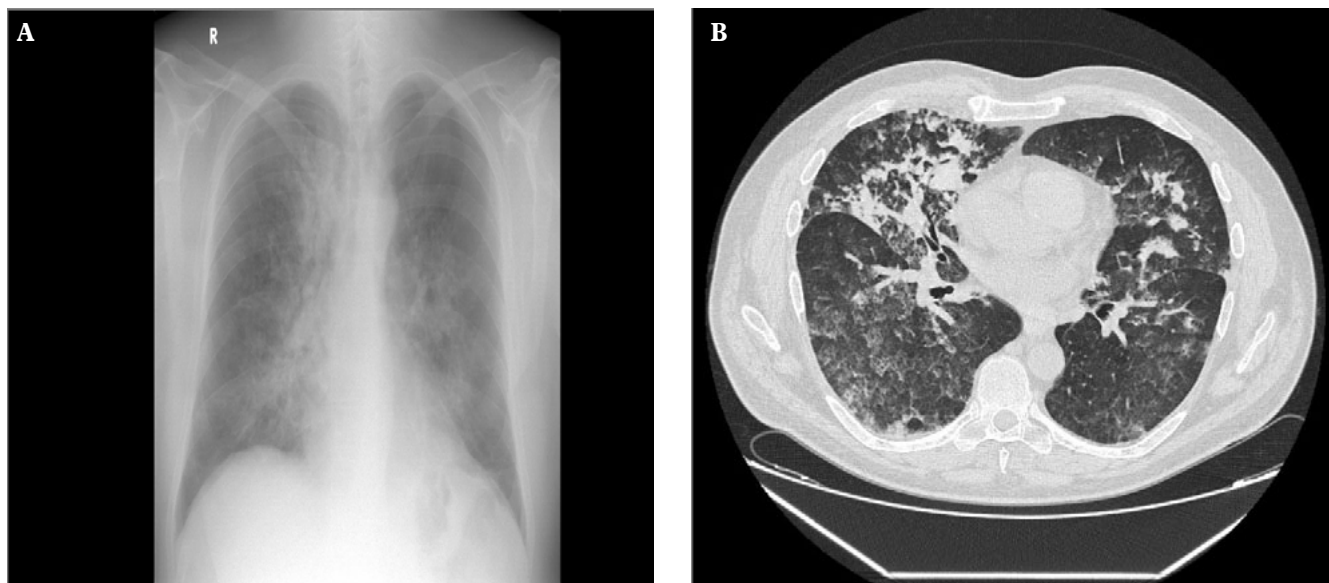


Figure 4. X-ray chest (A) and CT (B) on admission to the Department of Pulmonology: ‘frozen glass’ type infiltration in the parenchyma of both lungs – bleeding into the alveoli.

NT-pro BNP (908 pg/mL, $N < 125$ pg/L), IgE (392.12 IU/mL, $N < 100$ IU/mL) and hematuria in urine analysis. Leukocyte level, creatinine, and eGFR were correct. Moreover, c-ANCA concentration was 662.7 CU, p-ANCA 3.6 CU (negative ≤ 19.9 CU).

The diffusing capacity of the lung for carbon monoxide (DLCO) was 78% of predicted, indicating mild cognitive impairment. Other pulmonary function tests were not performed due to the serious condition of the patient. The chest X-ray and CT showed extensive ‘frozen glass’ type infiltration in the parenchyma of both lungs (Figure 4) – image corresponding with diffuse pulmonary hemorrhage into the alveolar spaces.

Based on the clinical picture and other tests GPA was recognized. In the early days of hospitalization bleeding from the lower gastrointestinal tract occurred twice. On the 1st day of hospitalization the patient was treated with cyclophosphamide orally at a dose of 2 mg/kg/day, bolus of methylprednisolone iv 1.0 g/day for 3 days, and then prednisone orally 1 mg/kg/day and administration of cyclophosphamide was continued. In addition, the patient received co-trimoxazole 960 mg orally, calcium and vitamin D₃ and had 2 units of red blood cells transfused. Clinical improvement, relief of dyspnea, hemoptysis were observed. On the 10th day of hospitalization bronchofiberscopy was performed which revealed: small amount of blood in the bronchial tree. Chest X-ray showed the improvement.

The patient was discharged with the recommendation cyclophosphamide treatment at a dose 2 mg/kg and prednisone 1 mg/kg/day.

After a month he was re-admitted to the Department of Pulmonology for follow-up examinations. The patient was in good condition, without any subjective symptoms and no hemoptysis. Ulceration of the left leg had partially healed.

Laboratory tests revealed the normalization of blood counts (Hgb 13.9 g/dL, WBC $8.9 \times 10^3/L$) and inflamma-

tory markers (CRP 1.9 mg/L). Still slightly elevated NT-pro BNP (136 pg/mL), hematuria (15–20 erythrocytes onto the field of view), the renal indicators (creatinine 1.06 mg/dL; $N < 0.9$ –1.3 mg/dL), eGFR 78 mL/min/1.73 m². c-ANCA antibodies decreased to 64.8 CU.

Pulmonary function tests revealed: spirometry and plethysmography – values within the normal range, DLCO – 88.37% of the predicted value, 6-minute walk test – ill defeated the 548 m, without desaturation. CT of the chest showed almost complete regression of lesions in the lung parenchyma.

Cyclophosphamide orally 2 mg/kg/day was continued and prednisone with reduced dose. After 3 months cyclophosphamide was discontinued and then the patient received azathiopryne 2 mg/kg/day.

4. RESULTS

The patient remains under control of the Department of Pulmonology. Currently there are no clinical features of active vasculitis and c-ANCA is negative. The ulcer on the lower leg was completely healed (Figure 5).

5. DISCUSSION

GPA skin symptoms, usually present as a purpura, occur in 50% of cases. The presence of circulating c-ANCA, involvement of internal organs (especially the lungs) and lack of neutrophilic infiltration in the biopsy of skin lesions can help to rule out and confirms the diagnosis of GPA, which simulates PG.^{5,7,9,10} When the clinical picture of these two entities is similar, there is a problem which is both diagnostic and therapeutic.⁶ Difficulties in assessing

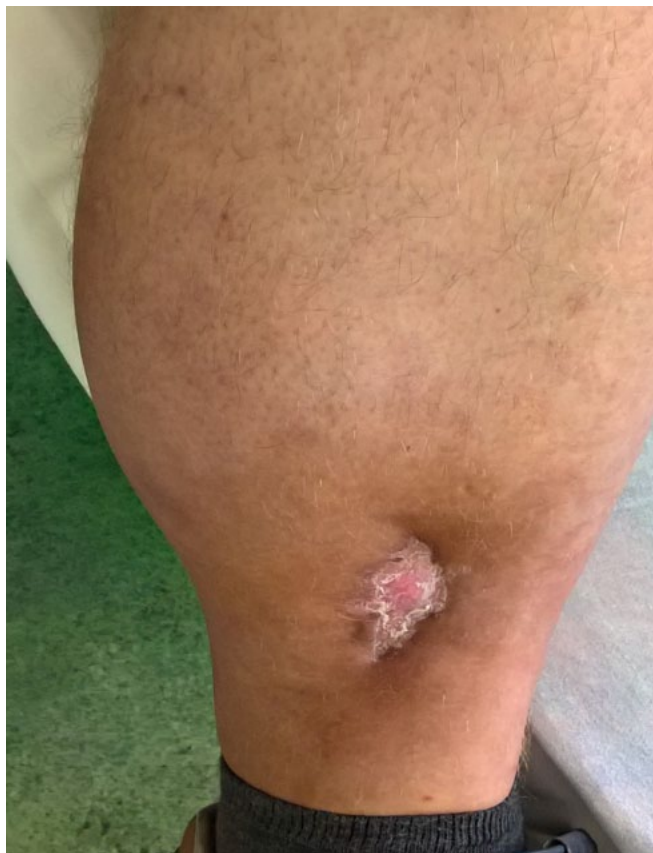

Figure 5. The leg ulcers has healed after the treatment - the day of discharge the patient from the Department of Pulmonology.

the histopathological picture such as lack of clear diagnostic criteria for PG and recommendation to repeat biopsy in order to determine the proper diagnosis.^{2,5,7} Therefore, epidemiological data regarding the actual co-existence of PG and GPA are controversial.^{9,11} Genoveese et al.⁹ reviewed 28 cases and established guidelines useful for distinguishing these conditions: (1) typical raised, erythematous-wavy edges are less visible in GPA ulcers compared to PG; (2) histology of early PG lesion consists mainly of neutrophilic inflammatory infiltrate; (3) c-ANCA positivity is compatible with GPA; (4) systemic involvement is common in GPA and rare in PG.^{9,2}

On the other hand, PG may, although rarely, occur secondary or coexist with GPA, as in the case of our patient. The literature identifies a variant of a malicious variety of PG, which according to some authors, is a skin manifestation of GPA. In both cases, histopathological examination reveals hemorrhagic necrosis, massive neutrophil infiltration, often resembling an abscess or cellulitis.^{6,12}

In a retrospective analysis of Daud et al., which evaluated 244 cases of ulcers, firstly identified as PG, a few of them developed GPA. In these patients, c-ANCA were positive in 81%.¹³ A multicenter French study examining the coexistence of neutrophilic dermatoses with ANCA in 17 patients, showed the most common relationship between PG and GPA (12 patients), much less with microscopic

vasculitis (MPA) (4 patients), and 1 case of eosinophilic GPA (EGPA)¹.

PG with lungs involvement and negative ANCA antibodies should be taken into account in the differential diagnosis. The lungs images show diffuse or multifocal opacities, interstitial pneumonia, pleurisy and cavitary pulmonary nodular lesions without necrosis.^{14,15} Lung damage can occur concurrently with skin symptoms or later. Differentiation should be based on the results of histological examination of biopsy carried out under the control of CT. Moreover PG is aseptic inflammation, without evidence of necrotizing granulomatous inflammation, and absence of c-ANCA.^{14,15}

In the case of the histopathological examination of our patient's leg ulcer, as well as a symptom pathergy (formation of ulcer at the site of skin injury) we observed characteristic picture for PG. According to our assessment, the patient developed generalized form of GPA with the lung, gastrointestinal tract and kidneys involvement.

Diffuse alveolar hemorrhage (DAH) occurs in approximately 25% of patients with severe GPA and is associated with higher mortality, due to diffuse pulmonary capillary damage.⁴ The diagnosis of DAH suggests the presence of hemoptysis, symptoms of respiratory failure, anemia and changes in radiological studies (X-ray, chest CT) – diffuse infiltrations like 'frosted glass' in the lung parenchyma, and in the bronchofiberscopy – bloody content of bronchoalveolar lavage (BAL).⁴ The mainstay of DAH treatment is the rapid administration of immunosuppressive agents (cyclophosphamide, prednisone, and rituximab) and in severe cases plasmapheresis.^{3,4,16,17} This treatment leads to remission of the disease in 90% of cases.¹⁸ There have been reports of the risks of developing interstitial pulmonary fibrosis following a history of bleeding into the alveoli of patients with the AAV.¹⁹

Presented patient received high doses of cyclophosphamide and corticosteroids from the first day of hospitalization which quick improvement of DAH symptoms. The patient still has mild impairment of DLCO. Due to the risk of interstitial pulmonary fibrosis it is advisable to assessment of lung function regularly.

Occupation of the gastrointestinal tract (particularly the small intestine and the colon) is rare in GPA. It clinically manifests by bleeding from the gastrointestinal tract. Histopathological lesions in the gut requires differentiation of other vascular inflammation, i.e. Crohn's disease and tuberculosis.^{20,21} In our patient episode of bleeding from the lower gastrointestinal tract occurred twice in the first few days of hospitalization. Due to the serious condition of the patient colonoscopy examination was not performed. The patient was referred for colonoscopy after the discharge from the hospital.

In patients with GPA despite the maintenance of immunosuppression, we should to reckon disease recurrent. The risk of relapse is approximately 47% within 18 months,²² and is greater in the presence of antibodies cANCA, with involvement of the lung and kidney.^{23,24} Therefore, these patients require especially careful and regular monitoring.

6. CONCLUSIONS

We presented the case of a patient due to a rare coexistence of pyoderma gangrenosum as a symptom heralding the development of the GPA. The presence of c-ANCA levels, despite the classic image of PG with a characteristic histology, requires special observation of patients who may develop systemic GPA. Such patients should have frequent assessments of internal organ involvement. ANCA control is recommended since their concentrations correlate with disease activity.² They may affect the re-activation and chemotaxis of neutrophils.¹

Conflict of interest

None declared.

Funding

None declared.

Ethics

Informed consent was obtained from patient for being included in the study.

References

- de Boysson H, Martin Silva N, de Moreuil C, et al. Neutrophilic dermatoses in antineutrophil cytoplasmic antibody-associated vasculitis: A French multicenter study of 17 cases and literature review. *Medicine (Baltimore)*. 2016;95(11):e2957. <https://doi.org/10.1097/MD.0000000000002957>.
- Tashtoush B, Memarpour R, Johnston Y, Ramirez J. Large pyoderma gangrenosum-like ulcers: A rare presentation of granulomatosis with polyangiitis. *Case Rep Rheumatol*. 2014;2014:850364. <https://dx.doi.org/10.1155/2014/850364>.
- Powers B, Uppalapati A, Gogineni S, Jamkhana ZA. Rituximab – a drug with many facets and cures: a treatment for acute refractory hypoxemic respiratory failure secondary to severe granulomatosis with polyangiitis. *Case Rep Crit Care*. 2013;2013:123134. <https://doi.org/10.1155/2013/123134>.
- Yates M, Watts RA, Bajema IM, et al. EULAR/ERA-EDTA recommendations for the management of ANCA-associated vasculitis. *Rheum Dis*. 2016;75(1):1583–1594. <http://dx.doi.org/10.1136/annrheumdis-2016-209133>.
- de Cambourg G, Mahe A, Banea S, et al. [Granulomatosis with polyangiitis revealed by a cutaneous ulceration mimicking a pyoderma gangrenosum: Two patients]. *Rev Med Interne*. 2016;37(9):632–635 [in French]. <https://doi.org/10.1016/j.revmed.2015.12.010>.
- Kędzierska K, Sindrewicz K, Smektała T, et al. Wegener's granulomatosis and pyoderma gangrenosum – rare causes of facial ulcerations. *Postepy Hig Med Dosw (Online)*. 2016;70:210–218. <https://doi.org/10.5604/17322693.1197372>.
- Schadt C, Callen J, O Ofori A. Pyoderma gangrenosum: Pathogenesis, clinical features, and diagnosis. *UpToDate*. 2015;23,2015.
- Wojas-Pelc A, Sułowicz J, Solecki R, Nowak W. Pathergy phenomenon in a patient with pyoderma gangrenosum – case report. *Post Dermatol Alergol*. 2009;26(6):550–554 [in Polish].
- Genovese G, Tavecchio S, Berti E, Rongioletti F, Marzano AV. Pyoderma gangrenosum-like ulcerations in granulomatosis with polyangiitis: two cases and literature review. *Rheumatol Int*. 2018;38(6):1139–1151. <https://doi.org/10.1007/s00296-018-4035-z>.
- Handfield-Jones SE, Parker SC, Fenton DA, Newton JA, Greaves MW. Wegener's granulomatosis presenting as pyoderma gangrenosum. *Clin Exp Dermatol*. 1992;17(3):197–200. <https://doi.org/10.1111/j.1365-2230.1992.tb00206.x>.
- Donmez S, Pamuk ON, Gedik M, A K R, Bulut G. A case of granulomatosis with polyangiitis and pyoderma gangrenosum successfully treated with infliximab and rituximab. *Int J Rheum Dis*. 2014;17(4):471–475. <https://doi.org/10.1111/1756-185X.12274>.
- Wollina U. Pyoderma gangrenosum—a review. *Orphanet J Rare Dis*. 2007;2:19. <https://doi.org/10.1186/1750-1172-2-19>.
- Daoud MS, Gibson LE, DeRemee RA, Specks U, el-Azhary RA, Su WP. Cutaneous Wegener's granulomatosis: clinical, histopathologic, and immunopathologic features of thirty patients. *J Am Acad Dermatol*. 1994;31(4):605–612. [https://doi.org/10.1016/s0190-9622\(94\)70224-1](https://doi.org/10.1016/s0190-9622(94)70224-1).
- Batalla A, Perez-Pedrosa A, Garcia-Doval I, González-Barcala FJ, Rosón E, de la Torre C. [Lung involvement in pyoderma gangrenosum: a case report and review of the literature]. *Actas Dermosifiliogr*. 2011;102(5):373–377 [in Spanish]. <https://doi.org/10.1016/j.ad.2010.12.008>.
- Bittencourt Mde J, Soares LF, Lobato LS, Mançano AD, Leandro HS, Fonseca DM. Multiple cavitary pulmonary nodules in association with pyoderma gangrenosum: Case report. *An Bras Dermatol*. 2012;87(2):301–304. <https://doi.org/10.1590/s0365-05962012000200018>.
- Klemmer PJ, Chalermkulrat W, Reif MS, Hogan SL, Henke DC, Falk RJ. Plasmapheresis therapy for diffuse alveolar hemorrhage in patients with small-vessel vasculitis. *Am J Kidney Dis*. 2003;42(6):1149–1153. <https://doi.org/10.1053/j.ajkd.2003.08.015>.
- Haupt ME, Pires-Ervoes J, Brannen ML, Klein-Gitelman MS, Prestridge AL, Nevin MA. Successful use of plasmapheresis for granulomatosis with polyangiitis presenting as diffuse alveolar hemorrhage. *Pediatr Pulmonol*. 2013;48(6):614–616. <https://doi.org/10.1002/ppul.22666>.
- Ishiguro T, Takayanagi N, Yamaguchi S, et al. Pulmonary capillaritis in Wegener's granulomatosis detected via transbronchial lung biopsy. *Intern Med*. 2012;51(8):905–909. <https://doi.org/10.2169/internalmedicine.51.6518>.
- West S, Arulkumaran N, Ind PW, Pusey C. Diffuse alveolar haemorrhage in ANCA-associated vasculitis. *Intern Med*. 2013;52(1):5–13. <https://doi.org/10.2169/internalmedicine.52.8863>.
- Qian Q, Cornell L, Chandan V, Hartman R, Caples S. Hemorrhagic colitis as a presenting feature of Wegener granulomatosis. *J Gastrointest Liver Dis*. 2010;19(4):445–447.
- Deniz K, Ozseker H, Balas S, Akpýnar E, Sökmensüer C. Intestinal involvement in Wegener's granulomatosis. *J Gastrointestinal Liver Dis*. 2007;16(3):329–331.
- Ozaki S. ANCA-associated vasculitis: diagnostic and therapeutic strategy. *Allergol Int*. 2007;56(2):87–96. <https://doi.org/10.2332/allergolint.R-07-141>.

- ²³ Pagnoux C, Hogan SL, Chin H, et al. Predictor of treatment resistance and relapse in antineutrophil cytoplasmic antibody-associated small-vessel vasculitis: comparison of two independent cohorts. *Arthritis Rheum.* 2008;58(9):2908–2918. <https://doi.org/10.1002/art.23800>.
- ²⁴ Lembicz M, Batura-Gabryel H, Nowicka A. Granulomatosis with polyangitis – clinical picture and review of current treatment options. *Pneumonol Alergol Pol.* 2014;81(1):61–73 [in Polish]. <https://doi.org/10.5603/PiAP.2014.0010>.

CORRECTED
PROOF