Polish Annals of Medicine

Journal homepage: https://www.paom.pl

Research paper

Congenital esophageal atresia treated with thoracoscopic approach – results of surgical treatment

Michał Puliński[1], *Wojciech Choiński*[1], *Marta Stęga*[2]

[1] *Department of Surgery, School of Public Health, Collegium Medicum, University of Warmia and Mazury in Olsztyn, Poland*
[2] *Pediatric Surgery Students' Association, Collegium Medicum, University of Warmia and Mazury in Olsztyn, Poland*

Article info

Article history
Received 8 December 2018
Accepted 18 April 2020
Available online 10 July 2020

Keywords
Surgery
Pediatric surgery
Esophageal atresia
Thoracoscopy
Esophageal atresia surgery
Congenital esophageal atresia

Doi
https://doi.org/10.29089/2020.20.00110

User license
This work is licensed under a Creative Commons Attribution – NonCommercial – NoDerivatives 4.0 International License.

BY-NC-ND

Abstract

Introduction: The first thoracoscopic esophageal atresia (EA) surgery in Poland was performed by Professor Dariusz Patkowski in 2005 in Wrocław. In the Clinical Ward of Pediatric Surgery and Urology, Regional Specialistic Children's Hospital in Olsztyn, thoracoscopic EA surgery was performed on 16 January 2009.

Aim: Data presentation on thoracoscopic treatment of congenital EA.

Material and methods: Between 2009 and 2018 in our Clinical Ward, 28 children (11 females and 17 males) diagnosed with EA underwent treatment. All patients presented with type III EA based on the Gross classification (lower tracheoesophageal fistula and atresia of the upper segment of the trachea) and 8 of them (29.6%) were diagnosed with coexisting diseases.

Results and discussion: The duration of the surgery was 70–290 minutes with a mean time of 180 minutes. Conversion was performed in 6 (21.4%) cases. Leakage of the lymph occurred in 2 (7.1%) cases . In 3 (10.7%) cases, a radiographic image showed leakage of the anastomosis. Only 1 (3.6%) patient needed reoperation due to re-canalization of tracheoesophageal fistula. Pneumothorax occurred in 2 (7.1%) cases. In total, 4 (14.3%) patients died and 23 (82.1%) patients required additional esophageal dilatation due to its narrowing.

Conclusions: The treatment results of thoracoscopic EA surgeries and undeniable advantages for the patient makes this technique a highly recommended method.

Corresponding author: Michał Puliński, Department of Surgery, School of Public Health, Collegium Medicum, University of Warmia and Mazury in Olsztyn, Okolna 3, 10-699, Olsztyn, Poland. Tel.: +48 609 059 037. E-mail: pulinski@wp.pl.

1. INTRODUCTION

During workshops of the 8th International Congress of Endoscopic Surgery in 1999 in Berlin, Germany, Prof. Steven Rothenberg performed the first thoracoscopic surgery of the esophageal atresia (EA) in a pediatric population.[1] In Poland, the first thoracoscopic surgery of EA was performed by Prof. Dariusz Patkowski in 2005.[2] Surgical technique and methods of restoring the patency of fistulas were ameliorated by Bax and van der Zee.[3] In the Clinical Ward of Pediatric Surgery and Urology, Regional Specialistic Children's Hospital in Olsztyn, Poland the first thoracoscopic surgery of EA took place on January 16, 2009. The advantages of this minimally invasive surgical technique include excellent visualization of the surgical field and a lower number of complications (compared with EA treated with thoracotomy). The long time required to learn the technique and high costs of the tools could be listed as disadvantages.

2. AIM

We would like to present the initial experience of our Clinical Ward, paying special attention to the safety and efficiency of EA treatment with the thoracoscopic approach.

3. MATERIAL AND METHODS

Cases of children diagnosed with EA and treated in the Pediatric Surgery Ward, the Intensive Care Unit (ICU), the Neonatal Pathology Ward, the Gastroenterological Outpatient Clinic and Surgical Outpatient Clinic in Olsztyn between 2009 and 2018 were taken as the research material. Retrospective analysis was used as a method. Special attention was paid to sex, body weight, defect type (using the Gross classification), coexisting disorders, time of the surgery, need of the conversion, length of stay in ICU, complications and reoperations. The study group consisted of 28 infants (11 females and 17 males) diagnosed with EA were treated using a thoracoscopic approach in the Pediatric Surgery Ward in Olsztyn in the period under study. The lowest body weight of a child treated with the thoracoscopic method was 1.050 g and the highest body weight was 3.370 g. All patients were diagnosed with type III EA according to the Gross classification. In 8 (29.6%) children coexisting congenital disorders were diagnosed (Table 1). Patient with partial tracheal atresia subsequently underwent second surgery to repair this defect.

Echocardiography was performed before the surgery in all patients and congenital heart defects were detected as listed (Table 2).

After the admission of a child with EA, a radiographic imaging was performed. During the imaging, a nasogastric tube was placed in the upper part of the esophagus and 0.5 cm of aquatic contrast was administered. Aquatic contrast was removed immediately after capturing an image (Figure 1). In cases where Replogle's catheter was placed in

Table 1. Coexisting disorders.

Disorder	Number of cases
Partial tracheal atresia	1
Hypothyroidism	1
Anal atresia	1
Polydactyly	1
Crossed ectopy of the kidneys, shortening of a forearm, cervical ribs	1
Down syndrome	1
Edwards syndrome	2

Table 2. Identified heart defects.

Heart defect	Number of cases
PDA	5
PFO	11
VSD	3

Comments: PDA – patent ductus arteriosus; PFO – patent foramen ovale; VSD – ventricular septal defect.

Figure 1 . Radiographic image of EA with contrast in the upper part of the esophagus.

the upper part of the esophagus to remove the saliva, the contrast was not administered because the catheter's end would be visible in the radiographic image.

Surgical management of the EAs was performed between 4–72 h after admission to the Pediatric Surgery Ward. The duration of the surgery depended mostly on preparation for the surgery that included performing essential laboratory tests and imaging diagnostics and rebalancing electrolyte levels.

The technique described by Prof. Dariusz Patkowski was used during the surgery with minor modifications due to tool differences and experience that increased with time.[2]

At the beginning, minimally invasive surgeries were performed using 5-mm tools and 5-mm optics. Today, 3-mm tools and oblique 30-degree optics placed through the right pleura are used. Previously, patients were placed on their left side. With time, our experience increased and patients were placed in the prone position. Each patient underwent enforced pneumothorax, which was obtained by insufflation of CO_2 with the pressure of 2–6 mm Hg.

First, a 5-mm trocar was placed using the open technique in intercostal space II or III, below the angle of the scapula. Next, a 3-mm trocar was placed under supervision of the camera in the paravertebral line in VI intercostal space. A 3-mm trocar was then placed in the posterior axillary line, in IV or V intercostal space. The identification of the tracheoesophageal fistula and upper and lower esophageal ends was the first step in every surgery. The dissection of the pleura began underneath the azygos vein. The aim was to preserve the azygos vein in order to separate the esophageal anastomosis and trachea in further steps of the surgery. After dissection of tracheoesophageal fistula, two 5-mm titan clips were placed beside the tracheal wall. The upper end of the esophagus was identified by movements of 8 Ch nasogastric tube, which was introduced through the nose. The upper end of the esophagus was dissected, immobilized and cut transversally using scissors. The nasogastric tube was further led through the opened upper end of the esophagus and the opened lower end of the esophagus to the stomach. For esophageal anastomosis, 5–0 absorbent surgical thread was used. In the esophageal anastomosis, both absorbable multifilaments and monofilaments were used, depending on the preferences of the operator. Both ends of the esophagus were fused using approximately 4 to 6 sutures. The suturing of the esophagus was always performed on a previously placed nasogastric tube. Sutures were knotted inside the chest cavity. The patient's chin was bowed to the chest to reduce tension of the esophagus. This position of the patient was maintained during the stay in the ICU. After performing the anastomosis, an 8 Ch nasogastric tube with no suction was left for 24–48 h in the chest cavity. The nasogastric tube was introduced through the second trocar (3 mm placed in the paravertebral line, VI intercostal space). Wounds after trocars were provided with a single absorbent suture. After the surgery, patients were admitted to the ICU.

4. RESULTS

The mean duration of the surgery was 171 minutes (70–290 minutes) (Figure 2). Because the surgeries were performed by multiple surgeons with different experience, learning curve was not possible to determine, but with growing experience of individual operators' duration of their performance declined.

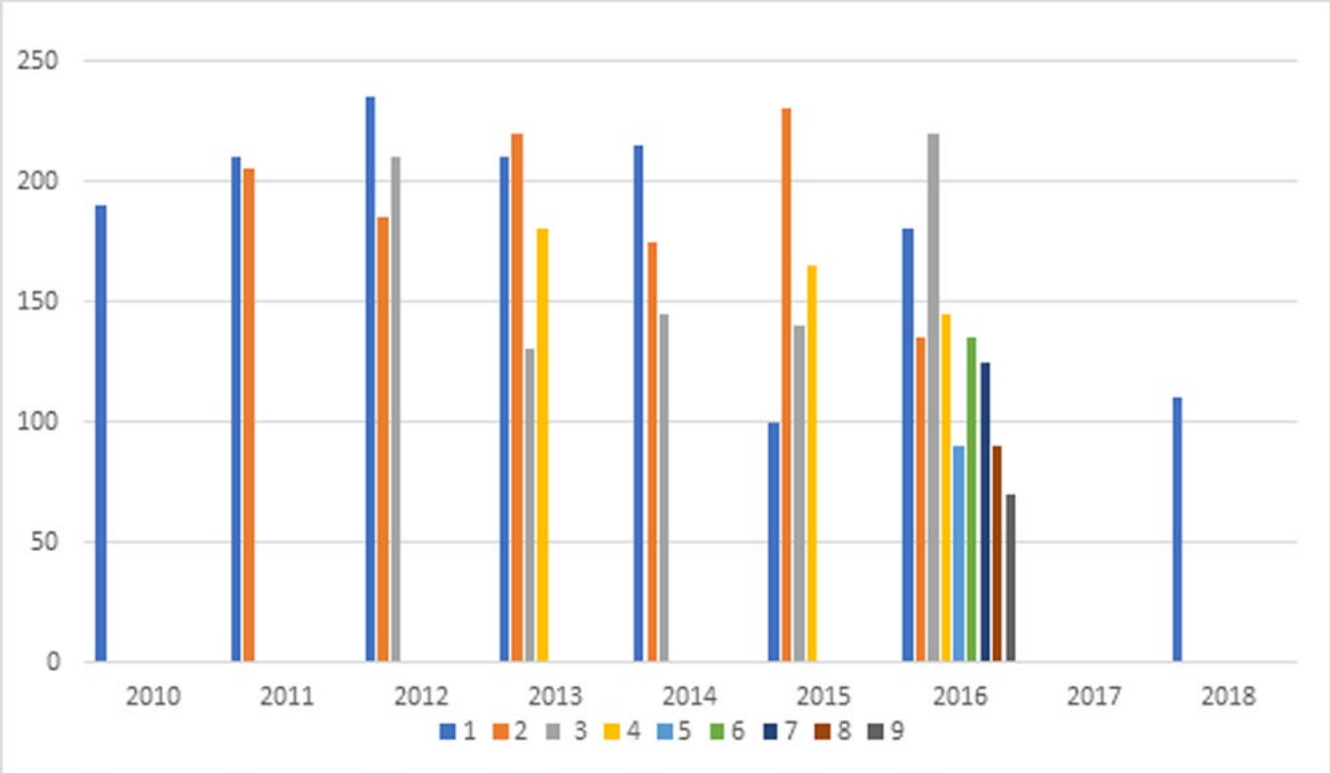

Figure 2. Procedure duration in minutes.

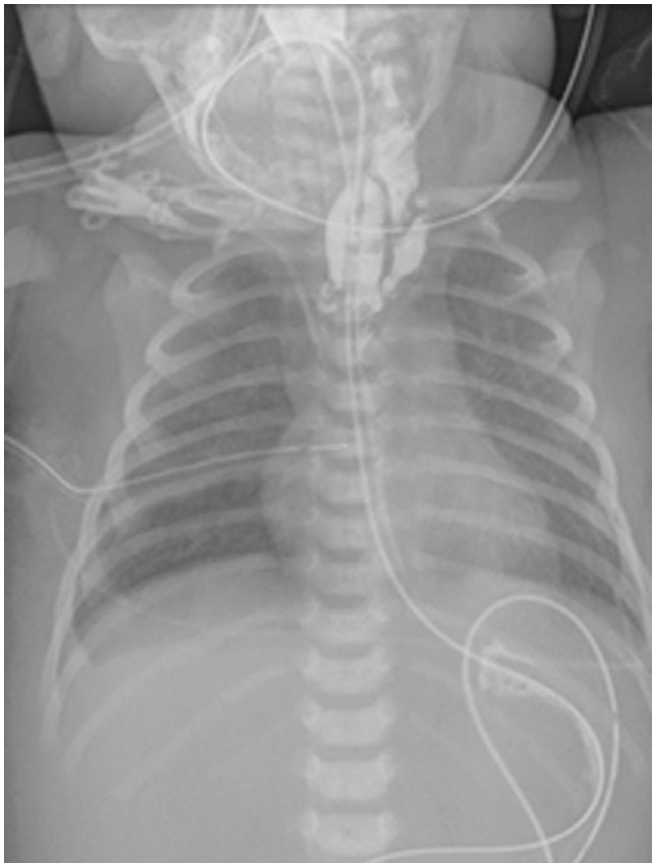

Figure 3. Stain around the anastomosis.

Figure 4. Disappearance of the stain after 3-weeks.

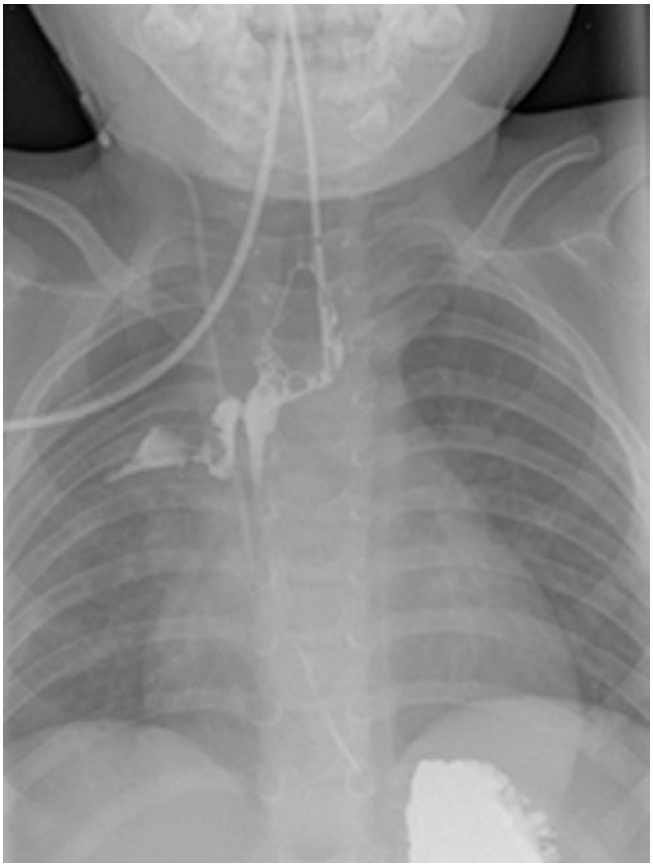

Figure 5. Tracheoesophageal fistula.

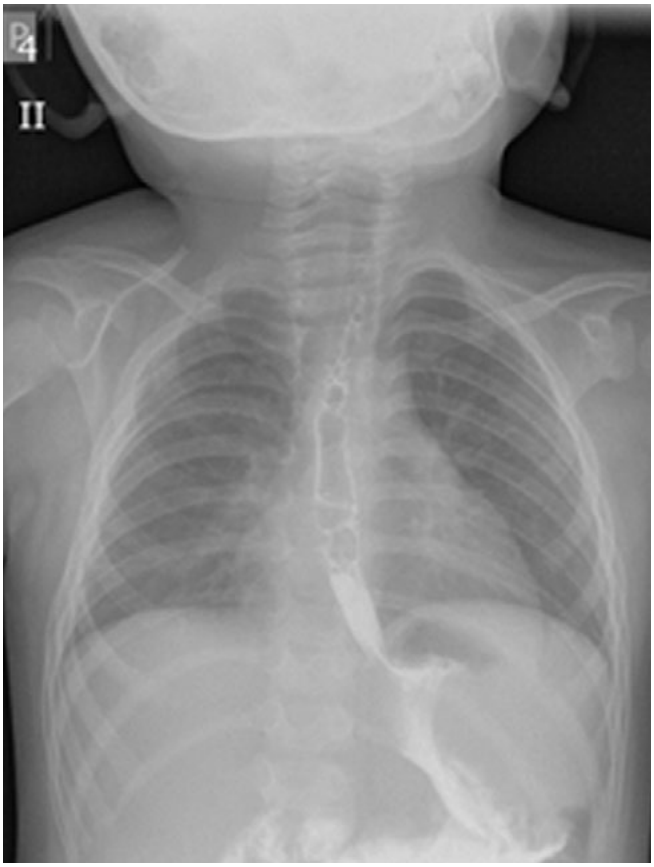

Figure 6. Patient after closure of the fistula.

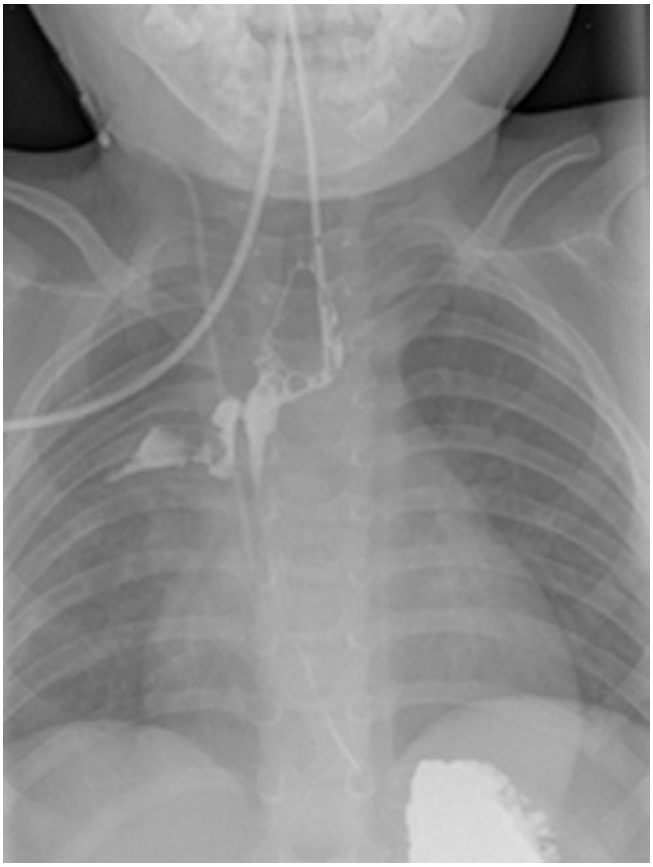

Figure 7. Radiographic image after dilatation of the esophagus.

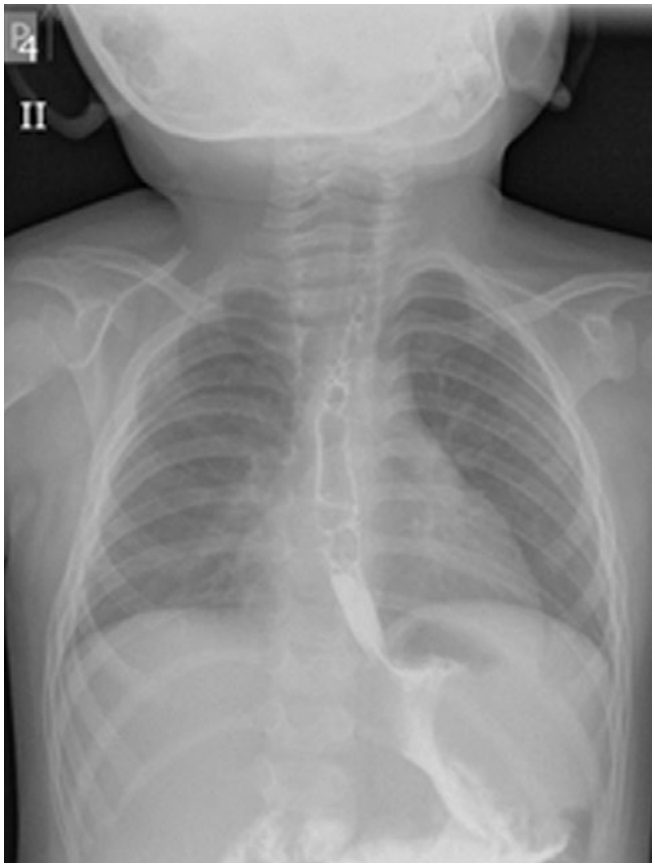

Figure 8. Narrowing of the esophagus in a radiographic image with barium contrast.

Conversion to thoracotomy was needed in 6 (21.4%) patients. The reason for the conversion was mainly due to lack of procedure progress caused by insufficient visualization of the surgical field.

Mean time that patient spent in the ICU ward was 14.5 days (6–30 days). Mean time of need for nCPAP was 13.8 days (5–31 days).

During hospitalization in the ICU, chest radiographic images were performed 2 days after the surgery. Afterwards, the nasogastric tube was removed from the chest cavity on the 2nd or 3rd day of the postoperative period.

Keeping the nasogastric tube in the chest cavity for a longer period was necessary in 2 patients due to pneumothorax. In 2 (7.1%) cases , leakage of lymph occurred. In 1 (3.6%) patients with lymph leakage sustained a nasogastric tube in the chest cavity and after 12 days, leakage of the lymph stopped spontaneously. The other patient died due to severe electrolyte imbalance, which was impossible to control. In 3 (10.7%) cases a radiographic image showed leakage of the anastomosis. In a radiographic image obtained by using barium as a contrast, a stain around the anastomosis was found. A three-week maintenance of a nasogastric tube inside the esophagus led to the complete healing of the anastomosis and stain disappearance (Figures 3 and 4).

One patient required re-operation due to air leakage which was caused by recurrent tracheoesophageal fistula. At the age of 2 years, the patient underwent thoracotomy and the fistula was sutured up (Figures 5 and 6).

Feeding through a nasogastric tube placed inside the esophagus usually started 4–6 days after the surgery. Patients with diagnosed stain around the anastomosis had delayed feeding introduction until stain disappearance. Nasogastric tube was usually removed from the esophagus 6 days after the surgery. In 2 (7.1%) cases, nasogastric tube was accidentally removed earlier and it was immediately placed back into the esophagus and stomach. Patients with this incident did not have any additional complications regarding to this event. In the study group, 22 (78.6%) patients underwent scheduled esophageal dilatation before discharge within 2 weeks after the surgery. After discharge, patients were regularly controlled in the Pediatric Surgery Outpatient Clinic and in Gastroenterological Outpatient Clinic. Further dilatation of the esophagus depended on clinical features and a radiographic image with barium contrast (Figures 7 and 8).

Four patients died (14.8%) (Table 3).

Table 3. Death causes in patients treated due to EA.

Death cause	Number of cases
Uncontrolled leakage of the lymph and electrolyte imbalance	1
MRCNS sepsis	1
Coexisting disorders (Edwards syndrome)	2

Comments: MRCNS – Methycillin-resistant coagulase-negative staphylococci

After discharge, the patients were treated in Gastroenterological Outpatient Clinic. They were included in a special treatment program, which involved scheduled gastroscopies and esophageal dilatation. None of the patients were surgically treated due to gastroesophageal reflux; 22 (78.6%) patients required esophageal dilatation due to its narrowing.

5. DISCUSSION

Thoracoscopic repair of EA is one of the most complicated surgeries performed by a pediatric surgeon in everyday practice. Many clinics worldwide perform this type of surgery due to its obvious advantages.[4] Muscles of the chest are not cut open during this procedure, which results in lower risk of spinal curvature, chest deformations, ribs adhesions, long-term pain and weakening of a pectoral girdle. These types of complications were described after EA surgeries using classic thoracotomy.[5–7] HD quality cameras with zoom up to 10× were used. This technique enables recognition of chest cavity anatomical structures and very precise tissue dissection resulting in minor traumatization and minimal blood loss surgeries. Newborn chilling is avoided because the surgery is performed without chest cavity opening. The most difficult and the longest part of the surgery is suturing the esophagus. This requires perfect visualization and operator's efficient technique in laparoscopic suturing. The duration of the surgery has characteristic learning curve. Thus, duration decreases over time due to increasing experience. This phenomenon was also confirmed by surgeons experienced in laparoscopic techniques.[8]

The six conversions described above were mainly caused by the lack of procedure progress due to insufficient visualization of the surgical field. This was particularly a cause of conversion during the first few surgeries when lung insufflation was blocking a view of the anastomosis. This problem could be alleviated by decreasing the respiratory volume of the patient, however, this action caused an unacceptable drop in saturation. It turned out that the appropriate position of the patient was the key to avoid blocking the view by sufficiently insufflated lungs. First few patients were placed on their left side. Over time, with growing experience, patients were placed in the prone position with a slight support of the chest on the level of the left arm. This maneuver enabled the left lung to fall under its own weight and it did not collide with the anastomosis view any more. CO_2 insufflation with 2–4 mmHg pressure was applied. In some cases, in patients positioned on the left side, pneumothorax occurred with CO_2 insufflation with the pressure of 6 mm Hg, which brought unsatisfactory results for sufficient visualization. Heaters of insufflation gases were always used to avoid hypothermia.

During the first phase of the surgery, trocars were securely sutured to the skin of the chest. The chest walls of newborns are very thin and this can easily lead to misplacing the trocars. Time loss connected with trocar re-insertion and resuming the procedure is disproportionally large when compared with time spent on proper trocar fixing in the first place. In order to improve suturing conditions, the surgeons changed the position of the left working trocar to the paravertebral line in VI intercostal space and the right working trocar in a position which enables work at 90 degrees. The position of the optic trocar, right below the axillary angle enables (especially using 30-degree optics) the view over the surgical field.[9] In the esophageal anastomosis, both absorbable multifilaments and monofilaments were used, depending on the preference of the operator. Based on the experience of other centers, monofilament sutures became more popular due to the advantage in facilitating esophagus suturing.[8]

The patient's chin was bowed to the chest to reduce tension of the esophagus. This position of the patient was maintained during breathing with the respirator in the ICU. On the 2nd or 3rd day after the surgery, a radiographic image was performed in ICU. If there was no sign of stain around the anastomosis or a pneumothorax, a nasogastric tube was removed from the chest cavity. In cases with pneumothorax, a nasogastric tube was left for a few more days until it disappeared. In 3 (10.7%) cases in which stain around the anastomosis occurred, a nasogastric tube was also left for a few more days until the stain disappeared. In these patients nasogastric tube was kept inside the esophagus for 3 weeks after the surgery. In all 3 cases, proper healing of the anastomosis was noted. Waiting for spontaneous disappearance of the stain and the maintenance of an esophageal nasogastric tube for a longer period than usual was also a good practice described by other clinics.[2,3]

Although esophageal dilatation after surgical management of esophageal atresia in our opinion is not always necessary, in our patients it was commonly needed due to esophageal narrowing. Furthermore, Gastroenterological Outpatient Clinic that our patients were followed at after discharge from the hospital, uses protocol that includes esophageal dilatation and regular gastroscopies as a part of standard patient management plan. Literature shows that dilatation of the esophagus after esophageal atresia surgical management is needed in approximately half of the patients.[10,11] Thus, in our opinion patients should be closely monitored in outpatient clinic after hospital discharge and application of an esophageal dilatation should be individually considered.

The described results are like results described in the literature on the subject.[4,8]

6. CONCLUSIONS

Performing a surgery due to EA using thoracoscopic technique requires experience and extraordinary skills in laparoscopic technique from the operator. An experienced anesthesiology and infant ICU teams are essential. Based on the results of thoracoscopically-treated EA and indisputable advantages of this approach for the patient (considering contraindications), the thoracoscopic technique of EA surgical treatment is a highly recommended method.

Conflict of interest

None declared.

Funding

None declared.

References

1 Lobe TE, Rothenberg SS, Waldschmidt J, Stroedter L. Thoracoscopic repair of esophageal atresia in an infant: a surgical first. *Pediatr Endosurg Innov Tech*. 1999;3(3):141–148. https://doi.org/10.1089/pei.1999.3.141.

2 Patkowski D, Rysiakiewicz K, Jaworski W, et al. Thoracoscopic repair of tracheoesophageal fistula and esophageal atresia. *J Laparoendosc Adv Surg Tech A*. 2009;19(Suppl 1):S19–22. https://doi.org/10.1089/lap.2008.0139.supp.

3 Bax NMA, van der Zee DC. Feasibility of thoracoscopic repair of esophageal atresia with distal fistula. *J Pediatr Surg*. 2002;37(2):192–196. https://doi.org/10.1053/jpsu.2002.30253.

4 Yang YF, Dong R, Zheng C, et al. Outcomes of thoracoscopy versus thoracotomy for esophageal atresia with tracheoesophageal fistula repair: A PRISMA-compliant systematic review and meta-analysis. *Medicine (Baltimore)*. 2016;95(30):e4428. https://doi.org/10.1097/md.0000000000004428.

5 Freeman NV, Walkden J. Previously unreported shoulder deformity following right lateral thoracotomy for esophageal atresia. *J Pediatr Surg*. 1969;4(6):627–636. https://doi.org/10.1016/0022-3468(69)90490-4.

6 Jaureguizar E, Vaiquez JJ, Murcia J, Diez Pardo JA. Morbid musculoskeletal sequelae of thoracotomy for tracheo-esophageal fistula. *J Pediatr Surg*. 1995;20(5):511–514. https://doi.org/10.1016/s0022-3468(85)80477-2.

7 Durning RP, Scoles PV, Fox OD. Scoliosis after thoracotomy in tracheo-esophageal fistula patients. *J Bone Joint Surg Am*. 1980;62(7):1156–1158.

8 Rothenberg S. Thoracoscopic repair of esophageal atresia and tracheo-esophageal fistula in neonates: the current state of the art. *Pediatr Surg Int*. 2014;30(10):979–985. https://doi.org/10.1007/s00383-014-3586-7.

9 Rothenberg SS. Thoracoscopic repair of esophageal atresia and tracheo-esophageal fistula in neonates: evolution of a technique. *J Laparoendosc Adv Surg Tech A*. 2012;22(2):195–199. https://doi.org/10.1089/lap.2011.0063.

10 Dingemann C, Dietrich J, Zeidler J, et al. Early complications after esophageal atresia repair: Analysis of a German health insurance database covering a population of 8 million. *Dis Esophagus*. 2016;29(7):780–786. https://doi.org/10.1111/dote.12369.

11 Salo M, Stenstrom P, Arnbjornsson E. Anastomotic Strictures after Esophageal Atresia Repair: Timing of Dilatation during the First Two Postoperative Years. *Surg J (NY)*. 2018;4(2):e62–e65. https://dx.doi.org/10.1055%2Fs-0038-1646950.