



Research paper

Demodex spp. (Acari: Demodicidae) infection in healthy young adults in Poland – occurrence and risk factors

Ewa Dzika ^{ORCID}, Katarzyna Kubiak ^{ORCID}, Joanna Korycińska ^{ORCID},
Lepczyńska Małgorzata ^{ORCID}, Hanna Szymańska ^{ORCID}

Department of Medical Biology, School of Public Health, Collegium Medicum, University of Warmia and Mazury in Olsztyn, Poland

ARTICLE INFO

Article history

Received 4 April 2020

Accepted 29 April 2020

Available online 11 July 2020

Keywords

Poland

Students

Mites

Demodex

Healthy young

Doi

<https://doi.org/10.29089/2020.20.00109>

User license

This work is licensed under a
Creative Commons Attribution –
NonCommercial – NoDerivatives
4.0 International License.



ABSTRACT

Introduction: *Demodex* mites are associated with various symptoms pertaining to facial and eyelid skin in humans. Demodicosis is often reported in elderly people, above 50 years of age. In young adults, the *Demodex* spp. infection is less common and is asymptomatic or the symptoms are mild.

Aim: The aim was to evaluate the occurrence of *Demodex* spp. in healthy young adults in Poland and analyze the associations between the presence of mites, participants gender and skin type, with regards to hygienic practices and symptoms.

Material and methods: The content of facial sebaceous glands and eyelash follicles was examined in a group of 94 people, aged 18–32 years. Metric data and information about face and eyelid skin symptom occurrence, skin type and hygienic practices were collected by diagnostic survey.

Results and discussion: *Demodex* spp. was identified in 21.3% of subjects. In 45% and 30% of carriers *Demodex folliculorum* and *Demodex brevis* occurred, respectively. A mixed infestation in 25% of subjects was detected. *Demodex* infestation was slightly higher in people with oily and mixed skin (23.5%), compared to those with dry and normal skin (18.6%). No significant influence of shared hygienic accessories on the level of *Demodex* spp. infection were observed. The skin symptoms of the face and eyelids were reported at 75% for subjects positive for *Demodex*.

Conclusions: *Demodex* mites are often prevalent in healthy young adults in Poland in both the sebaceous glands of the face and hair follicles. While diagnosing face and eyelid skin diseases in young people, *Demodex* spp. infection should be considered.

1. INTRODUCTION

The hair follicle mites of the *Demodecidae* family are cosmopolitan, specialized and obligatory parasites of both humans and animals.¹ Among 140 species described so far, only *Demodex folliculorum* and *Demodex brevis* are specific to humans.^{2,3} *Demodex folliculorum* usually inhabits facial hair follicles, but may also colonize the sebaceous glands (Zeiss' glands) and hair follicles of eyelashes. *Demodex brevis* lives deep in the sebaceous glands of facial skin (around the nose, eyes, forehead, chin, and nasolabial fold) or the Meibomian gland of the eyelids.^{4,5} Both species may also occur in the hair follicles or skin sebaceous glands of other body parts. The prevalence ratio of *D. brevis* and *D. folliculorum* in males and females is 1:4 and 1:10, respectively.⁶ Any particular human may be a carrier of a *Demodex* colony consisting from 1000 to 2000 specimens.

The life cycle of *Demodex* lasts from 14 to 18 days and requires only one host.^{7,8} These parasites avoid the sunlight in all of the developmental stages. Their copulation occurs during the night, near the entry to the hair follicle and the subsequently fertilized female migrates to the sebaceous gland where she lays less than 20 eggs.^{7,9} After copulation, the male dies.¹⁰ The larvae hatch after 60 h, molt twice and transform into a deutonymph – the infective stage for humans.⁹ The deutonymphs evolve to the adult form after the next molting.^{10,11} All of the developmental stages of *Demodex* spp. feed on epithelial cells, the content of sebaceous glands (sebum), lymph and plasma.⁷

Humans may contract the parasite by direct contact with a carrier of *Demodex* spp. as well as indirectly by using common towels, sheets, cosmetics or toiletries.^{8,10} It has also been documented that infants may become infected by contact with colonized mothers skin.^{12,13} Therefore, *Demodex* mites have a cosmopolitan distribution and are found in about 10% of biopsy specimens of healthy human skin, where they are present in about 12% of all follicles. Various studies have shown normal rates of colonization to be 20% to 80%.^{12,13} The prevalence of both *Demodex* species increases with the host age and in adults reaches even 100% with a density of more than 5 mites per 1 cm² of normal skin.^{14,15}

Usually the *Demodex* infection in humans occurs asymptotically. Primarily *Demodex* mites have been treated as a commensal fauna on mammalian skin.¹⁴ The host's immune status and changes in the skin microenvironment can facilitate a rapid propagation and consequently change it into a pathogen.^{5,16} An increasing number of *Demodex* mites in human skin is associated with the pathogenesis of some dermatoses including demodicosis, rosacea or blepharitis as well as with immunosuppression caused by the natural aging processes and the occurrence of other diseases.^{5,16,17} The skin symptoms caused by *Demodex* spp. show up because mites are moving from hair follicles and sebaceous glands to surrounding tissues. The *Demodex* antigens trigger the host immune reaction, which is the direct cause of rosacea symptoms. Similar triggers have been reported from parasite fe-

ces. The reason for skin symptoms might also be caused by blockage of follicles and sebaceous glands by *Demodex* mites that leads to epithelial hyperplasia and hyperkeratosis.¹⁶ *Demodex* mites might also trigger the mechanisms leading to skin inflammation which are not caused directly by tissue damage. *Demodex* mites contain lipase, supposed to be able to aggravate skin conditions by transforming sebum into certain components, which are clearly cytotoxic, and irritants.^{18,19,20} It has been established that *Demodex* mites can also be a vector of the pathogens *Bacillus oleroni* and *Staphylococcus epidermidis*, which may play a prominent role in the pathogenesis of demodicosis.^{9,21}

2. AIM

The epidemiological study of *Demodex* spp. prevalence in humans shown having a high dependence on the patient's age. Most often demodicosis in elderly people over 50 years old is reported.^{22,23} It has been suggested that the percent of infestation in young people, about 25 years old, is lower.²⁴ The aim of this study is to determine the prevalence of *Demodex* mites in the young adult population living in the North-East of Poland and also the association of the species occurrence with the facial area, gender, skin type, hygienic habits and symptoms.

3. MATERIAL AND METHODS

3.1. Study population

A total of 94 young healthy volunteers (students of the University of Warmia and Mazury in Olsztyn) were examined. The study group consist of 73% females ($n = 69$) and 27% males ($n = 25$), aged 18–32 (average 20.2) years old. The content of facial sebaceous glands (forehead, cheeks, nose, chin) and lashes from both eyes were collected from 81 participants. From the 13 volunteers, only lashes with a root of hair were collected to identify the *Demodex* occurrence. Metric data (age and gender), information about skin symptoms of the face and eyelids, skin type and hygienic habits from examined students were collected to determine the risk factors of *Demodex* spp. infection and associated possible symptoms (skin symptoms as itching and irritation of the skin, eczema, acne and ocular symptoms: inflammation of the eyelids, itching, madarosis). Data were collected by self-design diagnostic survey questionnaire.

3.2. Detection of *Demodex* mites

The *Demodex* mites were detected in the content of the forehead, cheeks, nose and chin sebaceous glands (black head) as well as in the roots of the upper lashes of both eyes. Samples were obtained from the volunteers by squeezing method and by epilation, early in the morning. The sterile gauze swabs, epilating forceps and microscopic slides were used for aseptic material collection. The material was set separately into a Hoyer liquid drop²⁵ and observed under light microscope

Table 1. The infection by *Demodex* mites and species distribution in according to gender.

Gender	<i>Demodex</i> positive/tested <i>n</i> (%)	<i>P</i> value*	OR(95%CI)	<i>Demodex</i> species / <i>Demodex</i> positive (%)			<i>P</i> value*
				<i>D. brevis</i>	<i>D. folliculorum</i>	<i>D. brevis</i> / <i>D. folliculorum</i>	
Female	17/69 (24.6)	0.186	0.42 (0.11–1.57)	4/17 (23.5)	8/17(47.1)	5/17 (29.4)	0.277
Male	3/25 (12.0)			2/3 (66.7)	1/3 (33.3)	0/3 (0.0)	
Total	20/94 (21.3)			6/20 (30.0)	9/20 (45.0)	5/20 (25.0)	

Comments: * χ^2 test; OR – odds ratio; CI – confidence interval.

by 100 \times and 400 \times magnification. Each sample containing a mite, from any developmental stage (adult form, nymph, egg), was considered as a positive result. The *Demodex* species were identified according to its morphological features (specimen size, opisthosoma end, size and shape of the eggs).^{26,27} Participants were informed about not washing their face and lack of makeup before taking samples.

3.3. Statistical analysis

The data were analyzed using Pearson χ^2 test and a *P* value less than 0.05 was considered as statistically significant. The association between predictor variables was determined by odds ratio (OR) and their 95% confidence interval (CI). The tests were conducted using the software package SPSS v. 22.0 for Windows (SPSS, Chicago, IL).

4. RESULTS

The total infestation rate of *Demodex* mites was 21.3% (20 of the 94 participants). In total, 24.6% (*n* = 17) of examined females and 12.0% (*n* = 3) of males were infected. No significant differences in the prevalence of mites infection was found between males and females (Table 1).

Based on the morphological features, *D. folliculorum* was in 45.0% (*n* = 9) of infected volunteers (Figure 1). *Demodex brevis* occurred in 30.0% (*n* = 6) of carriers. Mixed infestation was found in 25.0% (*n* = 5) of persons. *Demodex folliculorum* was detected in all of the positive samples of the lashes and 54.2% (*n* = 13) of positive samples from the sebaceous glands of facial skin. *Demodex brevis* was identified in 45.8% (*n* = 11) of positive samples from facial skin. No statistically significant differences between the occurrence of both species were observed according to gender (Table 1). From 17 colonized females, in 47.1% (*n* = 8) *D. folliculorum* was noted and in 23.5% (*n* = 5) *D. brevis* was identified. Infection with both species occurred in 29.4% (*n* = 5) of females. Among the males, *D. brevis* occurred in 66.7% of them (*n* = 2) and *D. folliculorum* in only 33.3% (*n* = 1). There were no mixed infections in the male group for facial skin or eyelash follicles.

Demodex spp. infection was slightly higher in young people with oily and mixed skin (23.5%) compared to those with dry and neutral skin (18.6%) (OR = 1.35; 95%CI: 0.49–3.66; *P* = 0.561). The statistical analysis did not show a significant influence of skin type on the occurrence of *Demodex* spp. in this group (Table 2). Similarly, using and sharing of the same hygienic accessories and cosmetics did not signifi-

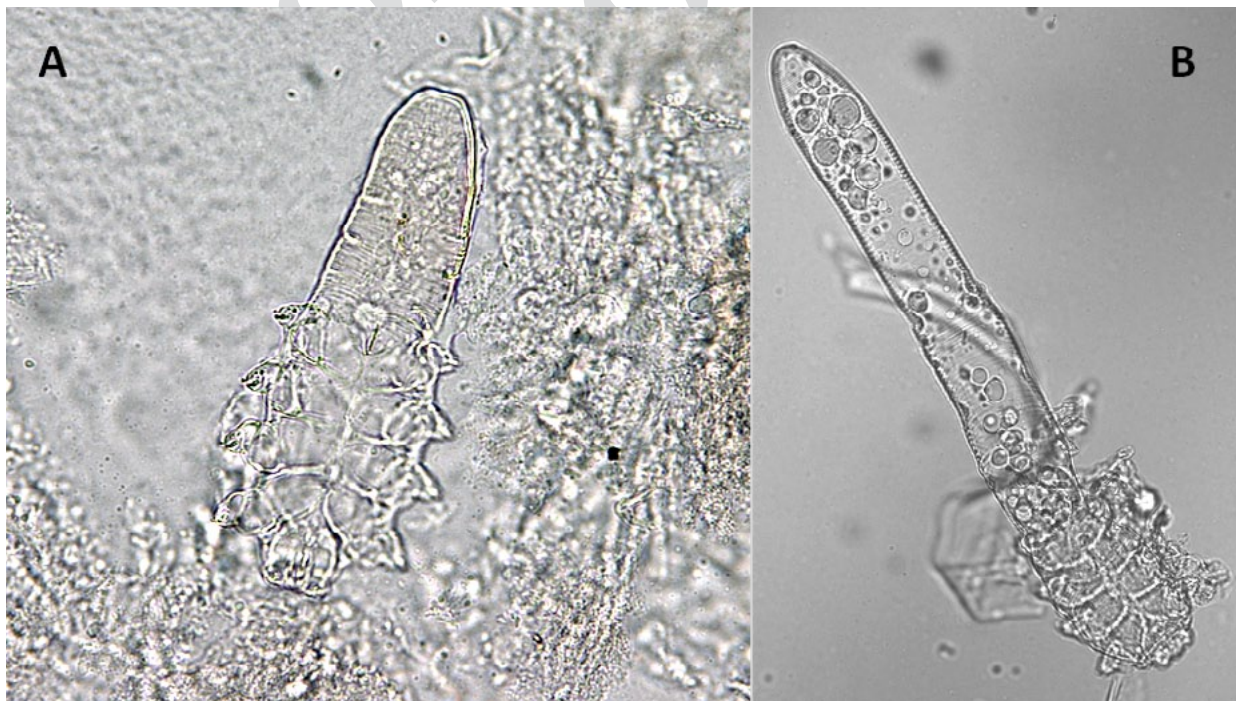


Figure 1. Adult *Demodex brevis* (A) and *Demodex folliculorum* (B) in facial sebaceous secretions (100 \times magnification) (foto Litwin D).

Table 2. Hygienic practices, skin type and symptoms in tested group of young healthy adults.

	<i>Demodex</i> spp.		<i>P</i> value*	OR(95%CI)
	positive <i>n</i> (%)	negative <i>n</i> (%)		
Sanitary ware sharing				
No	13(20.3)	51(79.7)	0.739	1.17(0.41–3.32)
Yes	7(23.3)	23(76.7)		
Skin type				
Dry/neutral	8(18.6)	35(81.4)	0.561	1.35(0.49–3.66)
Oily/mixed	12(23.5)	39(76.5)		
Symptoms				
No	5(14.7)	29(85.3)	0.072	1.93(0.63–5.89)
Yes	15(27.8)	39(72.2)		

Comments: * χ^2 test; OR – odds ratio; CI – confidence interval.

cantly influence the *Demodex* spp. infection level in this age group (OR = 1.17; 95%CI: 0.41–3.32; *P* = 0.739).

The questionnaire data show that skin symptoms on the face and eyelids were reported by 75.0% (15/20) of *Demodex* positive volunteers and by 60.8% (45/74) who were not colonized. The occurrence of *Demodex* spp. was twice as high in the symptomatic group as compared to volunteers without any skin disorders on the face and eyelids (OR = 1.93; 95%CI: 0.63–5.89; *P* = 0.072); however, these differences were not statistically significant. The most common symptoms were itchiness and skin irritation (*n* = 11) as well as madarosis (*n* = 7).

5. DISCUSSION

Demodex mites occur in people worldwide regardless of race or ethnic group^{1,28} and are quite often the reason for skin and eye problems. The infection of *Demodex* mites in healthy people depends on many factors, usually age and gender as well as skin type or hygienic habits.

The main determinant of *Demodex* spp. prevalence is the patient's age. The occurrence frequency of mites in the age group below 30 years old is lower than 40% in contrast to people in the 71–95 age group, where 95% or more are carriers of *Demodex* spp.^{23,29–33} Our results show that the *Demodex* spp. infection percentage of healthy people younger than 30 years of age in North–East Poland is 21.1%. It is higher than in the examined group of students from North–West Poland (14%) and from Hungary (17.1%).^{34,35} The type of diagnostic method, the number of examined samples as well as the examination time may influence the difference of the *Demodex* spp. prevalence in various young populations.^{15,36} Although there are differences in the *Demodex* spp. prevalence of young people (8–25 years old), our study has shown a lack of significant differences between males and females.^{15,30–33} Moreover, the prevalence of both species is similar in this age group to various populations. Usually, the infestations are dominated by *D. folliculorum*, which in our examined group was detected in 45% of positive samples. The prevalence of

this species was lower when compared to China (51%) and Turkey (77%).^{30,33} The higher percentage of infections by *D. folliculorum* may be associated with the place of residence – hair follicles of facial skin and eyelashes. Therefore, it is easier to detect than *D. brevis* which lives deeper in the sebaceous glands. It has been confirmed by our study that *D. folliculorum* was detected in all of the positive samples of eyelashes. In the sebaceous glands of facial skin samples, the prevalence of both *D. folliculorum* and *D. brevis* was equal.

The *Demodex* spp. prevalence in humans also depends on the skin type. In our study, the percentage of *Demodex* spp. infection of the examined group with oily and mixed skin was only a little higher compared to the group with dry and normal skin. It was shown that the detection rate of *Demodex* spp. in the group with oily and mixed skin was almost 15% higher than that with dry and normal skin.^{15,31} A higher infestation rate in the population having mixed or oily skin most probably is associated with a higher sebum secretion by sebaceous glands which provides more nutrition and stimulates the reproduction of *Demodex* spp.

Theoretically, poor hygienic habits such as using common towels and toilet accessories should have an influence on the *Demodex* distribution. The above mentioned activities are conducive to the transmission of *Demodex* spp. nymphs and eggs. However, the data does not confirm this theory. The infection level of young people from North–East Poland who use common toilet accessories was similar to those who did not share towels and cosmetics with others. Similarly, that risk factor did not have any influence on the infection level of students from China, Hungary and Turkey.^{15,32,35}

A *Demodex* spp. infection in most cases is asymptomatic. However, in some conditions such as immune system disorders, chronic diseases, genetic predispositions, or an elderly age, there may be various symptoms, which according to Chen and Plewig³⁶ are classified as primary and secondary demodicosis. Primary demodicosis usually occurs in people above 40 years old. Its etiological factor is a large colonization by *D. folliculorum* on the eyes, ears and oral skin.³⁷ The skin symptoms are usually localized around a hair follicle. In most cases, primary demodicosis is asymptomatic or with

mild itching, which persists after antiparasitic treatment (ivermectin, metronidazole).^{4,20} Secondary demodicosis shows skin symptoms associated with infection by numerous mites in patients of other recognized diseases with general or local immunosuppression (leukemia, HIV) as well as in patients treated with immunosuppression drugs.^{36,38} The reason for secondary demodicosis is mainly *D. brevis* infection.³⁷ The symptoms are more dispersed and are characterized by intense inflammation, which is the cause of rosacea or seborrheic dermatitis. The characteristic symptoms are redness, erythema and telangiectasia. The secondary demodicosis may coexist with a skin cancer (melanoma, eyelid cancer, mycosis fungoides) or systemic diseases. The treatment of secondary demodicosis in view of a patient's concurrent immunosuppression is more difficult.³⁶ This study shows that the *Demodex* spp. infection in young people may be associated with characteristics of both clinical forms of demodicosis. Zhao et al.¹⁵ demonstrated that 71.2% of Chinese people between the ages of 13–22 with diagnosed facial dermatosis (rosacea, acne vulgaris, blepharitis) were colonized by *Demodex* spp., while the same age-group without the above-mentioned diseases had a parasite infection level that was lower by about 18%. Similar differences in people aged 21–35 with diagnosed blepharitis were found.³⁹ In this age group, the mite infestation was about 20% higher compared to the control group.³⁹ In our study population, diagnosed skin diseases were not reported. However, 75% of *Demodex* spp. positive volunteers complained of facial skin and eyelid symptoms such as skin itching and irritation, and madarosis. These kinds of symptoms may suggest the beginning of primary demodicosis, which can have a higher intensity later at an elderly age and require treatment.

6. CONCLUSIONS

Demodex mites are often prevalent in healthy young Polish individuals of both sexes in the sebaceous glands of facial skin and the hair follicles of lashes. The infection of humans is caused by two specific *Demodex* species with a higher prevalence of *D. folliculorum*. The coexistence of both species, *D. folliculorum* and *D. brevis*, is also possible. The infestation of mites occurs a little more often in persons with mixed and oily skin than with person who have normal and dry skin. The prevalence of *Demodex* spp. is not associated with the sharing of common toilet accessories and cosmetics. The colonized persons report facial skin and eyelid symptoms slightly more often.

Conflict of interest

None declared.

Funding

None declared.

Ethics

This study was approved by the Bioethics Committee for Scientific Research at the University of Warmia and Mazury in Olsztyn, Poland (Agreement No. 19/2013). Written informed consent was obtained from each patient.

Acknowledgements

We thank D. Litwin M.Sc. for biological material collection and identification and E. Kędzierska M.Sc. for database preparation.

References

- Czepita D, Kuźna-Grygiel W, Czepita M, Grobelny A. Demodex folliculorum i Demodex brevis as a cause of chronic marginal blepharitis. *Ann Acad Med Stetin*. 2007;53(1):63–67 [in Polish].
- Zhao YE, Xu JR, Hu L, Wu LP, Wang ZH. Complete sequence analysis of 18S rDNA based on genomic DNA extraction from individual Demodex mites (Acari: Demodicidae). *Exp Parasitol*. 2012;131(1):45–51. <https://doi.org/10.1016/j.exppara.2012.02.025>.
- Akbulatova LKH. The pathogenic role of the mite Demodex and the clinical forms of demodicosis in man. *Vestn Dermatol Venerol*. 1966;40(12):57–61 [in Russian].
- Sędzikowska A. Demodicosis – pathophysiology, treatment and therapeutic efficacy of metronidazole ointment and mercury oxide ointment. *Ophtha Therapy*. 2014;2(2):108–111 [in Polish].
- Jarmuda S, O'Railly N, Zaba R, Jakubowicz O, Szkaradkiewicz A, Kavanagh K. Potential role of Demodex mites and bacteria in the induction of rosacea. *J Med Microbiol*. 2012;61(11):1504–1510. <https://doi.org/10.1099/jmm.0.048090-0>.
- Liu J, Sheha H, Tseng SC. Pathogenic role of Demodex mites in blepharitis. *Curr Opin Allergy Clin Immunol*. 2010;10(5):505–510. <https://doi.org/10.1097/ACI.0b013e32833df9f4>.
- Izdebska JN. Human skin mites and pets. In: *Allergology in practice. Allergy to mites*. Majkowska-Wojciechowska B, ed. Łódź: Mediton. 2005:95–105.
- Kuźna-Grygiel W, Kosik-Bogacka D, Czepita D, Sambor I. Symptomatic and asymptomatic infections of Demodex Spp. in eye lashes of patients of different age groups. *Wiad Parazytol*. 2004;50(1):55–61 [in Polish].
- Raszeja-Kotelba B, Jenerowicz D, Izdebska JN, Bowszyc-Dmochowska M, Tomczak M, Dembińska M. Some aspects of the skin infestation by Demodex folliculorum. *Wiad Parazytol*. 2004;50(1):41–54 [in Polish].
- Buczek A. *Parasitic diseases, epidemiology, diagnostics, symptoms*. Lublin: Koliber. 2005:318–323 [in Polish].
- Zhao YE, Guo NA, Li C, Lu Z-H. The dynamic observation of the morphologic structure and activity of human Demode in different stages. *Chin J Vec Biol Contr*. 2007;18(2):120–123.
- Lacey N, Russell-Hallinan A, Zouboulis CC, Powell FC. Demodex mites modulate sebocyte immune reaction: possible role in the pathogenesis of rosacea. *Br J Dermatol*. 2018;179(2):420–430. <https://doi.org/10.1111/bjd.16540>.
- Elston DM. Demodex mites: facts and controversies. *Clin Dermatol*. 2010;28(5):502–504. <https://doi.org/10.1016/j.clindermatol.2010.03.006>.

- ¹⁴ Forton FMN. Papulopustular Rosacea, Skin Immunity and Demodex: Pityriasis Folliculorum as a Missing Link. *J Eur Acad Dermatol Venereol*. 2012;26(1):19–28. <https://doi.org/10.1111/j.1468-3083.2011.04310.x>.
- ¹⁵ Zhao YE, Guo N, Xun M, Xu JR, Wang M, Wang DL. Sociodemographic characteristics and risk factor analysis of Demodex infestation (Acari: Demodicidae). *J Zhejiang Univ Sci B*. 2011;12:998–1007. <https://doi.org/10.1631/jzus.B1100079>.
- ¹⁶ Lacey N, Kavanagh K, Tseng SCG. Under the lash: Demodex mites in human diseases. *Biochem (Lond)*. 2009;31(4):2–6. <https://doi.org/10.1042/BIO03104020>.
- ¹⁷ Marcinowska Z, Kosik-Bogacka M, Łanocha-Arendarczyk N, Czepita D, Łanocha A. Demodex folliculorum and Demodex brevis. *Pom J Life Sci*. 2015;61(1):108–114 [in Polish].
- ¹⁸ Gutierrez Y. Diagnostic Pathology of Parasitic Infections with Clinical Correlations (2nd edn). Yezid Gutierrez, MD, MPH&TM, PhD. Oxford University Press, New York, 2000. *J Pathol*. 2001;193(2):277. [https://doi.org/10.1002/1096-9896\(200102\)193:2<277::AID-PATH806>3.0.CO;2-P](https://doi.org/10.1002/1096-9896(200102)193:2<277::AID-PATH806>3.0.CO;2-P).
- ¹⁹ Persi A, Reborá A. Metronidazole and Demodex folliculorum. *Acta Derm Venereol*. 1981;61(2):182–183.
- ²⁰ Litwin D, Chen W-Ch, Dzika E, Korycińska J. Human permanent ectoparasites; Recent advances on biology and clinical significance of Demodex mites: Narrative review article. *Iran J Parasitol*. 2017;12(1):12–21.
- ²¹ Shelley WB, Shelley ED, Burmeister V. Unilateral demodectic rosacea. *J Am Acad Dermatol*. 1989;20(5 Pt 2):915–917. [https://doi.org/10.1016/s0190-9622\(89\)70107-9](https://doi.org/10.1016/s0190-9622(89)70107-9).
- ²² Wesołowska M, Baran W, Szepietowski J, Hirschberg L, Jankowski S. Demodicidosis in humans as a current problem in dermatology. *Wiad Parazytol*. 2005;51(3):253–256 [in Polish].
- ²³ Czepita D, Kuźna-Grygiel W, Kosik-Bogacka D. Demodex as an etiological factor in chronic blepharitis. *Klin Oczna*. 2005;107(10–12):722–724 [in Polish].
- ²⁴ Garbacewicz A, Udziela M, Grytner-Ziecina B, Szaflik JP, Szaflik J. Demodex infections in general Polish population, in patients suffering from blepharitis, and among people who work with microscopes. *Klin Oczna*. 2010;112(10–12):307–310 [in Polish].
- ²⁵ Cielecka D, Salamatin R, Garbacewicz A. Usage of the Hoyer's medium for diagnostics and morphological studies of some parasites. *Wiad Parazytol*. 2009;55(3):265–270 [in Polish].
- ²⁶ Ruffi T, Mumcuoglu Y. The hair follicle mites Demodex folliculorum and Demodex brevis: Biology and medical importance. A review. *Dermatologica*. 1981;162(1):1–11. <https://doi.org/10.1159/000250228>.
- ²⁷ Desch C, Nutting WB. Demodex folliculorum (Simon) and D. Brevis Akbulatova of man: Redescription and reevaluation. *J Parasitol*. 1972;58(1):169–177. <https://doi.org/10.2307/3278267>.
- ²⁸ Rusiecka-Ziołkowska J, Nokieli M, Fleisher M. Demodex – an old pathogen or a new one? *Adv Clin Exp Med*. 2014;23(2):295–298. <https://doi.org/10.17219/acem/37081>.
- ²⁹ Elston CA, Elston DM. Demodex Mites. *Clin Dermatol*. 2014;32(6):739–743. <https://doi.org/10.1016/j.clindermatol.2014.02.012>.
- ³⁰ Ru-Juan Z, Xue-Rong Y, Ying Z, et al. Investigation on Demodex infection status and influencing factors in medical students in Wuhu City. *Zhongguo Xue Xi Chong Bing Fang Zhi Za Zhi*. 2017;29(3):358–362. <https://doi.org/10.16250/j.32.1374.2016243> [in Chinese].
- ³¹ Cao YS, You QX, Wang L, et al. Facial Demodex infection among college students in Tangshan. *Zhongguo Ji Sheng Chong Xue Yu Ji Sheng Chong Bing Za Zhi*. 2009;27(3):271–273 [in Chinese].
- ³² Karaman Ü, Kolören Z, Enginyurt Ö, Özer A. The epidemiology of Demodex mites at the college students living in dormitories in the City of Ordu. *Turkiye Parazitolo Derg*. 2014;38(3):166–171. <https://doi.org/10.5152/tpd.2014.3517> [in Turkish].
- ³³ Zeytun E, Tilki E, Doğan S, Yani Mumcuoğlu K. The effect of skin moisture, pH, and temperature on the density of Demodex folliculorum and Demodex brevis (Acari: Demodicidae) in students and staff of the Erzincan University, Turkey. *Int J Dermatol*. 2017;56(7):762–766. <https://doi.org/10.1111/ijd.13600>.
- ³⁴ Dołęgowska K. Prevalence of Demodex spp. in students and employees of the Pomeranian Medical University in Szczecin. *Pomeranian J Life Sci*. 2019;65(3):31–35. <https://doi.org/10.21164/pomjlifesci.603>.
- ³⁵ Horváth A, Neubrandt DM, Ghidán Á, Nagy K. Risk factors and prevalence of Demodex mites in young adults. *Acta Microbiol Immunol Hung*. 2011;58(2):145–155. <https://doi.org/10.1556/AMicr.58.2011.2.7>.
- ³⁶ Chen W, Plewig G. Human demodicosis: revisit and a proposed classification. *Br J Dermatol*. 2014;170(6):1219–1225. <https://doi.org/10.1111/bjd.12850>.
- ³⁷ Akilov OE, Butov YS, Mumcuoglu KY. A clinico-pathological approach to the classification of human demodocosis. *J Dtsch Dermatol Ges*. 2005;3(8):607–614. <https://doi.org/10.1111/j.1610-0387.2005.05725.x>.
- ³⁸ Litwin D, Wygonowska E, Dzika E, Placek W. [The prevalence of Demodex folliculorum on the skin lesions compared to non-lesion skin in patients with dermatoses – preliminary study]. *Dermatol Prakt*. 2014;6:13–17 [in Polish].
- ³⁹ Biernat M, Rusiecka-Ziołkowska J, Piątkowska E, Helemejko I, Biernat P, Gościński G. Occurrence of Demodex species in patients with blepharitis and in healthy individuals: A 10-year observational study. *Jpn J Ophthalmol*. 2018;62(6):628–633. <https://doi.org/10.1007/s10384-018-0624-3>.