



## Review paper

### Types of improper child carrying

**Wojciech Kiebzak<sup>1,2</sup>**, **Arkadiusz Żurawski<sup>1,2</sup>**, **Dariusz Czaprowski<sup>3</sup>**, **Ireneusz M. Kowalski<sup>4</sup>**

<sup>1</sup> Institute of Health Sciences, Collegium Medicum, The Jan Kochanowski University in Kielce, Poland

<sup>2</sup> Świętokrzyskie Center of Paediatrics, Provincial Integrated Hospital in Kielce, Poland

<sup>3</sup> Department of Physiotherapy, Faculty of Health Sciences, Poznan University of Medical Sciences, Poland

<sup>4</sup> Department of Rehabilitation, School of Medicine, Collegium Medicum, University of Warmia and Mazury in Olsztyn, Poland

#### ARTICLE INFO

##### Article history

Received 13 August 2020

Accepted 25 September 2020

Available online 4 November 2020

##### Keywords

Spine

Prevention

Psychomotor development

Posturogenesis

Hip joints

Carrying children

##### Doi

<https://doi.org/10.29089/2020.20.00138>

##### User license

This work is licensed under a

Creative Commons Attribution –

NonCommercial – NoDerivatives

4.0 International License.



#### ABSTRACT

**Introduction:** In the first months of the child's life, the spine is not ready to adopt and keep the upright body posture and to control the position of the body axis during locomotion. However, the authors' clinical observations show that it is common to carry children in the first year of their lives in a way that could be a potential source of overload of the locomotive organ.

**Aim:** The purpose of the work is to present the most common, incorrect ways of carrying infants and presenting their clinical consequences.

**Material and methods:** Using the keywords 'carrying children,' 'stacking babies,' 'moving babies,' 'carrying an infant,' 'stacking infants,' 'moving infants,' the following databases were searched: Science Direct, Web of Science, Pub Med, Scopus and Clinical Key. Works published after 1990 were searched.

**Results and discussion:** The most frequently observed mistakes when carrying a baby include: excessive bending of the lower limbs resulting in lumbar spine kyphosis, carrying the child facing the parent with the head rotated to one side, carrying the child facing the carer with the head in hyperextension and shoulders in protraction, carrying an infant face down on the forearm and the so-called 'carrying on the hip.'

**Conclusions:** Incorrect carrying an infant can affect the incorrect stimulation of a child's psychomotor development.

## 1. INTRODUCTION

The basic supporting and stabilizing element for the entire human locomotion organ is the spine. In the first months of its life it is not prepared to adopt the function of maintaining a vertical position and controlling the position of the body axis during locomotion.<sup>1</sup> The fetal and neonatal periods are the only ones in human life when the flexion position of the body is treated as natural and correct.<sup>2</sup> A gradual change in the curves of the spine is an adaptive mechanism to the changing conditions and motor needs that accompany a child during his growth and is associated with a desire and the need to explore the environment.<sup>3</sup> It seems that this process can be influenced by the manner in which the child is carried and laid.<sup>4</sup>

Lack of publications describing the optimal ways of carrying a child corresponds with the authors' own clinical observations pointing to widespread carrying children in a way that makes the head positioned improperly, the spine joints overloaded, and creates defective conditions for forming the hip joints. The repeatability and often extreme range of ways of unsuitable carrying observed at the outpatient clinic has inspired and keeps inspiring the authors to search for appropriate clinical solutions.

## 2. AIM

The purpose of the work is to present the most common, incorrect ways of carrying infants and presenting their clinical consequences.

## 3. MATERIAL AND METHODS

The authors have reviewed the literature to verify whether the standards of carrying a child in the first year of life have been presented. Using the keywords: carrying children, stacking babies, moving babies, carrying an infant, stacking infants, moving infants, the following databases were searched: Science Direct, Web of Science, Pub Med, Scopus and Clinical Key. Works published after 1990 were searched. No publication has been found describing how to carry children, and what complications arise from improper carrying them.

The authors' observations involved about 7500 children from the Provincial Specialist Children's Hospital and the Świętokrzyskie Pediatrics Center in Kielce and the Rehabilitation Clinic in Olsztyn. The observations concern over 30 years of clinical work of the authors. The beginning of the observation of the child's development usually begins around the third month of his life and continues until he reaches the stage of independent walking.

## 4. RESULTS

The authors' many years of clinical practice indicate that parents carry their children in a variety of ways that can affect the curvature of the spine and the child's motor development (Figure 1).

The most frequently observed mistakes when carrying a baby include:

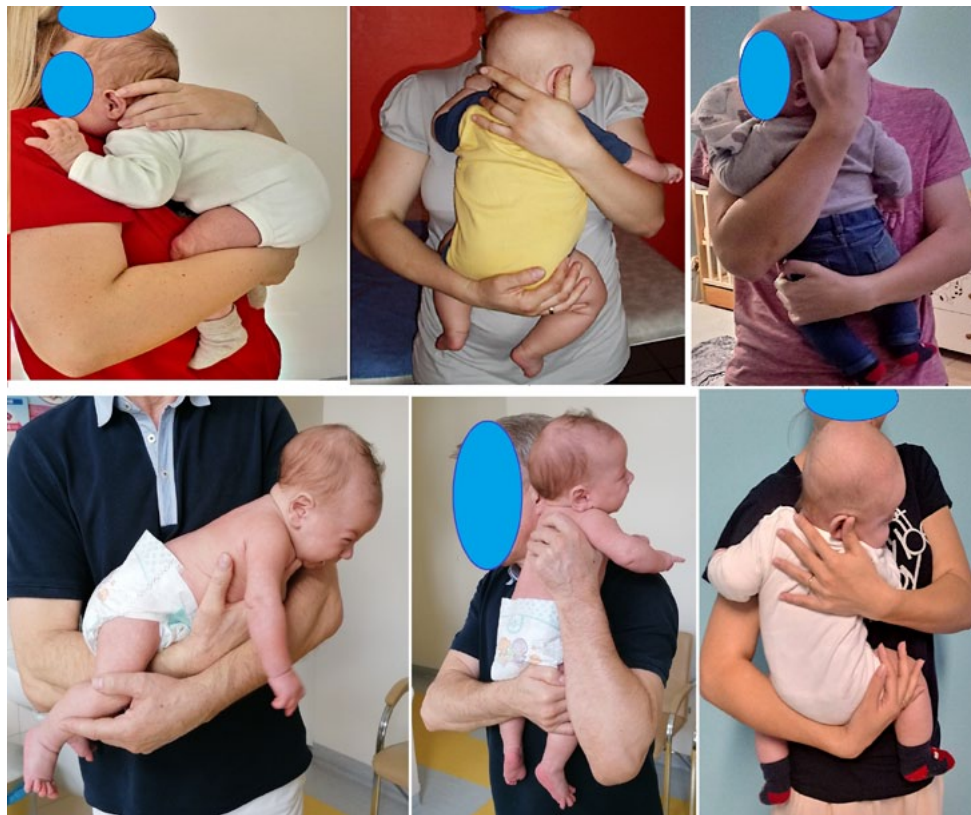

Figure 1. Examples of an infant's position when being carried (own sources).

- (1) Excessive bending the lower limbs, which causes shallowing and even kyphotization of the lumbar spine, which may delay the development of independent sitting and locomotion.<sup>5</sup> Too excessive thoracic kyphosis and too shallow lumbar lordosis correlate with the occurrence of discopathy, which is a serious clinical problem in older children.<sup>6</sup> This position is also accompanied by hyperextension of the head and shoulders retraction (Figure 2).
- (2) Carrying the child facing the carer with the child's head in the hyperextension position and arms in retraction. Typical for this position is the extension and adduction position of the femur in the hip joint (Figure 3). The above manner of carrying a child, with frequent and long-lasting repetition or with poor development of the acetabulum of the hip joint, may lead to disorders in the development of this structure.<sup>8</sup>

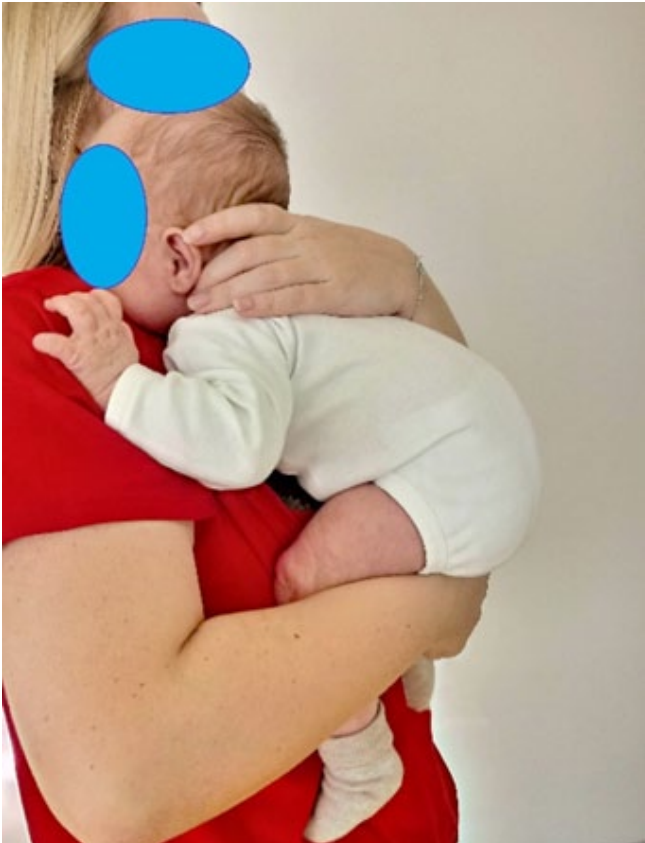

Figure 2. Kyphotization of the lumbar spine in an improperly carried infant (own sources).



Figure 3. Carrying the child facing the world with hip extension (own sources).

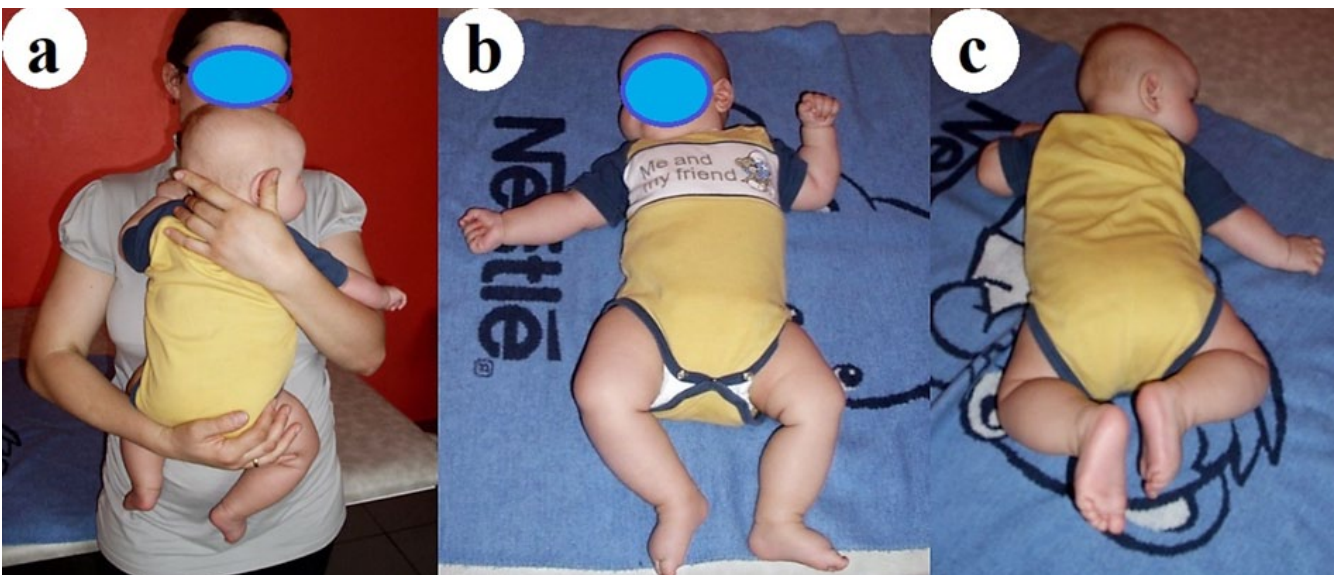
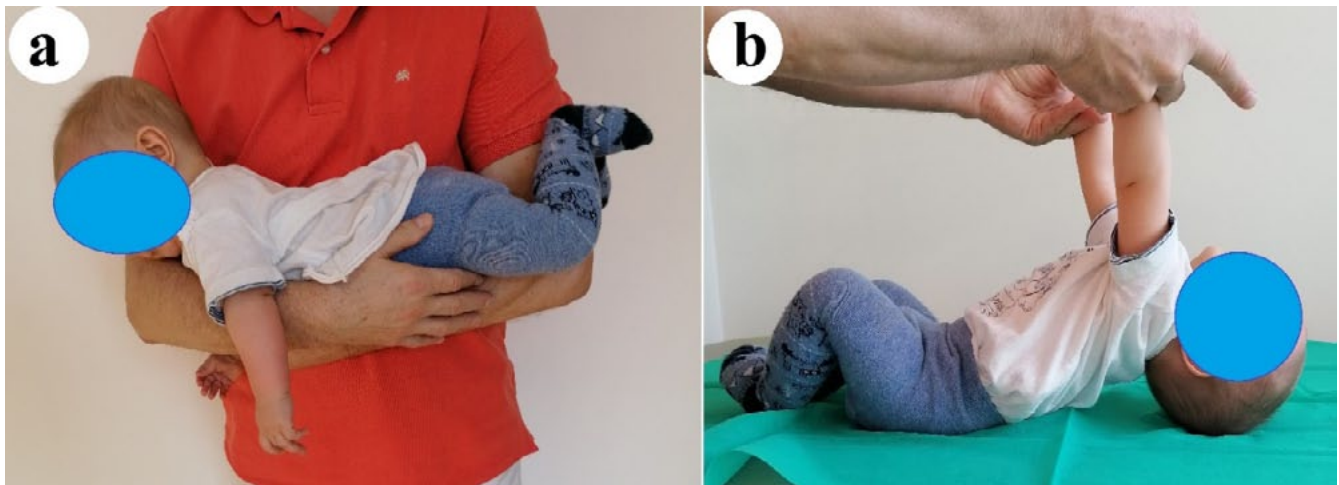


Figure 4. Influence of the child's position when worn on the induction of an asymmetrical tonic neck reflex (own sources).



**Figure 5. Carrying on the forearm face down (own sources).**

(3) Carrying the infant facing the world with the head turned to one side (Figure 4a).

Carrying a child with the head turned to one side may cause or intensify already existing dysfunctions such as strengthening pathological tonic reflexes, e.g. asymmetrical tonic neck reflex (ATNR) (Figure 4b). ATNR is caused by the head turned to the side, resulting in tonic extension of the limbs on the side of the face and tonic flexion of the limbs on the occiput side. This reflex determines the position of the head, spine and limbs<sup>7</sup> leading to disorders of support functions of the upper extremities (Figure 4c).

(4) Carrying on the forearm face down (Figure 5a).

Although this method (Figure 5) secures the correct position of the femoral head in the acetabulum and support of the spine, it may, however, lead to bent backwards position of the head and disorder of motor functions.<sup>9</sup> Long-lasting remaining in the shown position leads to stretching and weakening the flexors (m. longus colli and m. longus capitis) and simultaneous strengthening the extensors of the head (mm. spleni, m. longissimus capitis).<sup>9</sup> These disorders also translate into incorrect responses in postural reactions (Figure 5b).

(5) The so called ‘carrying on the hip’ (Figure 6).

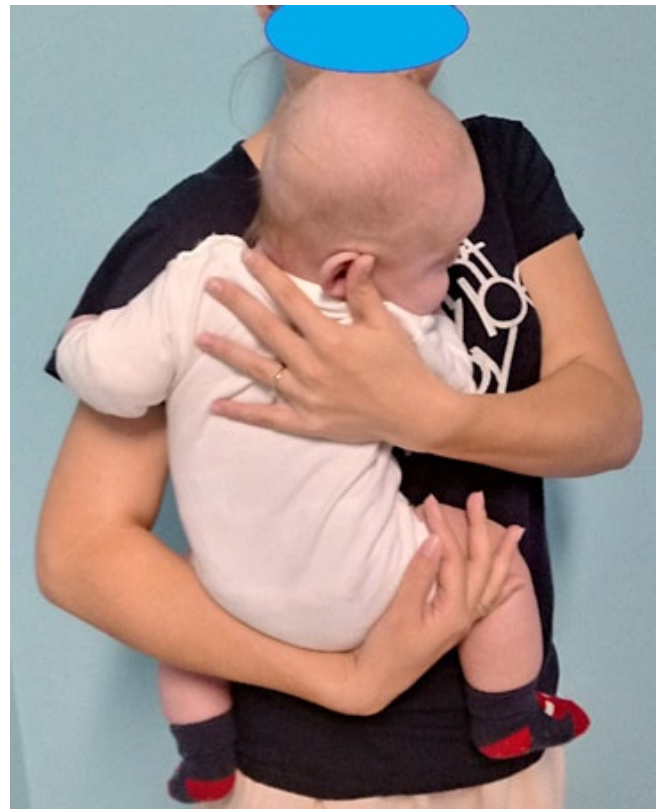Although this method safeguards the correct position of the femoral head in the acetabulum, it can, however, lead to an asymmetrical position of the head and spine, as well as a disorder of support and gripping functions of the upper limbs.<sup>10</sup>

The above examples are primarily characterized by too early axial load on the spine. According to Vojta, the infant is prepared for an axial load on the spine at around 8-9 months of age, when he independently adopts a sitting position. This ability is determined by the skill to keep the support on one straight upper limb, with simultaneous rotation of the torso and extension of the other upper limb above the head.<sup>5</sup>

## 5. DISCUSSION

The authors’ own clinical observations indicate that there are no general recommendations for optimum infant carrying. This is also confirmed by the literature review conducted for the purposes of the work, which has shown no publications in this regard. Therefore, the purpose of the work is to present the most common, improper ways of carrying an infant, based on biomechanical analysis and the authors’ own experience.

At the early stage of a child’s development the spine is not prepared to adopt axial loads. Therefore, first of all, car-



**Figure 6. The so-called ‘carrying on the hip’ (own sources).**

rying an infant in an upright position should be avoided. Such a position may disturb the formation of curvature of the spine, and, consequently, lead to incorrect development of the entire musculoskeletal system.<sup>2,9,11–15</sup> In the first year of a baby's life, the torso muscles do not provide adequate stabilization of the spine.<sup>2</sup> Position of the spine in flexion positions results in tenfold increase of compressive and shear forces affecting the lower spine.<sup>11</sup> Therefore, there is a risk that adopting the flexed position of the lumbar spine by the infant while carrying may be conducive to vertebrae development disorders due to compressive forces in their front part, which may result in vertebral wedge.<sup>2</sup> Flexion positions of the spine cause an increase in intra-spinal pressure, which results in disturbed blood flow and perfusion leading to disorders of oxidative metabolism in mitochondria of spinal neurons,<sup>12</sup> thus affecting axonal transport and nerve conduction disorders.<sup>16</sup> Hypovascular vertebral circulation disorders can cause vertebral growth disorders, which correlates with structural scoliosis.<sup>13</sup> Disorders in the curvature of the spine in the sagittal plane trigger the occurrence of deformations in the other planes of the spine, contributing to the development of posture defects in younger and younger children.<sup>17</sup> Being in flexion positions also disturbs the respiratory cycle, resulting in a decrease in respiratory capacity and pulmonary ventilation capacity in 1 minute,<sup>18</sup> a decrease in the forced expiratory volume in 1 second and forced vital capacity.<sup>14</sup> Holding the child in flexed positions may also result in the following disorders: swallowing,<sup>19</sup> intestinal peristalsis or intestinal gas passage.<sup>20</sup>

The occurrence of inappropriate reactions in infants often forces parents to carry them incorrectly. Parents wanting to adapt to the child's incorrect motor models carry them in a way that strengthens existing dysfunctions. In such situations, it is difficult to assess the order of events, whether the primary factor was the incorrect model or incorrect way of carrying. Incorrect carrying methods do not always have to result in these complications, especially if their application is short-lived.

Presented in the work ways of carrying are based on the authors' many years of clinical experience and have been supported by the analysis of the literature on the relationship between irregularities in positions adopted by the child in the first year of life and disorders of motor and cognitive development. Nevertheless, the authors are aware of the insufficiency of the work resulting from the lack of experimental verification of the presented ways of carrying.

According to the authors, despite the restrictions presented above, the work is of crucial clinical relevance. In clinical assessment, this is due to widespread, improper carrying infants, the lack of parents' knowledge and awareness about the impact of the way an infant is carried on his development and the common lack of skills to properly carry an infant. Therefore, the authors believe that the presented description of the negative consequences of improper carrying a child is important in the prevention of developmental disorders in infants in the first year of life.

## 6. CONCLUSIONS

Incorrect carrying an infant can affect the incorrect stimulation of a child's psychomotor development. Improper carrying a child may result in the overload of the musculoskeletal system, hindering the development of the level of social contacts, which in turn may lead to motor development disorders.

### Conflict of interest

None declared.

### Funding

This research was partially supported by the program of the Minister of Science and Higher Education called "Regional Initiative of Excellence" in the years, project no 024/RID/2018/19, amount of financing 11 999 000.00 PLN.

### Acknowledgement

We would like to express our acknowledgment for the selection of literature for Małgorzata Domagalska Szopa i Andrzej Szopa.

### Ethics

The authors obtained the written consent of the children's guardians for the publication of photographs with their images

### References

- Miyagishima S, Asaka T, Kamatsuka K, et al. Characteristics of antigravity spontaneous movements in preterm infants up to 3 months of corrected age. *Infant Behav Dev.* 2016;44:227–239. <https://doi.org/10.1016/j.infbeh.2016.07.006>.
- Nakano H, Kihara H, Nakano J, Konishi Y. The influence of positioning on spontaneous movement of preterm infants. *J Phys Ther Sci.* 2010;22(3):337–344. <https://doi.org/10.1589/jpts.22.337>.
- Bouwstra H, Dijk-Stiger G, Grooten HMJ, et al. Prevalence of abnormal general movements in three-month-old infants. *Early Hum Dev.* 2009;85(6):399–403. <https://doi.org/10.1016/j.earlhumdev.2009.01.003>.
- Pizzigalli L, Cremasco MM, Cremona E. Human postural adaptation to early and atypical gravitational environment effects of sport training on stabilometric parameters. *Adv Anthropol.* 2013;3(4):229–236. <http://dx.doi.org/10.4236/aa.2013>.
- Vojta V. [*Cerebral Movement Disorders in Infancy – Early Diagnosis and Early Therapy*]. Stuttgart: Ferdinand Enke Verlag; 1984 [in German].
- Żurawski A, Kiebzak W, Zmysłna A, et al. Efficacy of the use of the McKenzie and Vojta methods to treat discopathy-associated syndromes in the pediatric population. *Int J Occup Med Environ Health.* 2019;32:33–41. <https://doi.org/10.13075/ijom.1896.01309>
- Sweeney JK, Gutierrez T. Musculoskeletal implications of preterm infant positioning in the NICU. *J Perinat Neonatal Nurs.* 2002;16:58–70. <https://doi.org/10.1097/00005237-200206000-00007>.

- <sup>8</sup> Kiebzak W, Żurawski A, Dwornik M. Vojta method in the treatment of developmental hip dysplasia – a case report. *Ther Clin Risk Manag.* 2016;12:1271–1276. <https://dx.doi.org/10.2147%2FTCRM.S106014>.
- <sup>9</sup> Vaivre-Douret L, Ennouri K, Jrad I, Garrec C, Papiernik E. Effect of positioning on the incidence of abnormalities of muscle tone in low-risk, preterm infants, *Eur J Paediatr Neurol.* 2004;8(1):21–34. <https://doi.org/10.1016/j.ejpn.2003.10.001>.
- <sup>10</sup> Gerber RJ, Wilks T, Erdie-Lalena C. Developmental milestones: Motor development. *Pediatr Rev.* 2010;31(7):267–277. <https://doi.org/10.1542/pir.31-7-267>.
- <sup>11</sup> Dreischarf M, Shirazi-Adl A, Arjmand N, Rolman A, Schmidt H. Estimation of loads on human lumbar spine: A review in vivo and computational model studies; *J Biomech.* 2016;49(6):833–845. <https://doi.org/10.1016/j.jbiomech.2015.12.038>.
- <sup>12</sup> Dey A, Barnsley N, Mohan R, McCormick M, McAuley JH, Moseley GL. Are children who play a sport or a musical instrument better at motor imagery than children who do not? *Br J Sports Med.* 2012;46(13):923–926. <http://dx.doi.org/10.1136/bjsports-2011-090525>.
- <sup>13</sup> Heripret G, Duriez I, Cauchoix J. [Experimental approach to the problem of idiopathic scoliosis. II. Effect of the unilateral excision of the lumbar paravertebral muscular mass in the lathyric rabbit during growth]. *Rev Chir Orthop Reparatrice Appar Mot.* 1961;47:621–628 [in French].
- <sup>14</sup> Lin F, Parthasarathy S, Taylor SJ, Pucci D, Hendrix RW, Makhous M. Effect of different sitting postures on lung capacity, expiratory flow, and lumbar lordosis. *Arch Phys Med Rehabil.* 2006;87(4):504–509. <https://doi.org/10.1016/j.apmr.2005.11.031>.
- <sup>15</sup> de Graaf-Peters VB, de Groot-Hornstra AH, Dirks T, Hadders-Algra M. Specific postural support promotes variation in motor behaviour of infants with minor neurological dysfunction. *Dev Med Child Neurol.* 2006;48(12):966–972. <https://doi.org/10.1017/S001216220600212X>.
- <sup>16</sup> Dunsirn S, Smyser C, Liao S, Inder T, Pineda R. Defining the nature and implications of head turn preference in the preterm infant. *Early Hum Dev.* 2016;96:53–60. <https://dx.doi.org/10.1016%2Fj.earlhumdev.2016.02.002>.
- <sup>17</sup> Zmysłna A, Kiebzak W, Żurawski A, et al. Effect of physiotherapy on spinal alignment in children with postural defects. *Int J Occup Med Environ Health.* 2019;32(1):25–32. <https://doi.org/10.13075/ijomeh.1896.01314>.
- <sup>18</sup> Landers M, Barker G, Wallentine S, McWhorter JW, Peel C. A comparison of tidal volume, breath frequency, and minute ventilation between two sitting postures in healthy adults. *Physiother Theory Pract.* 2003;19(2):109–119. <https://doi.org/10.1080/09593980307958>.
- <sup>19</sup> Simão SSS, Romero VU, Baraldil, K, et al. Clinical evaluation of the relationship of posture, breathing and swallowing in chronic-state post-stroke patients: case report. *Rev CEFAC.* 2013;15(5):1371–1378. <https://doi.org/10.1016/j.yjmed.2012.12.008>.
- <sup>20</sup> Dainese R, Serra J, Azpiroz F, Malagelada J. Influence of body posture on intestinal transit of gas. *Gut.* 2003;52(7):971–974. <http://dx.doi.org/10.1136/gut.52.7.971>.