


## Case report

# Dystrophic calcifications in case of a patient with systemic lupus erythematosus – case report and literature review

**Anna Kruszewska<sup>1</sup> , Agnieszka Owczarczyk-Saczonek<sup>1</sup>, Waldemar Placek<sup>1</sup>,  
Magdalena Krajewska-Włodarczyk<sup>2</sup>**

<sup>1</sup> Department of Dermatology, Sexually Transmitted Diseases and Clinical Immunology, School of Medicine, Collegium Medicum, University of Warmia and Mazury in Olsztyn, Poland

<sup>2</sup> Department of Rheumatology, School of Medicine, Collegium Medicum, University of Warmia and Mazury in Olsztyn, Poland

## ARTICLE INFO

### Article history

Received 14 October 2020

Accepted 21 January 2021

Available online 18 August 2021

### Keywords

Systemic lupus erythematosus

Dystrophic calcifications

Calcinosis cutis

### Doi

.....

### User license

This work is licensed under a Creative Commons Attribution – NonCommercial – NoDerivatives 4.0 International License.



## ABSTRACT

**Introduction:** Cutis calcification is the deposition of calcium in the skin and subcutaneous tissues and is classified into four subsets. Dystrophic calcifications are the most common type of skin calcification, occurring mainly in damaged tissues or in course of autoimmune disease. However, the coexistence of systemic lupus erythematosus (SLE) and soft tissue calcification is described rarely.

**Aim:** This article presents a case of dystrophic calcifications in the buttocks area in a 49-year-old woman with a 17-year history of SLE.

**Case study:** We report a case of 49-year-old women with SLE who developed nodular lesions in the buttock area. The radiological and histopathological examinations of the nodules showed presence of calcifications. The calcium metabolism parameters were in a normal range. The diagnosis of dystrophic calcinosis in the course of SLE was established.

**Results and discussion:** Dystrophic calcifications associated with autoimmune diseases are common, but occur rarely in SLE. It should be noted that patients with SLE can also develop calcifications of different types like metastatic or iatrogenic. Dystrophic calcifications in SLE usually present as small nodules on buttocks or limbs. The pathophysiology remains unclear, however, there are some theories that inflammation and vascular ischemia play a role in its process.

**Conclusions:** Calcifications in case of patients with SLE rarely require treatment. Several pharmacologic and surgical therapies have been tested with variable results. Additional research to establish an accepted treatment algorithm should be conducted.

## 1. INTRODUCTION

Soft tissue calcification is a rare disorder characterized by the deposition of calcium salts in the skin and subcutaneous tissue. Calcification has been associated with various disease with normal or elevated calcium levels.

In the classification of calcifications proposed by Boulman, five main groups of calcifications are distinguished: dystrophic, metastatic, nodular, idiopathic and calciphylaxis.<sup>1</sup> Gutteriez and Wetter modified mentioned classification including the following groups of calcifications: dystrophic, metastatic, iatrogenic, idiopathic.<sup>2</sup> Metastatic calcification is associated with elevated serum calcium levels, most often in the course of chronic kidney disease (CKD). This type is often localized periarticularly. Iatrogenic calcifications may occur in case of patients receiving intravenous calcium/phosphate supplementation. Idiopathic calcifications can be categorized into 3 subtypes: familial tumoral calcinosis, subepidermal calcified nodules, and scrotal calcinosis. They are characterized by normal calcium/phosphate levels, no previous damage to calcified tissues and an early formation of the first subcutaneous deposits. Calciphylaxis is defined as the calcification of small and medium-sized vessels mainly in patients with CKD undergoing dialysis.<sup>3</sup>

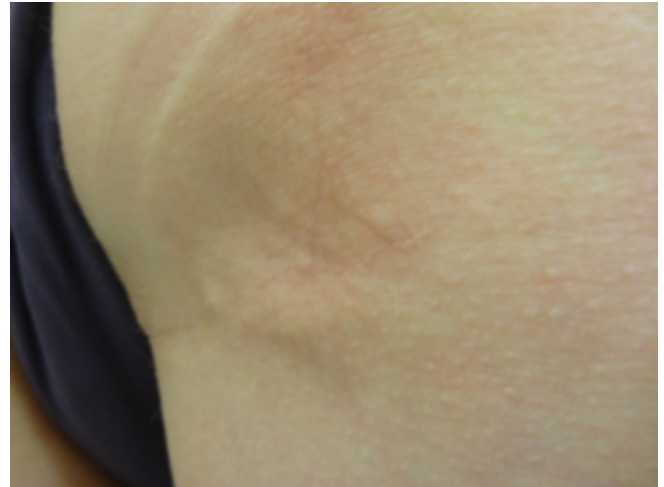Dystrophic calcifications are the most common type of skin calcification, occurring mainly in damaged tissues, e.g. following infection or trauma. Calcium and phosphorus levels are normal. Dystrophic calcifications have been well documented in association with connective tissue diseases such as systemic scleroderma (SS) and dermatomyositis (DM). It has also been found in many other diseases, such as morphea, Sjögren's syndrome, porphyria, some types of skin cancers, or scars. However, systemic lupus erythematosus (SLE) is one of the diseases in which this type of calcification is rarely observed.<sup>4</sup>

## 2. AIM

This study aims to present the case of a patient with SLE who was diagnosed with dystrophic calcifications in the buttocks area.

## 3. CASE REPORT

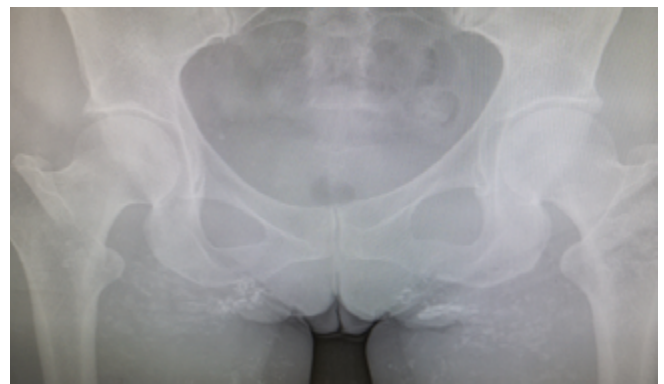A 49-year-old woman was admitted to the Department of Dermatology due to nodular lesions in the subcutaneous tissue in the buttocks area. The nodules were palpable for 2–3 years, were painless, but the patient reported noticeable discomfort while sitting on a hard surface (Figure 1). The patient was diagnosed with SLE 17-years ago. Leg ulcers, vasculitis and episodes of urticaria have occurred in the past. Previous laboratory tests revealed lower levels of complement components and high titers of antinuclear antibodies – ANA Hep2 1 : 2560 granular type with positive RNP Sm. She has been treated with hydroxychloroquine, periodically oral prednisone, intravenous methylprednisolone and recently with



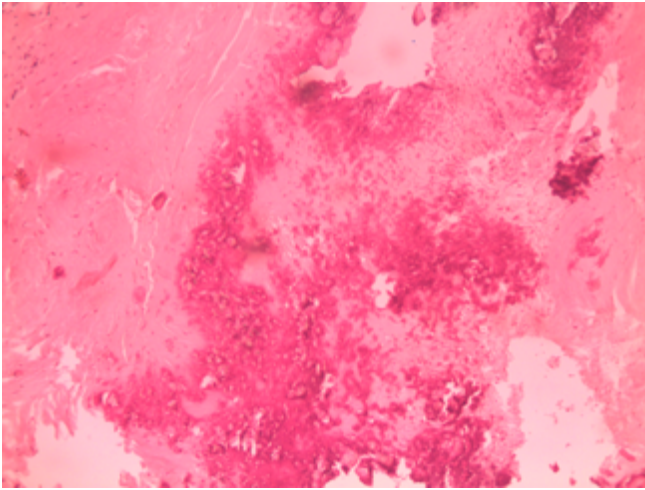
**Figure 1. Subcutaneous nodules presented in buttocks area, skin surface unaffected.**

oral methylprednisolone 8 mg daily. Additionally, she used oral supplementation of vitamins and electrolytes (calcium carbonate, cholecalciferol and potassium chloride). Other comorbidities included hypothyroidism treated with levothyroxine 62.5 µg daily and osteoporosis.

Laboratory tests revealed leukopenia  $3.34 \times 10^9/L$  with neutropenia  $1.41 \times 10^9/L$ , anemia (Hbg 11.9 g/dL) and a slightly increased amount of protein in 24 h urine collection (0.22 g / 24 h). The calcium metabolism was normal (parathyroid hormone 52.9 pg/mL, calcium 9.1 mg/dL, vitamin D3 level 57 ng/mL) and renal parameters were without significant deviations (serum creatinine 1 mg/dL, eGFR 58.9 mL/min/1.73 m<sup>2</sup>, serum urea concentration 32 mg/dL). A high level of ANA antinuclear antibodies was found in the titer 1 : 10000 and PmScl 100 was positive in the immunoblot. The radiological examination of the soft tissues around the buttocks showed numerous calcifications (Figure 2), and the histopathological examination of the subcutaneous nodule also showed the presence of calcifications (Figure 3). The diagnosis of dystrophic calcinosis most likely in the course of SLE was established. The treatment of the underlying disease was modified by adding hydroxychloroquine 200 mg daily, whereas calcium and vitamin D supplementation was discontinued. In the following months, the patient underwent litho-



**Figure 2. Numerous calcifications on radiological examination.**



**Figure 3. Calcifications visible in histological examination of skin nodules.**

tripsy with a fairly good clinical effect – the deposits around the buttocks were divided into smaller parts, which reduced the discomfort while sitting down.

After about a year, the patient was admitted to the Department of Rheumatology due to weakness and low-grade fever, with suspected exacerbation of the autoimmune disease. The patient was diagnosed with a urinary tract infection (*Staphylococcus aureus*) complicated by bacteremia. In the course of this infection, after an initial good response to targeted antibiotic therapy, the macrophage activation syndrome developed. The patient additionally received pulses of methylprednisolone (3000 mg in total) and the administration of immunoglobulins was started. After the first dose of immunoglobulins (20 g), the patient experienced a sudden increase in blood pressure with acute circulatory failure. As a result of these complications, the patient died.

#### 4. RESULTS

Dystrophic calcifications are sporadically observed in patients with SLE, with less than 50 cases being described in the literature.<sup>4,5</sup> According to some researchers, the incidence of ectopic calcifications in SLE may be higher, in a study of 60 patients with SLE, calcification was found in 40% (including periarticular and perivascular calcification – calciphylaxis).<sup>6</sup> It is worth noting that SLE patients may also develop metastatic calcifications associated with hypercalcemia<sup>7</sup> or iatrogenic calcifications, e.g. associated with injections of calcium-containing heparin.<sup>8</sup>

Dystrophic calcifications usually develop several years after the diagnosis of SLE.<sup>5</sup> The period between diagnosis and development of calcification rarely is shorter. Duration of about 5 years or less has been reported in patients with lupus panniculitis<sup>5</sup> or in a single case of extensive periarticular calcifications.<sup>9</sup> Calcifications are usually small, sparse nodules and occur around the buttocks or on the limbs.<sup>4</sup> Less typical locations were also found, e.g. on the face in the pre-ear area<sup>10</sup> or in the scalp area.<sup>11</sup> The presence of dif-

fuse calcification of the subcutaneous tissue and muscles has been described in a few cases of patients with SLE.<sup>5,12,13</sup> Calcifications forming small subcutaneous nodules are most often found in skin lesions typical of SLE.<sup>4</sup> Several cases have been described in relation to the lesions of the discoid lupus erythematosus type.<sup>11,14</sup> Shallow calcifications creating non-healing ulcers may occur with the presence of white-colored exudation containing calcium salt crystals.<sup>15</sup> In some cases, calcifications were localized in the deeper layers of the dermis and in the subcutaneous tissue, without visible changes on the skin surface or accompanied by atrophic scars.<sup>16</sup>

The mechanism of the formation of dystrophic calcifications in connective tissue diseases is unclear. The influence of two main components is reported: chronic inflammation and ischemia. In patients with lupus myopathy, calcifications may be associated with muscle damage, while calcifications in DLE with accompanying scarring.<sup>17</sup>

One hypothesis suggests that phosphorus bounded to proteins from necrotic cells is a precursor to the deposition of calcium.<sup>18</sup> According to another, alkaline phosphatase released from damaged lysosomes can cause the hydrolysis of extracellular pyrophosphates, which prevent the formation of hydroxyapatite deposits.<sup>4,19</sup> In a study conducted on a group of patients with juvenile DM and calcifications, the inflammatory cytokines IL-6, IL-1B and TNF were found in the fluid space containing non-crystallized calcium salts.<sup>20</sup> Powell developed a theory that the formation of calcifications is influenced by local ischemia of tissues related to the compression of adipose tissue overgrown under the influence of steroids.<sup>21</sup> The hypothesis about the influence of ischemia on calcification formation is supported by the observation of increased GLUT-1 (hypoxia associated glucose transporter molecule) expression in patients with lsSSc and dcSSc calcifications.<sup>22</sup>

The research of Okada, who observed more frequent formation of calcifications in SLE patients with normal parameters of calcium-phosphate metabolism receiving vitamin D<sub>3</sub> (alfacalcidol) supplementation and patients with renal lupus (excluding patients with end-stage renal failure), are noteworthy. An author suggested possible influence of vitamin D<sub>3</sub> on calcification by inducing local inflammation related to macrophage activation and the production of pro-inflammatory cytokines IL-1. He also drew attention to the possibility of subclinical renal dysfunction with accompanying parathyroid disorders, which are not yet visible in laboratory tests such as parathyroid hormone (PTH).<sup>6</sup> Our patient was treated chronically with supplementation of calcium and vitamin D<sub>3</sub> (cholecalciferol), but at the stage of calcification renal lupus was not diagnosed.

The presence of hard, calcified nodules is problematic for some patients with autoimmune diseases, especially when it includes soreness and formation of ulcers. This is particularly true for people with extensive calcifications, most often in SS and DM. In the case of SLE patients, calcified nodules were often discovered by accident during routine radiological examinations and did not display any significant symptoms, therefore treatment was not always needed.<sup>4,17</sup>

No method that would be satisfactorily effective in treatment of dystrophic calcifications has yet been presented. Systemic medications i.a. calcium channel blockers (diltiazem), bisphosphonates, colchicine, minocycline, warfarin, immunoglobulins, or procedures such as surgical removal of concrements, lithotripsy, carbon dioxide laser were used in therapy.<sup>23</sup> Diltiazem leads to the precipitation of calcium crystals. It is the most commonly used drug in calcinosis associated with connective tissue diseases and is one of the most effective solutions.<sup>5</sup> Bisphosphonates reduce bone resorption, but their efficacy in dystrophic calcifications is debatable.<sup>23,24</sup> Warfarin lower vitamin K level, which is necessary for the production of calcium-binding  $\gamma$ -glutamic acid, therefore, it reduces deposition of calcium. The positive effect of warfarin was observed mostly in small, recently formed calcifications.<sup>5</sup> Minocycline induces improvement through the anti-inflammatory effect, inhibition of metalloproteinases and calcium chelation.<sup>25</sup> Immunoglobulins reduce inflammation by influencing the functions of macrophages.<sup>26</sup> Surgical intervention is indicated in cases of calcifications, that cause significant pain.<sup>5</sup> Lithotripsy is used as adjunctive therapy of calcification of various etiologies. It causes fragmentation of calcium deposits leading to pain relief and facilitation of potential surgical intervention.<sup>27</sup> Our patient underwent this treatment method with a fairly good effect related to the reduction of the discomfort when sitting down.

In the unofficial guidelines for the treatment of dystrophic calcifications formulated by clinicians from the Mayo Clinic in 2012 based on the observation of a group of 78 patients with connective tissue diseases it is recommended as first-line treatment diltiazem 120–480 mg daily in combination with resection of calcifications, alternatively colchicine 0.6–1.8 mg daily. The experts suggest that aggressive treatment of the underlying disease can help inhibit the development of new calcifications.<sup>5</sup> The effectiveness of these methods has been reported in a series of cases and several small randomized trials have been conducted so far. In February 2020 a review was realized summarizing articles published from 1980 to July 2018 on the treatment of calcifications in DM and SS in a total of 288 patients. The greatest therapeutic efficacy of diltiazem, warfarin, rituximab, infliximab and intralesional injections of sodium thiosulfate was found, while the effectiveness of warfarin was questioned.<sup>28</sup> It seems advisable to conduct randomized trials on large groups of patients comparing the effectiveness of currently used methods.

## 6. CONCLUSION

- (1) We presented the case of a patient due to a rare coexistence of dystrophic calcifications and SLE.
- (2) Dystrophic calcifications associated with autoimmune diseases are common, but occur rarely in SLE.
- (3) Dystrophic calcifications are not associated with incorrect calcium/phosphorus levels.
- (4) The time of onset for dystrophic calcinosis is typically several years after the onset of SLE, as shown in our case.
- (5) Calcifications in cases of patients with SLE usually are not extensive and rarely requires treatment. However, in our case calcifications were associated with discomfort while sitting.
- (6) Among many treatment options it is difficult to indicate one sufficiently effective. In the presented case lithotripsy has proven to be acceptable solution.

## Conflict of interest

None declared.

## Funding

None declared.

## References

- 1 Boulman N. Calcinosis in rheumatic diseases. *Semin Arthritis Rheum.* 2005;34(6):805–812. <https://doi.org/10.1016/j.semarthrit.2005.01.016>.
- 2 Gutierrez AJ, Wetter DA. Calcinosis cutis in autoimmune connective tissue diseases. *Dermatol Ther.* 2012;25(2):195–206. <https://doi.org/10.1111/j.1529-8019.2012.01492.x>.
- 3 Reiter N. Calcinosis cutis: part I. Diagnostic pathway. *J Am Acad Dermatol.* 2011;65(1):1–12. <https://doi.org/10.1016/j.jaad.2010.08.038>.
- 4 Kim MS, Choi KC, Kim HS, Song IG, Shin BS. Calcinosis cutis in systemic lupus erythematosus: a case report and review of the published work. *J Dermatol.* 2010;37(9):815–818. <https://doi.org/10.1111/j.1346-8138.2010.00894.x>.
- 5 Balin SJ, Wetter DA, Andersen LK, Davis MDP. Calcinosis cutis occurring in association with autoimmune connective tissue disease: the Mayo Clinic experience with 78 patients, 1996–2009. *Arch Dermatol.* 2012;148(4):455–462. <https://doi.org/10.1001/archdermatol.2011.2052>.
- 6 Okada J, Nomura M, Shirataka M. Prevalence of soft tissue calcifications in patients with SLE and effects of alfacalcidol. *Lupus.* 1999;8(6):456–461. <https://doi.org/10.1177/096120339900800608>.
- 7 Zhao L, Huang L, Zhang X. Systemic lupus erythematosus-related hypercalcemia with ectopic calcinosis. *Rheumatol Int.* 2016;36(7):1023–1026. <https://doi.org/10.1007/s00296-016-3486-3>.
- 8 Hattori M, Shimizu A, Ishikawa O. Calcinosis cutis caused by subcutaneous injection of calcium-containing heparin in a patient with systemic lupus erythematosus. *Acta Derm Venereol.* 2018;98(5–6):614–615. <https://doi.org/10.2340/00015555-2927>.
- 9 Dima A, Berzea I, Baicus C. Impressive subcutaneous calcifications in systemic lupus erythematosus. *Maedica.* 2015;10(1):55–57.
- 10 Lopez AT, Grossman ME. Facial calcinosis cutis in a patient with systemic lupus erythematosus: A case report of tissue injury owing to photosensitivity as the cause of dystrophic calcification. *JAAD Case Rep.* 2017;3(5):460–463. <https://dx.doi.org/10.1016%2Fj.jdc.2017.06.018>.

- <sup>11</sup> Eastham A. Diffuse dystrophic calcinosis cutis of the scalp in a patient with scalp discoid lupus erythematosus and systemic lupus erythematosus. *JAMA Dermatol.* 2013;149(2):246–248. <https://doi.org/10.1001/jamadermatol.2013.1420>.
- <sup>12</sup> Carocha AP, Torturella DM, Barreto GR. Calcinosis cutis universalis associated with systemic lupus erythematosus: an exuberant case. *An Bras Dermatol.* 2010;85(6):883–887. <https://doi.org/10.1590/s0365-05962010000600016>.
- <sup>13</sup> Tristano AG, Villarroel JL, Rodríguez MA, Millan A. Calcinosis cutis universalis in a patient with systemic lupus erythematosus. *Clin Rheumatol.* 2006;25(1):70–74. <https://doi.org/10.1007/s10067-005-1134-5>.
- <sup>14</sup> Korekawa A, Nakajima K, Kaneko T, Nakano H, Sawamura D. Discoid lupus erythematosus with dystrophic calcinosis cutis. *JAAD Case Rep.* 2015;1(4):182–184. <https://dx.doi.org/10.1016%2Fj.jdc.2015.01.006>.
- <sup>15</sup> Lederhandler M, Valins W, Zoghbi Z, Grossman ME. Leg ulcers in systemic lupus erythematosus associated with underlying dystrophic calcinosis and bone infarcts in the absence of antiphospholipid antibodies. *JAAD Case Rep.* 2016;2(2):164–167. <https://dx.doi.org/10.1016%2Fj.jdc.2016.02.009>.
- <sup>16</sup> Gunasekera NS, Maniar LEG, Lezcano C, Laga AC, Merola JF. Intralesional sodium thiosulfate treatment for calcinosis cutis in the setting of lupus panniculitis. *JAMA Dermatol.* 2017;153(9):944–945. <https://doi.org/10.1001/jamadermatol.2017.0966>.
- <sup>17</sup> Rothe MJ, Grant-Kels JM, Rothfield NF. Extensive calcinosis cutis with systemic lupus erythematosus. *Arch Dermatol.* 1990;126(8):1060–1063.
- <sup>18</sup> Glimcher MJ, Krane SM. Studies on the interactions of collagen and phosphate. In: McLean FC, ed. *Radioisotopes and Bone. A Symposium.* Philadelphia, Pa: FA Davis Co Publishers; 1962:393.
- <sup>19</sup> Nomura M, Okada, N, Okada M, Yoshikawa K. Large subcutaneous calcification in systemic lupus erythematosus. *Arch Dermatol.* 1990;126(8):1057–1059.
- <sup>20</sup> Mukamel M, Horev G, Mimouni M. New insight into calcinosis of juvenile dermatomyositis: a study of composition and treatment. *J Pediatr.* 2001;138(5):763–766. <https://doi.org/10.1067/mpd.2001.112473>.
- <sup>21</sup> Powell RJ. Systemic lupus erythematosus with widespread subcutaneous fat calcification. *Proc R Soc Med.* 1974;67(3):215–217.
- <sup>22</sup> Davies CA, Jeziorska M, Freemont AJ, Herrick AL. The differential expression of VEGF, VEGFR-2, and GLUT-1 proteins in disease subtypes of systemic sclerosis. *Hum Pathol.* 2006;37(2):190–197. <https://doi.org/10.1016/j.humpath.2005.10.007>.
- <sup>23</sup> Valenzuela A, Chung L. Calcinosis: pathophysiology and management. *Curre Opin Rheumatol.* 2015;27(6):542–548. <https://doi.org/10.1097/bor.0000000000000220>.
- <sup>24</sup> Nunes GPS, de Souza RB, Ribeiro SLE. Dystrophic calcinosis: do we really know how to treat it?. *Acta Reumatol Port.* 2019;44(1):86–87.
- <sup>25</sup> Robertson LP, Marshall RW, Hickling P. Treatment of cutaneous calcinosis in limited systemic sclerosis with minocycline. *Ann Rheum Dis.* 2003;62(3):267–269. <https://doi.org/10.1136/ard.62.3.267>.
- <sup>26</sup> Schanz S, Ulmer A, Fierlbeck G. Response of dystrophic calcification to intravenous immunoglobulin. *Arch Dermatol.* 2008;144(5): 585–587. <https://doi.org/10.1001/archderm.144.5.585>.
- <sup>27</sup> Sultan-Bichat N, Menard J, Perceau G, Stearman F, Bernard P, Reguiaï Z. Treatment of calcinosis cutis by extracorporeal shock-wave lithotripsy. *J Am Acad Dermatol.* 2012;66(3):424–429. <https://doi.org/10.1016/j.jaad.2010.12.035>.
- <sup>28</sup> Traineau H, Aggarwal R, Monfort JB, et al. Treatment of calcinosis cutis in systemic sclerosis and dermatomyositis: a review of the literature. *J Am Acad Dermatol.* 2020;82(2):317–325. <https://doi.org/10.1016/j.jaad.2019.07.006>.