



Case study

Comparative analysis within diagnostics and treatment of retroperitoneal schwannoma

Agnieszka Grabińska¹ , Tomasz Ząbkowski¹, Sławomir Szymczyk², Anna Grabińska²

¹ Department of Urology, Military Institute of Medicine in Warsaw, Poland

² Department of Agriculture and Forestry, University of Warmia and Mazury in Olsztyn, Poland

ARTICLE INFO

Article history

Received 5 January 2021

Accepted 26 January 2021

Available online 9 February 2021

Keywords

Schwannoma

Kidney

Retroperitoneal tumor

Neoplasm

Doi

<https://doi.org/10.29089/2020.20.00144>

User license

This work is licensed under a Creative Commons Attribution – NonCommercial – NoDerivatives 4.0 International License.



ABSTRACT

Introduction: Retroperitoneal schwannoma is a rare tumor that originates from the Schwann cells of the peripheral nerve sheath. It is mostly located in the brain and spinal cord, but can affect other untypical places such as the scrotum and penis.

Aim: The aim of this study was to present two different cases of retroperitoneal schwannoma.

Case study: The authors present two cases of patients with benign and malignant retroperitoneal schwannomas (malignant peripheral nerve sheath tumor – MPNST).

Results and discussion: It has been reported that only 0.7% of schwannomas occur in the retroperitoneum. It is difficult to diagnose this tumor preoperatively because of the clinical variety and a lack of the characteristic symptoms. These tumors can mimic different conditions, such as pancreatic tail tumors, a hepatic tumor in the caudate lobe, or lymph node metastases. They can arise at any age, but generally occur between 30 and 50 years of age and develop in any race.

Based on the literature published in the last 20 years regarding schwannomas arising in retroperitoneum 20 cases were reported.

Conclusions: Careful monitoring is highly recommended after retroperitoneal schwannoma removal.

1. INTRODUCTION

Retroperitoneal schwannoma is a rare tumor that originates from the Schwann cells of the peripheral nerve sheath.¹ It is mostly located in the brain and spinal cord, but can affect other untypical places, such as the scrotum and penis. It has been reported that only 0.7% of schwannomas occur in the retroperitoneum.¹ These tumors can mimic different conditions, such as pancreatic tail tumors, a hepatic tumor in the caudate lobe, or lymph node metastases.^{2,3} They can arise at any age, but generally occur between 30 and 50 years of age and develop in any race.^{4,5} Schwannomas arise as solitary tumors or as part of a systemic disease that can involve the nervous system.⁶ The etiology of these tumors is unknown. They develop slowly, occur incidentally, and mostly affect the flexor extremity, neck, mediastinum, thoracic cavity, retroperitoneum, posterior spinal roots, pelvis, and genitals, including the scrotum and penis.^{5,7}

2. AIM

The aim of this study is to present two different cases of retroperitoneal schwannoma.

3. CASE STUDY

Case I

A 63-year-old man was admitted to the Department of Urology with a tumor 70 mm in diameter in the left retroperitoneal space that was accidentally detected by US. The patient indicated no symptoms regarding the urinary system. During the physical examination, the tumor was not palpable by abdominal integuments. Biochemical and morphological examinations were performed. CT showed a 70 × 50 mm solid cystic tumor including the medial part of the left kidney, the tail of the pancreas, and adherent to the abdominal aorta. MRI showed a large, non-homogenous tumor with solid and liquid elements. The tumor presented non-homogenous contrast enhancement, and the solid liquid change adhered to the tail of the pancreas, the left adrenal gland, and the abdominal aorta.

Considering the uncertain origin of the tumor, from the kidney or the pancreas, the patient was treated with a laparotomy. Large tumors that include the left kidney, tail of the pancreas, and abdominal aorta have been shown to be operative. The mass was removed with the left kidney and part of the tail of the pancreas (Figure 1).

To prepare tumor in the abdominal aorta area, the aorta was opened and provided with a vascular suture.

The histopathological examination showed a large retroperitoneal schwannoma. After one, two, three, and four years, the CT of the abdominal cavity did not show any tumor recurrence (Figure 2).

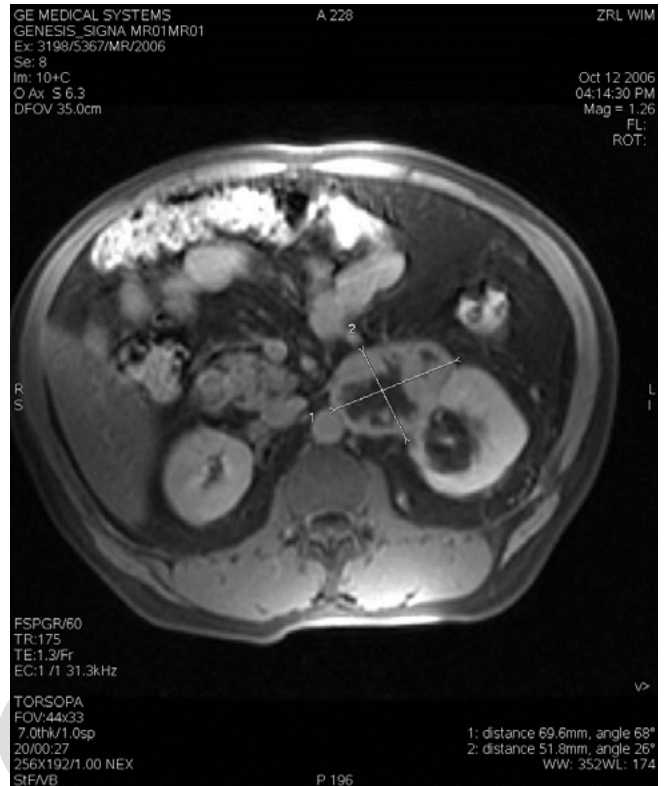

Figure 1. The solid liquid change adhered to the tail of the pancreas, the left adrenal gland, and the abdominal aorta. CT showed a large, non-homogenous left tumor with solid and liquid elements as well as a small amount of calcification.

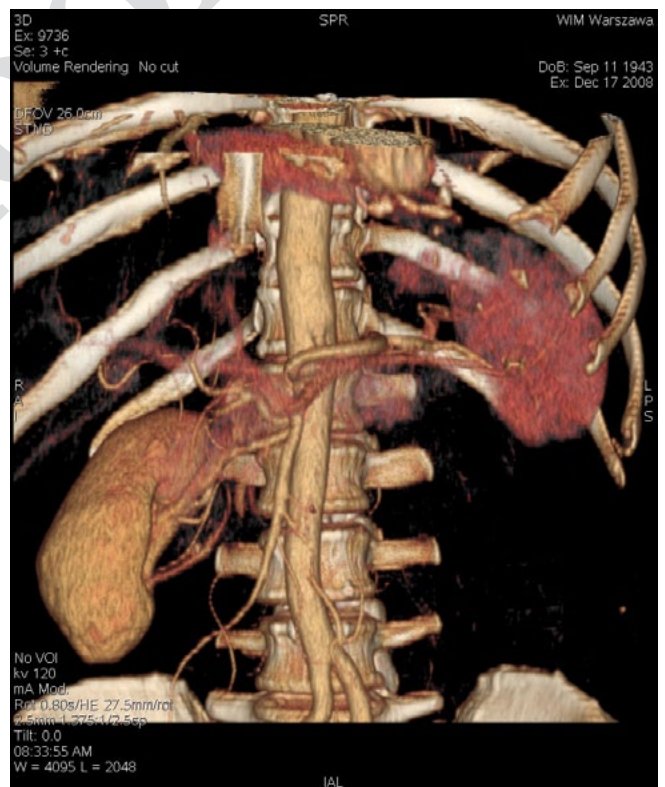


Figure 2. After one, two, three, and four years, the computed tomography of the abdominal cavity did not show any tumor recurrence.

Case II

A 65-year-old patient was admitted to the Department of Urology and classified for operative treatment of a tumor of the right retroperitoneal space, which was incidentally detected by US. The patient indicated no symptoms from the urinary system. Morphological and biochemical tests showed no deviation from the norm. During a physical examination, the tumor was impalpable. CT showed a 9.5 × 8.0 cm tumor and infiltrated the psoas muscle greater and trapezium loin muscle. A large tumor size, of 10 cm, was identified intra-operatively, and the tumor infiltrated the lower kidney pole, raising and going under the caval vein (Figure 3).

A tumor with a rich, additional vascularization and solid adhesions to the back abdominal wall and spinal area was found. By sharply dissecting the adhesions of the tumor with the caval vein inferior, the tumor was removed.

The kidney with the capsule was dissected sharply on the back wall with part of the psoas muscle. An increased numbers of lymph nodes was not been identified.

The histopathological examination revealed a malignant schwannoma. After four months, the CT did not show any tumor recurrence.

In the following CT examination after eight months, tumor recurrence was observed, as well as a large, visible change in the nephrectomy site. This change started from the level below the outgoing of superior mesenteric artery near the aorta and spread on the right side of the aorta in the retroperitoneal space. This change reached the pelvis minor and finished just over the urinary bladder, with a size of 10 × 11 × 19 cm (Figure 4).

The patient was treated with a laparotomy, and the tumor was radically removed. In the histopathological examination, liposarcoma myxomatousum G-1 was diagnosed. The patient was treated with chemotherapy and died a few months after the surgery, due to increasing circulatory system involvement and respiratory failure that resulted from the tumor.

4. RESULTS AND DISCUSSION

Schwannomas can arise as solitary tumors or as part of a systemic disease that involves the nervous system.⁶ None of our patients showed any other systematic disease symptoms. Patients often do not show any features of the disease or do not experience characteristic pain in the flank of the abdomen on the side of the tumor. Schwannomas can be benign or malignant tumors, occur regardless of sex, and can be associated with von Recklinghausen disease, all of which were not associated with our patients.⁴

The etiology of these tumors remains unknown. They develop slowly, occur incidentally, and mostly affect the flexor extremity, neck, mediastinum, thoracic cavity, retroperitoneum, posterior spinal roots, pelvis, and genitals, including the scrotum and penis.^{5,7} The CT scan showed schwannomas, which are characterized by central necrosis, internal cystic schema, and low density.^{8,9}

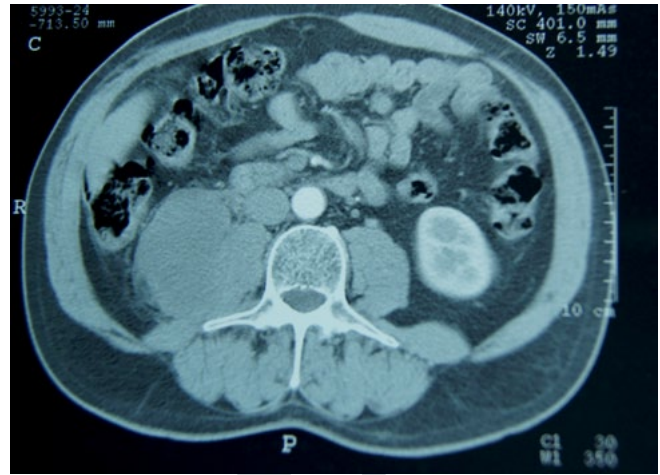


Figure 3. A large tumor mass was detected on the right side in CT – the tumor measured 9.5 x 8.0 cm, and infiltrated the psoas muscle greater and a trapezium loin muscle, with rich, additional vascularization in solid adhesions to the back abdominal wall and the spinal area.

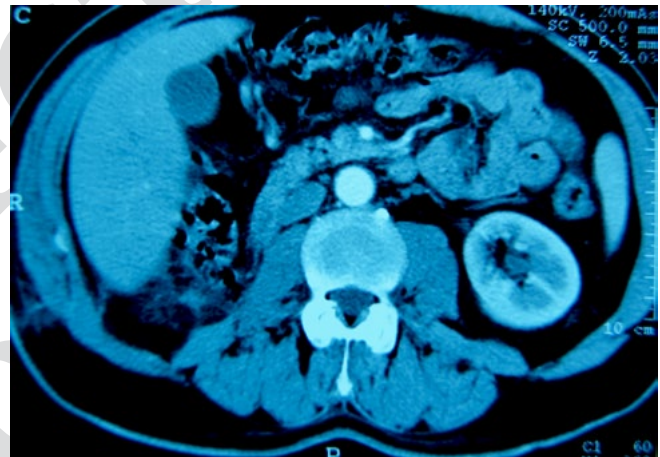


Figure 4. In the following CT examination after eight months, tumor recurrence was observed.

Malignant transformation of the benign schwannoma is possible, so patient follow-up is highly recommended.¹⁰

Pathological retroperitoneum changes support an exact differential diagnosis, although the histopathological examination determines the final diagnosis.

En-block resection of a mass is treatment of choice.¹¹

5. CONCLUSIONS

Careful monitoring is highly recommended after retroperitoneal schwannoma removal.

Conflict of interest

None declared.

Funding

None declared.

Acknowledgement

We thank our colleagues from our department who provided insight and expertise that greatly assisted the research.

References

- ¹ Das Gupta TK, Brasfield RD. Solitary malignant schwannoma. *Ann Surg.* 1970;171(3):419–428. <https://dx.doi.org/10.1097%2F00000658-197003000-00016>.
- ² Pakla P, Lewandowski B. The case of malignant peripheral nerve sheath tumor of the cheek. *Pol Ann Med.* 2016;23(2):172–176. <http://dx.doi.org/10.1016/j.poamed.2016.03.002>.
- ³ Hsiao WC, Lin PW, Chang KC. Benign retroperitoneal schwannoma. *Scand J Urol Nephrol.* 1992;26(1):85–87. <https://doi.org/10.3109/00365599209180403>.
- ⁴ Safak M, Baltaci S, Yaman S, Uluoglu O, Eryilmaz Y. Intrascrotal extratesticular malignant schwannoma. *Eur Urol.* 1992;21(4):340–342. <https://doi.org/10.1159/000474870>.
- ⁵ Aricola AJ, Golden S, Zapinsky J, Fracchia JA. Primary intrascrotal nontesticular schwannoma. *Urology.* 1995;26(3):304–306. [https://doi.org/10.1016/0090-4295\(85\)90135-9](https://doi.org/10.1016/0090-4295(85)90135-9).
- ⁶ Sato D, Kase T, Tajima M, et al. Penile schwannoma. *Int J Urol.* 2001;8(2):87–89. <https://doi.org/10.1046/j.1442-2042.2001.00248.x>.
- ⁷ Guha A, Bilbao J, Kine DG, Hudson AR. Tumors of the peripheral nervous system, In: Youman J, ed. *Youman's Neurological Surgery.* 4th Ed. Vol. 4. Philadelphia: W.B. Saunders 1996:3175–3187.
- ⁸ Okamura K, Ito K, Aota Y, Suzuki Y, Shimoji T. [A case report of retroperitoneal malignant schwannoma]. *Hinyokika Kyo.* 1984;30(8):1045–1051 [in Japanese].
- ⁹ Barrero Candau R, Ramirez Mendoza A, Morales Lopez A, et al. [Benign adrenal schwannoma]. *Arch Esp Urol.* 2002;55(7):858–860 [in Spanish].
- ¹⁰ Shamsa A, Omid A. Huge primary intrascrotal Schwannoma: a case report and review of the literature. *Med J Islam Repub Iran.* 2004;18(1):85–86.
- ¹¹ Janaka A, Hettiarachchi Michael P, Finkelstein Alec M, et al. A Benign retroperitoneal Schwannoma presenting as a giant adrenal tumour. *Urol Int.* 2003;71(2):231–232. <https://doi.org/10.1159/000071857>.