



Research paper

A five-year experience in endoscopic endonasal excision of juvenile nasopharyngeal angiofibroma

Siew Chung Cheah^{1,2} , Li Yun Lim^{2,3} , Salina Husain¹ , Ing Ping Tang^{2,3} 

¹ Department of Otorhinolaryngology-Head and Neck Surgery, Faculty of Medicine, Universiti Kebangsaan Malaysia Medical Centre, Kuala Lumpur, Malaysia

² Department of Otorhinolaryngology-Head and Neck Surgery, Sarawak General Hospital, Sarawak, Malaysia

³ Department of Otorhinolaryngology-Head and Neck Surgery, Faculty of Medicine and Health Sciences, Universiti Malaysia Sarawak, Sarawak, Malaysia

ARTICLE INFO

Article history

Received 30 January 2021

Accepted 11 March 2021

Available online 24 August 2021

Keywords

Juvenile nasopharyngeal angiofibroma

Endoscopic approach

Endoscopic endonasal

Doi

<https://doi.org/10.29089/2020.20.00175>

User license

This work is licensed under a Creative Commons Attribution – NonCommercial – NoDerivatives 4.0 International License.



ABSTRACT

Introduction: Juvenile nasopharyngeal angiofibroma (JNA) is a histological benign but locally aggressive vascular tumour which can invade the base of skull.

Aim: This is a retrospective study with the aim to examine the outcome of patients with JNA and endoscopic endonasal excision of tumour at a tertiary center in Malaysia.

Material and methods: 9 patients were identified from the medical record office from 2015 to 2019. We review the data on patient demographics, clinical presentations, laboratory investigations, intraoperative blood loss and duration of hospital stay.

Results and discussion: 8 patients were male, 1 was female. The average age of diagnosis was 15 (range 11 to 29) years. The commonest chief complaint was recurrent epistaxis, followed by nasal obstruction and nasal discharge. Three patients were at stage I, 4 patients at stage II, 1 patient at stage III and 1 patient at stage IV based on Fisch classification. All patients underwent primary endoscopic endonasal excision of tumour with no vascular, ophthalmological or neurological complication. Seven patients had preoperative embolization done. Average operation time was 137 minutes (range 60–360 minutes). Intraoperative blood lost varied from 500 mL to 1300 mL (mean 777.7 mL). All patients were discharged well with no recurrence.

Conclusions: The management of JNA can be challenging. The current shift in management favouring endoscopic endonasal excision of JNA reduces postoperative morbidity. It is possible to be applied on all stages of tumour with good success rate.

1. INTRODUCTION

Juvenile nasopharyngeal angiofibroma (JNA) is an uncommon, highly vascular tumour that is mostly seen in adolescent boys. Although it only accounts for 0.05% to 0.5% of all head and neck tumours, it is the commonest benign tumour at the nasopharynx.^{1,2} JNA originates from the posterosuperior aspect of sphenopalatine foramen, in the region of pterygoid canal. Despite it being slow growing and histologically benign, JNA can erode the surrounding structure and spread through natural foramina or fissure. It can extend to occupy nasopharynx, paranasal sinuses, posteriorly into sella and cavernous sinus, laterally into pterygopalatine fossa and infratemporal fossa, into the orbit through inferior orbital fissure, into the skull base and even intracranial extension in up to 20% of patients.^{3,4} Under histopathological examination (HPE), JNA is an unencapsulated tumour, consisting of wide vascular spaces and only single-layered lining of endothelial, which explains the phenomenon of easy bleeding and recurrent epistaxis in patient with JNA.^{4,5}

The clinical presentations vary depending on the extent of tumour, typically unilateral nasal blockage, epistaxis and rhinorrhoea. Proptosis, headache, facial deformity and cranial nerves palsy may also result due to its ability for local invasion.⁶ Massive, life threatening haemorrhage can also occur as it is highly vascularized.³ A thorough history and clinical examination with nasal endoscopy is important in making the diagnosis. Investigations include imaging study with contrast-enhanced computed tomography (CT) and magnetic resonance imaging (MRI) is the standard of care, helping to establish the site of tumour, the extent of involvement of surrounding vital structures and staging of tumour. Preoperative angiogram and embolization can be considered, especially for large tumours.^{1,2} Preoperative biopsy is not recommended as the tumour may bleed torrentially.⁵ Hence the HPE result usually can only be available after complete excision of tumour. Traditionally, the operation was performed through open surgical approaches such as lateral rhinotomy, midface degloving and concomitant craniotomy. However, endoscopic endonasal approach is more popular and preferable nowadays.

2. AIM

The purpose of this paper is to review the outcomes of cases with JNAs with endoscopic endonasal excision at a tertiary center in Malaysia.

3. MATERIAL AND METHODS

This is a retrospective review involving 9 patients with JNA treated at a tertiary center from 2015 to 2019 with pure endoscopic endonasal approach. HPE of specimens were available in all patients for confirmation of diagnosis. We collected and reviewed data on patient demographics, clinical

Table 1. JNA classification according to Fisch.

Stage	Description
I	Tumours limited to nasal cavity, nasopharynx with no bony destruction
II	Tumours invading pterygomaxillary fossa, paranasal sinuses with bony destruction
III	Tumours invading infratemporal fossa, orbit and/or parasellar region remaining lateral to cavernous sinus
IV	Tumours invading cavernous sinus, optic chiasmal region, and/or pituitary fossa

presentations, laboratory investigations and treatments. The duration of operation, intraoperative blood loss, need for blood transfusion and duration of hospital stays were analysed. All tumours were classified according to the Fisch classification system based on the CT report (Table 1).⁷

The nasal cavity was first packed with cotton swab impregnated with Moffett's solution (4 mL sodium bicarbonate – 8.4%, 2 mL cocaine – 10.0%, 1 mL adrenaline – ratio 1 : 1000, and 13 mL of water) for 20 minutes after anaesthesia induction.⁸ After removal of the nasal packing, local anaesthesia was infiltrated into the lateral nasal cavity mucosa using mepivacaine (2%) with levonordefrin (1 : 20000). The 'two nostrils – four hand' technique was applied to all patients. In order to improve the visualization and access of surgical field within nasal cavity, posterior septectomy and medial maxillectomy at the side of tumour were performed. To cover the exposed bone, a nasoseptal rescue flap or Hadad-Bassagatiguy flap was raised with a L-hook monopolar diathermy and freer elevator to cover the exposed bone if any. Sphenopalatine artery was ligated by using a bipolar diathermy. Subsequently, tumour debulking was performed with microdebrider and bipolar diathermy. The posterior maxillary wall and vertical plate of palatine bone were removed to expose the pterygopalatine fossa if the tumour involved pterygopalatine fossa or infratemporal fossa. After complete removal of tumour, haemostasis was achieved with warm saline irrigation, bipolar diathermy and compressed with ribbon gauze soaked in 1 : 1000 adrenaline solution. Hadad-Bassagatiguy flap was laid over the exposed bone and held with Foley's catheter, supported by Merocel nasal packing. Nasal packing was kept for at least 48 h before removal.

4. RESULTS

A total of 9 patients were diagnosed as JNA from 2015 to 2019. There were 8 (88.9%) male and 1 (11.1%) female. Mean age at diagnosis was 15 years (range 11–29 years old). The patient who presented at age of 29 to our center had his first operation done for JNA 10 years before. In the study group of 9 patients, 2 were Malay, 2 were Chinese and 5 were local ethnic (2 Bidayuh, 2 Iban and 1 Melanau). Those patients were either referred from secondary centers or Emergency Department.

All patients presented with recurrent epistaxis as the chief complaint. Other symptoms included nasal blockage (44.4%) and rhinorrhoea (33.3%). Nasal endoscopic exami-

Table 2. Patient data in relation to tumour staging, preoperative embolization, operative time, blood loss and duration of hospital stay post-operation.

Patient	Fisch staging	Preoperative embolization	Operative time, minutes	Blood loss, mL	Duration of hospital stay, days
1	II	Yes	135	1100	2
2	I	No	150	500	5
3	III	Yes	140	500	4
4	I	Yes	90	1200	3
5	II	Yes	125	700	3
6	I	Yes	60	500	5
7	II	Yes	105	600	2
8	II	No	70	600	2
9	IV	Yes	360	1300	5

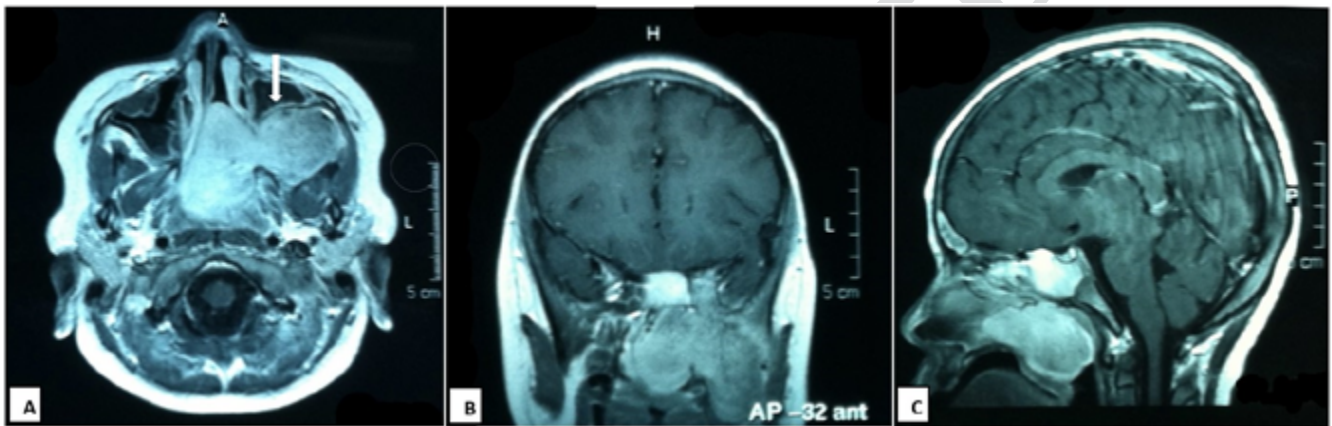


Figure 1. T1 weighted- postcontrast MRI in (A) axial, (B) coronal and (C) sagittal view demonstrate a left sided enhancing nasopharyngeal mass extending to left infratemporal fossa, erosion of basisphenoid involving left cavernous sinus and anterior bowing of the posterior wall of the left maxillary sinus – Holmann Miller sign (A, white arrow).

nation of nasal cavity was performed for all patients and revealed nasopharyngeal mass on the left in 6 patients (66.7%) and on the right in 3 patients (33.3%).

Contrast enhanced computed tomography (CECT) scan was performed for all patients as an initial assessment; 3 of them had additional MRI scan. Fisch classification was used to stage the tumours according to their CT scan findings: 3 (33.3%) patients were at stage I, 4 (44.4%) patients at stage II, 1 (11.1%) patient at stage III and 1 (11.1%) patient at stage IV (Figure 1). Angiography imaging showed 8 tumours (88.9%) which had blood supply mainly from ipsilateral maxillary arteries and 1 tumour (11.1%) with equal supply from bilateral maxillary arteries (Figure 2).

Seven patients underwent angiography with selective embolization of maxillary artery and sphenopalatine artery 24 h prior to surgery with no complication. The average operation time was 137 minutes (range: 60–360 minutes). The intraoperative surgical blood loss varied from 500 mL to 1300 mL (mean 777.7 mL). Four patients required intraoperative blood transfusion. The duration of hospital stays range 2–5 days with an average of 3.5 days (Table 2). None of the patients had any vascular, ophthalmological or neurological complications. Postoperative nasal packing was done in all patients.

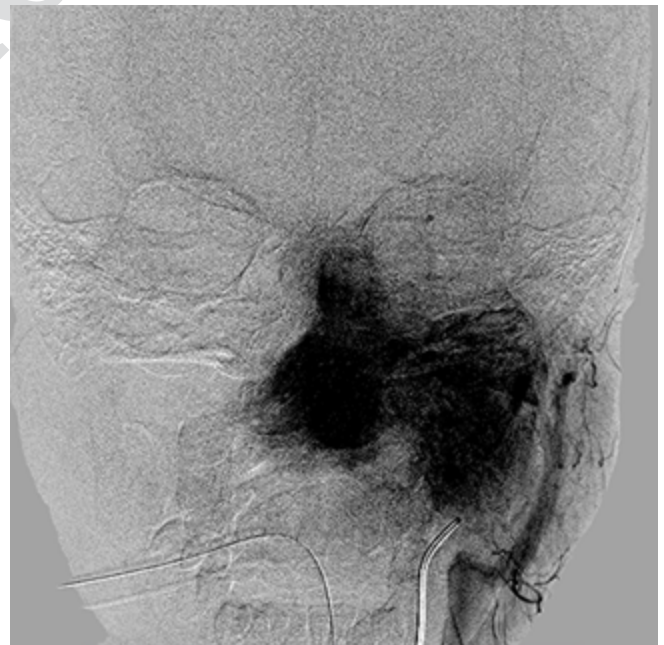

Figure 2. Angiography demonstrates the JNA is supplied by left maxillary artery.

All patients were followed up in the current center for at least 1 year and subsequent follow up was continued at the nearest hospital with otorhinolaryngology surgeon. There was no recurrence detected during follow up for all patients.

5. DISCUSSION

JNA is a disease mostly seen in male adolescents from ages 14 to 25 years. In this paper, 8 out of 9 patients were male and the mean age of diagnosis was 15. This is consistent with the demographical data from previous studies.^{1-3,5-6,9-10} Patients usually present with spontaneous recurrent epistaxis, nasal blockage and discharge. Other clinical presentations may vary depending on the size and extent of the tumour.

The diagnosis of JNA is essentially based on high index of suspicion in male adolescent group, together with detail clinical history, physical examination including nasal endoscopy and is supplemented with imaging studies such as CT or MRI.¹ Biopsies to establish histological diagnosis are not recommended due to the risk of haemorrhage.^{2,5,6}

CT and MRI are two primary imaging modalities that have been used widely in the diagnosis and staging of JNA. CT is more superior in identifying the presence of bony erosion and invasion over sphenoid bone and skull base while MRI is preferred in demonstrating soft tissue, bone marrow and intracranial involvement.¹¹ With proper imaging study, the precise location of the tumour can be identified and this can be utilized for image guided surgery if the service is available.

Preoperative embolization of feeding vessel was suggested in some studies to reduce intraoperative risk of bleeding.^{2,4-6,12} In this study, 77.8% of patients had angiography and embolization done 24 h prior to operation; 85.7% had embolization of internal maxillary arteries and 14.3% had embolization of sphenopalatine arteries. As a patient in the non-embolized group was a recurrent case with stage I tumour, the time of operation was significantly shorter with lesser blood loss. The data from this patient reduces the total duration of operation among non-embolized group in this small sample size data. In contrast, a higher stage of tumour and possibility of incomplete embolization can contribute to higher risk of major bleed among patients who had embolization.¹³

The primary treatment for JNA is surgical excision of the tumour. Radiotherapy is reserved for unresectable lesions or recurrent cases involving critical anatomical sites.^{13,14} Surgical therapies are mainly divided into open and endoscopic approaches. The traditional open approaches have disadvantages of increased morbidity and complications including hypoesthesia, massive haemorrhage, facial scarring and affecting the facial bone growth, all of which are not seen with endoscopic technique.¹⁰ The advancement in instruments for endoscopic endonasal excision of JNA also contributed to the paradigm shift favouring this technique. There was suggestion from previous study that the role of endoscopic technique may be limited, especially in stage III and IV tumours due to the space limitation in a confined nasal cavity and intracranial involvement.¹ Combine surgery

with neurosurgeon may be needed if craniofacial approach is required.¹ However, in this study, all stage I to IV tumours were removed through endoscopic technique.

Together with preoperative embolization, endoscopic approaches can reduce the operative time and also blood loss. The average duration of operation for open approaches ranged 240–500 minutes with the total blood loss of 1.5–4.0 L according to data from previous studies.^{4,5,10} The longest duration of surgery in this paper was 360 minutes, on a patient with stage IV tumour, with total blood loss of 1.3 L. This shows the potential for reduction of operating time and blood loss with endoscopic technique as compared to open surgery. The need for blood transfusion can be reduced and thus reduce occurrence of any blood transfusion related adverse events. With lesser post-operative morbidity, the duration of hospital stay also decreases. In previous papers, the average length of hospital stays ranged from 7 to 10 days for open approaches as compared to the current paper with mean hospital stays of 3.5 days only.^{4,5,9-10} Only 1 patient with stage IV tumour required intensive care unit admission for 1 day due to prolonged operation time and higher amount of blood loss.

JNA has the tendency to recur, especially for large tumours with incomplete excision. Massive haemorrhage obscuring surgical field or tumours involving critical areas are the other factors which can contribute to incomplete excision.¹² The recurrence rate is about 30%–50% based on previous studies, up to 28% of patients can have multiple recurrences.¹⁵⁻¹⁷ Whether the preoperative embolization causes the recurrence is still debatable.^{6,9} Endoscopic technique has shown better results with fewer recurrence.^{2,4,10} The recurrence rate is 0% in this paper after one year of follow up.

5. CONCLUSIONS

JNA is a benign yet highly vascular tumour. Endoscopic endonasal removal of JNA can be challenging. However, this technique is effective with the advantage of less morphological disturbance, less morbidity and possibility to be utilized for all stages of tumour. This is shown in the current report with less intraoperative blood loss, shorter hospital stays and no recurrence.

Conflict of interests

None declared.

Funding

None declared.

Ethics

This study did not involve any intervention on patient and special application from ethic committee was not applicable. There was no picture/figure which will disclose the patient's identity, so no informed consent was needed.

References

- ¹ Mann WJ, Jecker P, Amedee RG. Juvenile Angiofibromas: Changing surgical concept over the last 20 years. *Laryngoscope*. 2004;114(2):291–293. <https://doi.org/10.1097/00005537-200402000-00020>.
- ² Lim LY, Mohamad I, Tang IP. Endoscopic excision of juvenile nasopharyngeal angiofibroma: A case series. *Egypt J ENT All Sci*. 2017;18(2):173–176. <https://doi.org/10.1016/j.ejenta.2016.12.007>.
- ³ Scholtz AW, Appernroth E, Kammen-Jolly K, Scholtz LU, Thumfart WF. Juvenile Nasopharyngeal Angiofibroma: Management and Therapy. *Laryngoscope*. 2001;111(4 Pt 1):681–687. <https://doi.org/10.1097/00005537-200104000-00022>.
- ⁴ Pryor S, Moore EJ, Kasperbauer JL. Endoscopic versus traditional approaches for excision of juvenile nasopharyngeal angiofibroma. *Laryngoscope*. 2005;115(7):1201–1206. <https://doi.org/10.1097/01.mlg.0000162655.96247.66>.
- ⁵ Tang IP, Shshinder S, Gopala KG, Narayanan P. Juvenile nasopharyngeal angiofibroma in a tertiary centre: Ten-year experience. *Singapore Med J*. 2009;50(3):261–264.
- ⁶ Gaillard AL, Anastácio VM, Piatto VB, Maniglia JV, Molina FD. A seven-year experience with patients with juvenile nasopharyngeal angiofibroma. *Braz J Otorhinolaryngol*. 2010;76(2):245–250.
- ⁷ Fisch U. The infratemporal fossa approach for nasopharyngeal tumours. *Laryngoscope*. 1983;93(1):36–44. <https://doi.org/10.1288/00005537-198301000-00007>.
- ⁸ Benjamin E, Wong DK, Choa D. ‘Moffett’s’ solution: A review of the evidence and scientific basis for the topical preparation of the nose. *Clin Otolaryngol Allied Sci*. 2004;29:582–587. <https://doi.org/10.1111/j.1365-2273.2004.00894.x>.
- ⁹ Midilli R, Karci B, Akyildiz S. Juvenile nasopharyngeal angiofibroma: Analysis of 42 cases and important aspects of endoscopic approach. *Int J Pediatr Otorhinolaryngol*. 2009;73(3):401–408. <https://doi.org/10.1016/j.ijporl.2008.11.005>.
- ¹⁰ Hackman T, Snyderman CH, Carrau R, Vescan A, Kassam A. Juvenile nasopharyngeal angiofibroma: The expanded endonasal approach. *Am J Rhinol Allergy*. 2009;23(1):95–99. <https://doi.org/10.2500/ajra.2009.23.3271>.
- ¹¹ Alimli AG, Ucar M, Oztunali C, et al. Juvenile nasopharyngeal angiofibroma: Magnetic resonance imaging findings. *J Belg Soc Radiol*. 2016;100(1):63. <https://dx.doi.org/10.5334%2Fjbr-btr.1090>.
- ¹² Wormald PJ, Hasselt AV. Endoscopic removal of juvenile angiofibromas. *Otolaryngol Head Neck Surg*. 2003;129(6):684–691. [https://doi.org/10.1016/s0194-5998\(03\)01580-8](https://doi.org/10.1016/s0194-5998(03)01580-8).
- ¹³ Eloy P, Watelet JB, Hatert AS, de Wispelaere J, Bertrand B. Endonasal endoscopic resection of juvenile nasopharyngeal angiofibroma. *Rhinology*. 2007;45(1):24–30.
- ¹⁴ McAfee WJ, Morris CG, Amdur RJ, Werning JW, Mendenhall WM. Definitive radiotherapy for juvenile nasopharyngeal angiofibroma. *Am J Clin Oncol*. 2006;29(2):168–170. <https://doi.org/10.1097/01.coc.0000203759.94019.76>.
- ¹⁵ McCombe A, Lund VJ, Howard DJ. Recurrence in juvenile angiofibroma. *Rhinology*. 1990;28(2):97–102.
- ¹⁶ Harma RA. Nasopharyngeal angiofibroma. *Acta Otolaryngol*. 1958;49:1–76. <https://doi.org/10.1007/BF02992425>.
- ¹⁷ Itoo FA, Iqbal I, Chiesti LA. Juvenile nasopharyngeal angiofibroma; A tertiary hospital – based experience. *Indian J Clin Prac*. 2014;25(4):352–355.