



## Case report

# Native lung hyperinflation after single lung transplantation – case report and literature review

**Kajetan Kielbowski<sup>1</sup>** , **Nikola Ruszel<sup>1</sup>**, **Seweryn Skrzyniarz<sup>1</sup>**, **Maria Piotrowska<sup>2</sup>**,  
**Tomasz Grodzki<sup>2</sup>**, **Michał J. Kubisa<sup>2</sup>**, **Bartosz Kubisa<sup>2</sup>**

<sup>1</sup> Student Scientific Society, Pomeranian Medical University, Szczecin, Poland

<sup>2</sup> Department of Thoracic Surgery and Transplantation, Pomeranian Medical University, Szczecin, Poland

## ARTICLE INFO

### Article history

Received 2 February 2021

Accepted 12 March 2021

Available online 23 March 2021

### Keywords

Lung transplantation

Pneumonectomy

Hyperinflation

### Doi

<https://doi.org/10.29089/2020.20.00147>

### User license

This work is licensed under a  
Creative Commons Attribution –  
NonCommercial – NoDerivatives  
4.0 International License.



## ABSTRACT

**Introduction:** Single lung transplantation (SLuTx) is a challenging operation for patients with end-stage chronic pulmonary diseases. After surgery, native lung hyperinflation (NLH) and a mediastinal shift may develop, which changes the anatomical position of the lungs and heart and may lead to graft compression.

**Aim:** We present a case report of a patient who developed NLH after SLuTx. We discuss the treatment methods and compare the outcomes with other case reports and analysis from world literature.

**Case study:** A 56-year-old female patient was diagnosed with end-stage chronic obstructive pulmonary disease ( $FEV_1 < 30\%$ ) and qualified for right SLuTx. After the procedure, spirometry revealed gradual loss in FEV1. Radiological images confirmed NLH and compression of the graft. Therefore, a native lung pneumonectomy was performed with positive outcomes.

**Results and discussion:** NLH is a known complication of SLuTx. Typically, lung volume reduction surgery is performed to reduce the compression and a pneumonectomy is a rare treatment, even in centres with extensive experience with SLuTx.

**Conclusions:** Despite SLuTx being a common approach in many pulmonary diseases, NLH should be always taken into consideration. Hyperinflation could cause a dangerous loss of respiratory efficiency and require invasive surgeries for lung transplant recipients.

## 1. INTRODUCTION

Lung transplantation (LuTx) is a life-saving procedure for patients with end-stage lung diseases that have not responded well to conventional treatment. Among others, chronic obstructive pulmonary disease (COPD), idiopathic pulmonary fibrosis (IPF), cystic fibrosis (CF), primary pulmonary hypertension and bronchiectasis are common indications for the procedure. Single LuTx (SLuTx) is a method used in patients who do not suffer from septic lung disease in order to avoid contamination of the new lung with infection. The criteria for a COPD patient to qualify for LuTx consist of a forced expiratory volume in 1 s ( $FEV_1$ ) less than 25%,  $PaCO_2 > 55$  mm Hg and BODE 7–10 (index involves BMI, airway obstruction, dyspnea, exercise).<sup>1</sup>

## 2. AIM

We present the case of a COPD patient that underwent SLuTx and developed hyperinflation and a mediastinal shift postoperatively, ending in a native lung pneumonectomy. Diagnostic evaluation and treatment are discussed with a review of other cases from world literature.

## 3. CASE STUDY

In 2010, a 56-year-old female patient was admitted to the hospital due to worsening respiratory efficiency, which had been deteriorating for the past 2 years. The patient was diagnosed with COPD. Since June of 2010, domestic oxygen therapy had been applied. A radiological scan of the chest revealed advanced emphysema of the lungs. In January 2011, COPD progressed to stage 4 (with  $FEV_1 < 30\%$ ). As a result, the patient qualified for a right SLuTx. Pulmonary function tests showed a severe obstructive defect, with  $FEV_1$  15.3% of predicted value and  $FEV_1$  and FVC ratio of 32.8%. A blood gas test showed hypercapnia  $pCO_2$  53 mm Hg and  $pO_2$  62 mm Hg, indicating hypoxia, despite being on supplemental oxygen therapy. The patient demonstrated a significant decrease in exercise tolerance, as measured by the 6-minute walk test (6MWT) with a result of 165 m. Right SLuTx was performed on December 21, 2011 at the Department of Thoracic Surgery and Transplantation, Pomeranian Medical University in Szczecin, Poland. An anterolateral thoracotomy in the 5th intercostal

space was carried out. The pleural cavity was clear, and the lungs were thin and emphysematous, without focal lesions. There were no postoperative complications, blood gas examination showed approximately:  $pCO_2$  38.9 mm Hg,  $pO_2$  74.8 mm Hg with  $FEV_1$  71% of predicted value and  $FEV_1$  and FVC ratio of 74% (Table 1) on January 1, 2012. Immunosuppression consisted of cyclosporine, mycophenolate mofetil and corticosteroids. In 2014, computer tomography (CT) revealed progression of emphysema in the left (native) lung and a mild mediastinal shift towards the right side. In 2015 a spirometry test was performed, which presented reduced  $FEV_1$  to 56%. At the beginning of 2016, a bronchoscopy showed narrowing of the right segmental bronchi as a result of the native lung shifting. A CT presented small opacities (less than 1 cm) in II and VI segments of the right lung. In January 2017, plethysmography revealed increased resistance of the air passages. In April and December of 2017, two 6MWTs were carried out that showed distances of 558 m and 420 m, respectively. Subsequently, additional opacities in right lung were detected. In April 2018, the patient was feeling very weak. She had problems carrying out the spirometry test, which ultimately showed just 45% of the  $FEV_1$ . During that time, the shift of the left lung progressed as well (Figure). Consequently, 3 months later (July 6, 2018) it was decided to perform the left lung pneumonectomy. There were no complications during surgery. Histopathological examination confirmed emphysema in the left lung and revealed focal inflammation (due to atelectasis, without any neoplasm formation).

Just a month later  $FEV_1$  showed enormous improvement of 74% of predicted value comparing to tests before the pneumonectomy. At the end of 2018, another 6MWT was performed with result of 360 m. In March 2019, a CT revealed a small pneumothorax in right middle and bottom lung fields. Furthermore, the mediastinum was shifted towards the left side. During hospitalisation, inflammation in the remaining lung was revealed in addition to reduced organ function. The patient was treated with corticosteroids and discharged in a good state.

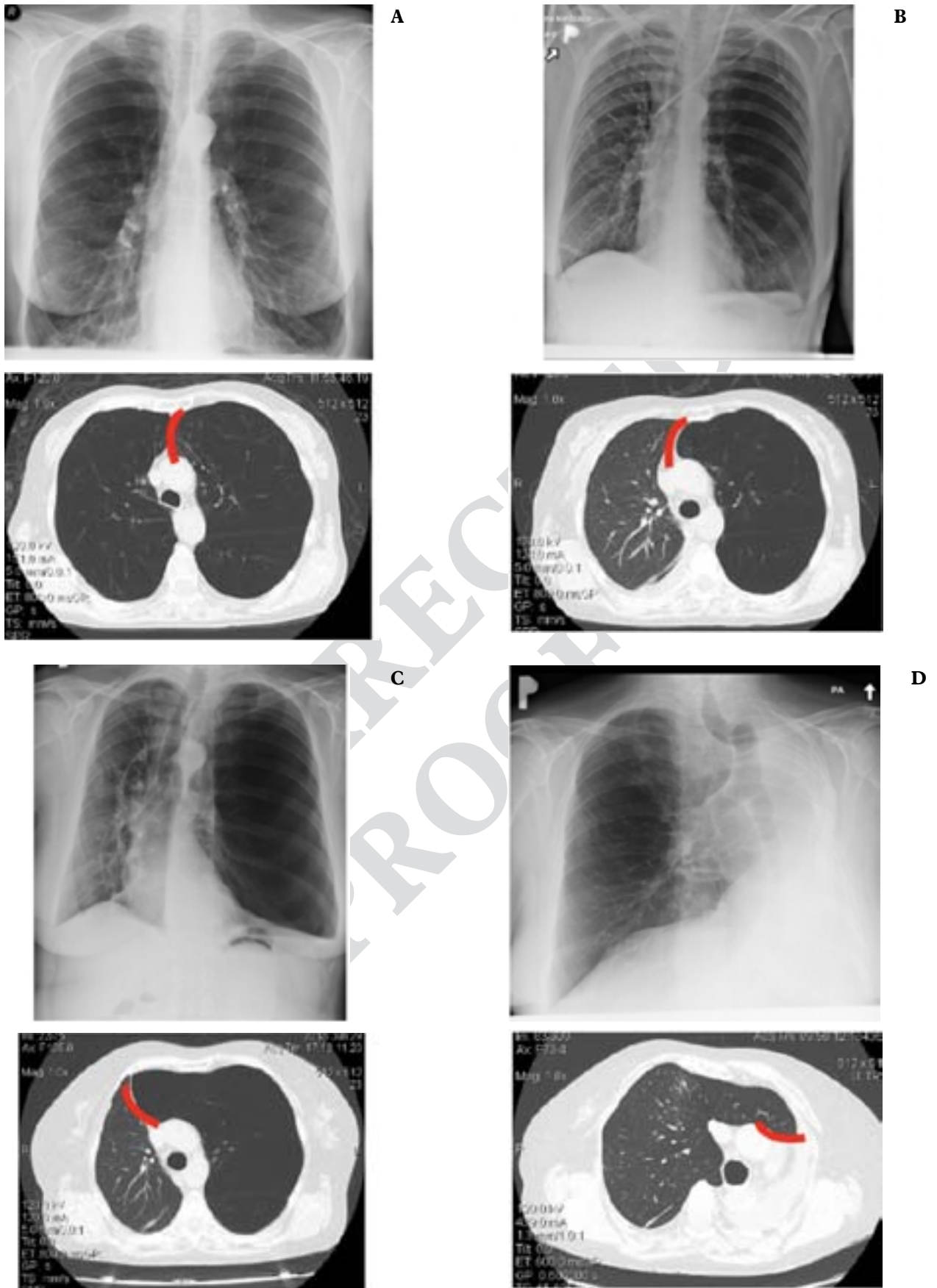
## 4. DISCUSSION

The first lung lobar transplantation in Poland was carried out in 1996 in Szczecin, while the first successful lung transplantation was performed in Zabrze in 1997.<sup>2</sup> Since then, LuTx has become a standard of care dedicated to carefully

**Table 1.  $FEV_1$ ,  $FEV_1/FVC$  and 6MWT results.**

Date	$FEV_1$ , %	$FEV_1$ and FVC, %	6MWT, m
Before SLuTx (February 2, 2011)	17.1	46.5	147
After SLuTx (January 10, 2012)	71	88	310
Before pneumonectomy (April 19, 2018)	45	85	420
After pneumonectomy – (August 31, 2018)	74	95	360
September 12, 2019	63	81	ND

Comments: ND – not done.



**Figure.** X-ray and CT scans of the patient: Before SLuTx (A); after SLuTx (B); before pneumonectomy (C), after pneumonectomy (D).

**Table 2. Clinically relevant information about reviewed cases.**

Author (Year)	Cause of SLuTx	Time between SLuTx and symptoms	Complications in the native lung	Symptoms	Treatment
Kapelanski et al. (1996) <sup>10</sup>	Emphysema	3 years	Emphysema	Dyspnea Exercise intolerance	Pneumonectomy
Speziali et al. (1997) <sup>11</sup>	Emphysema	1 day	Hyperinflation	–	Middle and lower lobectomy
Samano et al. (2010) <sup>12</sup>	Emphysema	5 days	Hyperinflation Mediastinal shift	–	Lung volume reduction surgery
Samano et al. (2010) <sup>12</sup>	Emphysema	3 years	Hyperinflation	Dyspnea	Lower lobectomy
Liu et al. (2014) <sup>13</sup>	Pulmonary lymphangioliomyomatosis	3 years	Mediastinal shift	Dyspnea	Pneumonectomy
Abi Jaoude et al. (2016) <sup>14</sup>	Idiopathic pulmonary fibrosis	–	Aspergilloma	Persistent cough	Pneumonectomy
Abi Jaoude et al. (2016) <sup>14</sup>	Alpha-1-antitrypsin deficiency	–	Hyperinflation Mediastinal shift	Hemoptysis	Pneumonectomy
Madan et al. (2018) <sup>15</sup>	Idiopathic pulmonary fibrosis	5 years	Idiopathic pulmonary fibrosis Aspergilloma infection	Persistent cough Hemoptysis	Right lower lobectomy
Yoshizaki et al. (2020) <sup>16</sup>	Pulmonary lymphangioliomyomatosis	Several months	Hyperinflation Aspergillus infection	Hemoptysis Dyspnea	Bronchial artery embolization

selected patients with strict qualification process. The expected 2-year survival rate without the transplant should be lower than 50%, where the probability of surviving more than 90 days after the surgery ought to be greater than 80%. In addition, a patient should have an adequate psychological profile with support from relatives.<sup>3</sup>

Firstly, SLuTx was performed in patients with pulmonary fibrosis. Currently, this method is successful in patients with COPD, Eisenmenger's syndrome, primary pulmonary hypertension and alpha-1-antitrypsin deficiency.<sup>4</sup> In COPD, according to the Global Initiative for Chronic Obstructive Pulmonary Disease (GOLD), there are four stages of the disease (based on the airflow limitation): GOLD 1 (mild)  $FEV_1 > 80\%$ ; GOLD 2 (moderate)  $FEV_1 50\%–79\%$ ; GOLD 3 (severe)  $FEV_1 30\%–49\%$ ; GOLD 4 (very severe)  $FEV_1 < 30\%$ , respectively.<sup>5</sup> Patients in fourth stage of the disease may qualify for transplantation. COPD is the most common indication for LuTx (40% of all performed transplantations).<sup>6</sup> Chronic cough and progressive shortness of breath are typical symptoms of the disease.<sup>7</sup> The BODE index ranges from 0 to 10. Higher score indicates higher risk of death. According to the International Society for Heart and Lung Transplantation (ISHLT), there are many contraindications for the procedure: event of malignancy in the past 2 years, major organ dysfunction, unstable psychological profile of the patient, addiction, age of over 65 years and more.<sup>8</sup>

In the presented case, after SLuTx, the patient developed NLH and a mediastinal shift. NLH is a known complication which causes loss of pulmonary function due to compression of transplanted lung (as seen in lowered results in spirometry).<sup>9</sup> To prevent hyperinflation, lung volume reduction surgery might be performed after SLuTx. In this patient, as a result of advanced compression with narrowed right segmental bronchi, a native left lung pneumonectomy had to be performed (Figure). After the lung resection,

spirometry tests showed improvement. The decrease in 6MWT was caused by femoral bone fissure.

We have reviewed 9 cases from world literature that present complications in the native lung after SLuTx (Table 2). Symptoms after the primary procedure appeared from days to years. The most common complication in reviewed articles was hyperinflation (56% of the cases)<sup>11, 12, 14, 16</sup> of the native lung but fungal infection (aspergillosis) was observed often as well (33%).<sup>14–16</sup> Symptoms were similar to the case we present: dyspnea, exercise intolerance and cough. Risk factors for hyperinflation are severe COPD and prolonged mechanical ventilation.<sup>12</sup> To remove the compression of transplanted organ, lung volume reduction surgery is performed, native lung pneumonectomy is not frequently reported.<sup>13</sup>

In analysis performed by King et al. out of 180 patients who underwent SLuTx, 25 developed complications in the native lung. In this group, 11 patients required native lung pneumonectomy. Indications for lung resection consisted of aspergilloma, bronchopleural fistula, non-small-cell lung cancer and infection.<sup>17</sup>

In another analysis by Reece et al. 206 SLuTx were completed. Among those patients, 10 developed significant compression of graft and required lung volume reduction surgery. The mean time from lung transplantation to lung volume reduction was 50 months and all patients presented gradual decrease in  $FEV_1$  during that time.<sup>18</sup>

In study performed by Arango et al. 293 patients underwent lung transplantation. Among them, 82 patients suffered from end stage COPD. Postoperatively NLH was developed in 3 patients. Consequently, they underwent lung volume reduction surgery. Condition of those patients were improved, as measured by  $FEV_1$  from 31% to 65%.<sup>19</sup>

## 5. CONCLUSIONS

- (1) NLH is a gradually developing complication after SLuTx which might lead to dangerous graft compression causing loss of respiratory function.
- (2) To reduce the compression, lung volume reduction surgery usually is performed. In rare cases, only pneumonectomy would improve patient's condition.

### Conflict of interests

None declared.

### Funding

None declared.

### References

- 1 Lahzami S, Aubert JD. Lung transplantation for COPD – evidence-based? *Swiss Med Wkly*. 2009;139(1–2):4–8.
- 2 Czerwiński J, Czapiewski W, Danielewska E, et al. Evolution of organ transplantation in Poland 1966 to 2014: Dates and numbers. *Transplant Proc*. 2016;48(5):1423–1426. <https://doi.org/10.1016/j.transproceed.2016.01.042>.
- 3 Latos M, Nęcki M, Pawlak D, et al. Outcome of lung transplantation as a treatment of patients with chronic obstructive pulmonary disease: A single-center study. *Transplant Proc*. 2020;52(7):2118–2122. <https://doi.org/10.1016/j.transproceed.2020.02.107>.
- 4 Trulock EP. Lung transplantation. *Annu Rev Med*. 1992;43:1–8. <https://doi.org/10.1146/annurev.me.43.020192.000245>.
- 5 Mirza S, Clay RD, Koslow MA, Scanlon PD. COPD Guidelines: A Review of the 2018 GOLD Report. *Mayo Clin Proc*. 2018;93(10):1488–1502. <https://doi.org/10.1016/j.mayocp.2018.05.026>.
- 6 Weill D. Lung transplantation: Indications and contraindications. *J Thorac Dis*. 2018;10(7):4574–4587. doi: 10.21037/jtd.2018.06.141.
- 7 Kuzmenko N, Iaremenko O, Dobrianskiy D, Ilnytskiy R, Gumeniuk G. The efficacy and safety of inhaled acetylcysteine in comparison with oral acetylcysteine in chronic obstructive pulmonary disease: A randomized single-center study. *Pol Ann Med*. 2020;27(2):108–114. <https://doi.org/10.29089/2020.20.00112>.
- 8 Inci I. Lung transplantation for emphysema. *Ann Transl Med*. 2020;8(21):1473. <https://doi.org/10.21037/atm-20-805>.
- 9 Wilson H, Carby M, Beddow E. Lung volume reduction surgery for native lung hyperinflation following single-lung transplantation for emphysema: Which patients? *Eur J Cardiothorac Surg*. 2012;42(3):410–413. <https://doi.org/10.1093/ejcts/ezs086>.
- 10 Kapelanski DP, Anderson MB, Kriett JM, et al. Volume reduction of the native lung after single-lung transplantation for emphysema. *J Thorac Cardiovasc Surg*. 1996;111(4):898–899. [https://doi.org/10.1016/S0022-5223\(96\)70354-9](https://doi.org/10.1016/S0022-5223(96)70354-9).
- 11 Speziali G, McDougall JC, Midthun DE, et al. Native lung complications after single lung transplantation for emphysema. *Transpl Int*. 1997;10(2):113–115. <https://doi.org/10.1111/j.1432-2277.1997.tb00551.x>.
- 12 Samano MN, Junqueira JJ, Teixeira RH, et al. Lung hyperinflation after single lung transplantation to treat emphysema. *J Bras Pneumol*. 2010;36(2):265–269. <https://doi.org/10.1590/S1806-37132010000200017>.
- 13 Liu F, Ruan Z, Wang S, Lin Q. Right native lung pneumonectomy due to over inflation three years after left single lung transplantation for pulmonary lymphangioleiomyomatosis. *Ann Thorac Cardiovasc Surg*. 2014;20(1):70–73. <https://doi.org/10.5761/atcs.cr.13-00133>.
- 14 Abi Jaoude W, Tiu B, Strieter N, Maloney JD. Thoracoscopic native lung pneumonectomy after single lung transplant: initial experience with 2 cases. *Eur J Cardiothorac Surg*. 2016;49(1):352–354. <https://doi.org/10.1093/ejcts/ezv075>.
- 15 Madan N, Abdelrazek H, Patil PD, et al. Development of squamous cell carcinoma after pulmonary aspergillosis in the native lung of a lung transplant recipient: A case report. *Transplant Proc*. 2018;50(10):4080–4084. <https://doi.org/10.1016/j.transproceed.2018.07.034>.
- 16 Yoshizaki A, Yamamoto M, Hirabayashi A, et al. Fatal Hemoptysis Due to Endobronchial Aspergilloma in the Hyperinflated Native Lung after Single-Lung Transplantation for Lymphangioleiomyomatosis: A Case Report. *Kobe J Med Sci*. 2020;65(4):114–117. <https://www.ncbi.nlm.nih.gov/pmc/articles/PMC7447097/>.
- 17 King CS, Khandhar S, Burton N, et al. Native lung complications in single-lung transplant recipients and the role of pneumonectomy. *J Heart Lung Transplant*. 2009;28(8):851–856. <https://doi.org/10.1016/j.healun.2009.04.023>.
- 18 Reece TB, Mitchell JD, Zamora MR, et al. Native lung volume reduction surgery relieves functional graft compression after single-lung transplantation for chronic obstructive pulmonary disease. *J Thorac Cardiovasc Surg*. 2008;135(4):931–937. <https://doi.org/10.1016/j.jtcvs.2007.10.069>.
- 19 Arango E, Espinosa D, Illana J, et al. Lung volume reduction surgery after lung transplantation for emphysema-chronic obstructive pulmonary disease. *Transplant Proc*. 2012;44(7):2115–2117. <https://doi.org/10.1016/j.transproceed.2012.07.068>.