



Review paper

Percutaneous epidural adhesiolysis – treatment method for drug-resistant back pain

**Andrzej Zawadzki¹, Marta Zawadzka², Mateusz Maciej Węciewicz³ ,
Wojciech Skrobot⁴ , Wojciech Kloc^{3,5}**

¹ *Independent Researcher*

² *Department of Developmental Neurology, Chair of Neurology, Medical University of Gdańsk, Poland*

³ *Department of Neurosurgery, Copernicus Hospital Gdansk, Poland*

⁴ *Department of Functional Diagnostics and Kinesiology, Gdansk University of Physical Education and Sport, Gdańsk, Poland*

⁵ *Department of Psychology and Social Sciences in Medicine and Public Health, Faculty of Health Sciences, Collegium Medicum, University of Warmia and Mazury in Olsztyn, Poland*

ARTICLE INFO

Article history

Received: 12 May 2021

Accepted: 29 July 2021

Available: 27 September 2021

Keywords

Back pain

Percutaneous epidural adhesiolysis

Post-surgery syndrome

Doi

<https://doi.org/10.29089/2021.21.00184>

User license

This work is licensed under a Creative Commons Attribution – NonCommercial – NoDerivatives 4.0 International License.



ABSTRACT

Introduction: Percutaneous epidural adhesiolysis (epidural decompressive neuroplasty, percutaneous epidural neuroplasty) is treatment method for drug-resistant back pain, including post-surgery syndrome, sciatica or spinal canal stenosis.

Aim: To describe the method and outcomes of epidural adhesiolysis.

Material and methods: The review of the literature on the topic of epidural adhesiolysis.

Results and discussion: This procedure is usually performed in the lumbo-sacral part of the spine, although it can be also done in the cervical or thoracic parts as well. Its purpose is to administer anesthetic drugs, steroids, saline solution or hyaluronidase into the epidural space via one of the three approaches: caudal, interlaminar and transforaminal. The efficacy of epidural adhesiolysis was proven in numerous randomized controlled trials.

Conclusions: The efficacy of epidural adhesiolysis was proven in numerous randomized controlled trials. When performed by an experienced physician, epidural adhesiolysis is a safe and effective method with infrequent adverse events.

1. INTRODUCTION

Treatment of low back pain (LBP) is a clinical challenge. The incidence of LBP increases as the population ages. Chronic pain is a cause of suffering, disability and significant costs (both financial and social).^{1–3} Intervertebral disc herniation, spinal canal stenosis and spondylolisthesis are the most common indications for spine surgery. However there are many more causes of chronic back pain e.g. lumbo-sacral pathologies, ‘black disk,’ degenerative diseases of the joints or ligaments, pseudoarthrosis, neuropathic pain, post-traumatic and post-operative epidural scars. It is noteworthy that despite the available diagnostic techniques, a significant group of patients experience lumbar pain of unknown origin. Epidural scars are gaining increasing attention as they are a potentially treatable cause of spinal pain.⁴

Percutaneous epidural adhesiolysis (epidural decompressive neuroplasty, percutaneous epidural neuroplasty, epidural neurolysis, Racz neurolysis) is a minimally invasive method to remove epidural adhesions that directly (or indirectly) lead to compression, edema, inflammation or reduced perfusion of nerve roots.^{2,4} There are two therapeutic goals of the epidural adhesiolysis: to provide analgesia and to prevent adhesion recurrence. This procedure is performed using a dedicated catheter (and thin, blunt-ended wire inside of it) or a balloon (similar to angioplasty balloon catheter) to mechanically separate adhesions and to administer drugs (e.g. anesthetics, steroids, saline solution or hyaluronidase) into the epidural space near the affected nerve root.^{5–8}

Technique of the epidural adhesiolysis was introduced into clinical practice by Gabor Racz in 1989. It comprised of 3-day protocol that involved simultaneous epidurography, adhesiolysis and epidural injection of bupivacaine, triamcinolone, hyaluronidase and 10% saline solution via the Racz catheter (all on day 1) (Figure 1) and repeated doses of bupivacaine and 10% saline on days 2 and 3.^{9,10} According to Racz, the mechanical manipulation using the cannula and the slow administration of the saline solution releases the dura from adhesions. Racz et al. claim that the procedure was the first method to combine so many actions: diagnostics, mechanical and chemical adhesiolysis and local action of the administered drugs.¹⁰

Manchikanti et al. modified the Racz procedure by shortening it one day and substituting drugs (lidocaine instead of bupivacaine, methylprednisolone instead of triamcinolone).¹¹ Several researchers report that this modified technique is equally effective, though cheaper and safer




Figure 1. Different types of Racz catheter.¹²

than the original Racz protocol.^{8,13,14} In the 1990's adhesiolysis evolved further, with the development of endoscopic techniques allowing for more precise visualization of the epidural space and its contents.^{15,16} In recent times, methods of epidural neurolysis were developed. Raffaelli et al. described neuroplasty using a Fogarty balloon to remove fibrosis. Those methods were furtherly improved as commercial products were introduced to the market.^{17–19}

2. AIM

Aim of the paper was to describe the procedure based on the data found in the literature and authors' own experience. Another objective was to review the literature on epidural adhesiolysis to compare the efficacy of the method and standard minimally invasive procedures in spinal disorders.

3. MATERIAL AND METHODS

Databases and indexes such as: Medline, PubMed Central, Google Scholar and Scopus were used during the literature review. Search was conducted with phrases: ‘percutaneous epidural adhesiolysis,’ ‘epidural decompressive neuroplasty,’ ‘percutaneous epidural neuroplasty,’ ‘epidural neurolysis,’ ‘Racz neurolysis’ to identify papers. Duplicates were deleted from the database. Papers were reviewed by two independent reviewers, relevant publications were included. After the first review there were 53 papers included. After the second analysis 14 papers were rejected due to lack of relevant data or data duplication. In total, 39 publications were included in this review.

4. RESULTS AND DISCUSSION

4.1. Procedure

Epidural adhesiolysis is usually performed in the lumbo-sacral part of the spine, although it can also be done in cervical or thoracic spine. This procedure is typically performed in the operating room and in some centers patients are sedated and local anesthetic is administered into skin near the puncture site.^{9,20}

The first step of this procedure is to reach the epidural space via one of the three approaches (caudal, interlaminar and transforaminal) (Figure 2).¹³ In order to better assess the approach to the epidural space and to avoid adverse events, one can use. The assist of fluoroscopic imaging for guidance should be implemented in order to confirm positioning of the catheter in the epidural space and to avoid adverse events.²⁰

Caudal approach involves using the sacral hiatus as the access to the epidural space. The sacral hiatus is easy to find thanks to the characteristic anatomy of the sacrum, including the sacral horns. Imaging is possible but not required when using this approach. After crossing the sacrococcygeal

ligament, the needle is introduced into the sacral canal and enters the epidural space. Using the interlaminar approach, the needle is introduced via the interspinous ligament of the spine, between the spinous processes, so that the needle is between the ligamentum flavum and the dura. When using this approach, imaging also is not required. In order to assess the location of the needle, one can use the so-called ‘loss of resistance method’ or the ‘hanging droplet method.’^{21–23}

Transforaminal approach involves introducing the needle into the epidural space at the level of the affected nerve root via posterolateral approach through Kambin’s triangle aiming at the intervertebral foramen (the use of intraoperative fluoroscopy is required for safety).²⁴ After reaching the epidural space, contrast is injected and the enhancement around the nerve root should be visualized. Then a mechanical removal of adhesions and fibrotic tissues is performed with a catheter or inflatable balloon followed by chemical adhesiolysis.

The method described in 2001 by Manchikanti et al. involved mechanical adhesiolysis using the Racz catheter and injection of 5 mL of 1% lidocaine and 6 mg of betamethasone, a 10–15 minute break and two doses (3 mL) of 10% saline solution.²⁵ Other modifications of the Racz method were subsequently published. In 2006 Veihelmann et al. administered 9 mL of ropivacaine (2 mg) and 1 mL of triamcinolone (40 mg) in slow bolus (>5 minutes), a 30 minute break and 10 mL of 10% NaCl in a 30-minute infusion.²⁶ In 2018 Akbas et al. compared the effectiveness of adhesiolysis depending on the approach (caudal, S1 foraminal, and L5–S1 transforaminal), they administered 1500 IU of hyaluronidase and 80 mg of methylprednisolone mixed with 10 mL of 10% NaCl. The effectiveness was the same regardless of the approach used.²⁷

When it comes to the choice of steroids, Racz et al. recommended using triamcinolone.¹⁰ However, other authors reported using dexamethasone or methylprednisolone due to longer duration of action and less tissue irritation.^{11,20} Betamethasone is also considered less irritating to the tissues and the literature emphasizes its good anti-inflammatory effect, fast onset of action and the fact that it dissolves in solutions. The local anesthetics of choice are bupivacaine, ropivacaine and lidocaine. The chemical adhesiolysis is performed using hyaluronidase and saline solution (either 0.9% or 10%). According to some authors, the hypertonic 10% saline solution has local anesthetic activity and reduces cellular edema.¹³ A recent study by Choi et al. demonstrated that after a 6-month follow-up the hypertonic 5% saline solution is just as effective as 10% saline solution and suggesting that this is an alternative in epidural adhesiolysis of the lumbar spine.²⁸

Balloon neuroplasty can be performed via either of three described approaches. After insertion at the desired level or foramen the balloon filled with a contrast agent is inflated. Generated pressure causes mechanical removal of adhesions around the dura. Free flow of the contrast agent in the epidural space confirms that adhesions were successfully removed. After mechanical adhesiolysis local anesthetics and/or steroids are injected.^{17–19}

Endoscopic epiduroscopy is a method approved for the visualization of the epidural space and allows administra-

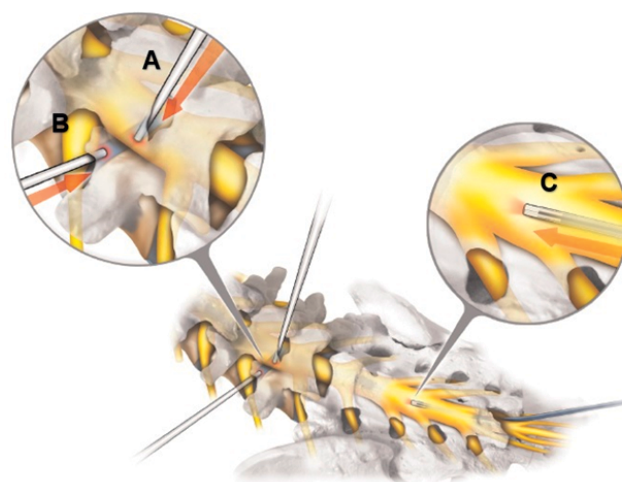


Figure 2. Various approaches for epidural adhesiolysis: (A) interlaminar approach; (B) transforaminal approach; (C) caudal approach. Modified from Kim DH, Abdi S, Schütze G, eds.²⁹

tion of drugs into the epidural space. The undisputed advantage of this method is the possibility to visualize changes in the epidural space and to potentially document the cause of the symptoms.³⁰

4.2. Indications

Epidural adhesiolysis is a treatment method for drug-resistant spinal pain syndromes, including post-operative pain syndromes, sciatica or spinal canal stenosis.^{19,26,31–34} Indications for epidural adhesiolysis include failed back surgery syndrome and post-laminectomy syndrome.^{2,4,35} The literature about epidural adhesiolysis in lumbo-sacral spinal pain indicates that this method is effective in the short- and long-term.^{5–7,10,30–34,36,37} There is also limited evidence on percutaneous neuroplasty in cervical spine stenosis.^{38,39}

4.3. Efficacy

The efficacy of epidural adhesiolysis was proven in numerous randomized controlled trials.

In their systematic review from 2016, Helm et al. examined the effectiveness of percutaneous and endoscopic adhesiolysis in the treatment of chronic lumbo-sacral pain radiating to the lower extremity. They included 10 articles (7 RCTs and 3 observational) in their meta-analysis that concluded that there is strong evidence that percutaneous adhesiolysis is effective in the treatment of chronic, refractory pain of the lower back and lower extremity (level I evidence).³⁰ The majority of the randomized controlled trials (RCTs) presented in the literature compared patients with epidural adhesiolysis with those who had an epidural block in various spinal disorders and provide evidence for effectiveness of the method. Improvement of patients’ status was noted twice as often in groups treated with adhesiolysis when compared either to placebo or epidural steroid injections.^{17,30,36,37} Veihelmann et al. compared the effectiveness of adhesiolysis and physical therapy showing superiority of adhesiolysis up to 12 months after the procedure.²⁶

Manchikanti et al. analyzed literature from 1996–2019 regarding epidural adhesiolysis in the treatment of chronic central lumbar spinal stenosis. Into their meta-analysis they included 2 RCTs, 4 observational studies and 5 studies for single arm meta-analysis and reported level II evidence for the effectiveness of both short- (≤ 6 months) and long-term (> 6 months) treatment.³⁷

Amirdelfan et al. analyzed the effectiveness of various methods of treating post-surgery syndrome, including pharmacotherapy, re-operation, spinal cord stimulation, rehabilitation and interventional procedures. The authors reported that active exercise, some interventional procedures including adhesiolysis and spinal cord stimulation are supported by quality evidence in the literature. They also pointed out that percutaneous adhesiolysis is better than endoscopic. At the same time, the authors emphasize that there are very few well-designed studies about the use of drugs in the epidural space to treat post-surgery syndrome and the existing data is sometimes conflicting. In their literature search, the authors found 3 level I studies, 11 level II studies, 2 level III studies and 10 systematic reviews. One of the I studies includes epidural adhesiolysis in the treatment group.⁴⁰ In that particular study, He Chun-jing et al. included 92 patients and divided them into 2 groups: those who were administered 10 mg of dexamethasone into the anterior epidural space and those who had epidural adhesiolysis. After 1 and 6 months of follow-up, significantly lower pain (Visual Analog Scale) was reported by the patients who had adhesiolysis. In addition, half of the patients treated using adhesiolysis and only 5.26% of those from the control group considered their treatment as good or excellent.⁴¹

Recently Manchikanti et al. published another meta-analysis in which they assessed the effectiveness of percutaneous adhesiolysis in the treatment of chronic low back and lower extremity pain in post-surgery syndrome. They searched for studies published in 1966–2019 and 10 (6 randomized controlled trials and 4 non-randomized). Of the 6 RCTs, 2 were high-quality and demonstrated significant improvement after adhesiolysis: approximately 70% of the patients reported improved functioning and more than 50% reported pain relief. The rest of the RCTs as well as the observational studies also report effectiveness of epidural adhesiolysis. Depending on the study, the patients were followed-up 6 weeks to 2 years, demonstrating short- and long-term effectiveness of adhesiolysis in managing chronic low back and lower extremity pain in post-surgery syndrome (level I evidence).⁴² There are also some additional reports of the effectiveness of adhesiolysis in other pathologies of the lumbar and cervical spine.^{13,39}

4.4. Controversies

In the literature epidural adhesiolysis is described as the effective method of relieving the pain in conditions that are difficult to address surgically i.e. post-laminectomy syndrome or other chronic spinal diseases. The difficulty in assessing postoperative outcomes is difficult because of the subjective nature of symptoms that the patient feels. The problem in previously described data is also a potential se-

lection bias, especially in spinal stenosis cases. It remains unclear whether patients qualified for epidural adhesiolysis were not selected for surgical treatment (due to mild symptoms or comorbidities) or they had a chance to choose surgery or adhesiolysis freely. Moreover, the degree of spinal stenosis was not described with any available scale.¹⁹

Moreover, it remains controversial that there are not many scientists that actively publish data on the topic. Most of the publications come from Manchikanti et al. and almost all of the data included in meta-analyses come from their scientific center. Also, the data is published by a limited number of journals including the Pain Physician Journal, which is the official journal of the American Society of Interventional Pain Physicians. Controversial fact is that Manchikanti is the Chairman of the Board and Chief Executive Officer of the organization.

Summing up, the data presented in the literature was not yet reproduced to the scale that allows unbiased conformation of their effectiveness. Authors, however, noted that in selected cases (including FBSS and LBP that cannot be efficiently treated with rehabilitation or surgery) those methods provide pain relief and can be safely repeated.

4.5. Adverse events

Adverse events during or after the adhesiolysis procedure are rare and usually benign. They can be due to the adverse reactions to the administered drugs or the mechanical manipulation inside the epidural space.²¹ Among the serious adverse events are puncture of the dura or arachnoid mater, administration of drug/s into the subdural or arachnoid space, spinal cord compression, infection, hemorrhage, damage to the cannula.^{13,20} The concentrated 10% saline solution might trigger arrhythmias or sphincter dysfunction. Steroids administered into the epidural space can theoretically cause any of their numerous adverse reactions, including immunosuppression.¹³ If fluoroscopic imaging was performed during the procedure, the patient is also at risk of adverse reactions to the contrast medium.

6. CONCLUSIONS

Epidural adhesiolysis is a treatment method for drug-resistant spinal pain syndromes, including post-surgery syndrome, sciatica or spinal canal stenosis. It is a typical day surgery procedure that can be safely and repeatedly performed in patients with comorbidities. Treatment with epidural adhesiolysis results with improvement of pain in short-term observation that improves the quality of life of patients with debilitating spinal diseases.

Conflict of interest

None declared.

Funding

None declared.

References

- 1 Manchikanti L, Kosanovic R, Pampati V, Kaye AD. Declining utilization patterns of percutaneous adhesiolysis procedures in the fee-for-service (FFS) Medicare population. *Pain Physician*. 2021;24(1):17–29.
- 2 Brito-Garcia N, Garcia-Perez L, Kovacs FM, et al. Efficacy, effectiveness, safety, and cost-effectiveness of epidural adhesiolysis for treating failed back surgery syndrome. a systematic review. *Pain Med*. 2019;20(4):692–706. <https://doi.org/10.1093/pm/pny233>.
- 3 Tymecka-Woszczerowicz A, Wrona W, Kowalski PM, Hermanowski T. Indirect costs of back pain – Review. *Pol Ann Med*. 2015;22(2):143–148. <https://doi.org/10.1016/j.poamed.2015.07.003>.
- 4 Helm S, Knezevic NN. A review of the role of epidural percutaneous neuroplasty. *Pain Manag*. 2019;9(1):53–62. <https://doi.org/10.2217/pmt-2018-0042>.
- 5 Chopra P, Smith HS, Deer TR, Bowman RC. Role of adhesiolysis in the management of chronic spinal pain: a systematic review of effectiveness and complications. *Pain Physician*. 2005;8(1):87–100.
- 6 Trescot AM, Chopra P, Abdi S, Datta S, Schultz DM. Systematic review of effectiveness and complications of adhesiolysis in the management of chronic spinal pain: an update. *Pain Physician*. 2007;10(1):129–146.
- 7 Epter RS, Helm S 2nd, Hayek SM, Benyamin RM, Smith HS, Abdi S. Systematic review of percutaneous adhesiolysis and management of chronic low back pain in post lumbar surgery syndrome. *Pain Physician*. 2009;12(2):361–378.
- 8 Manchikanti L, Pampati V, Cash KA. Protocol for evaluation of the comparative effectiveness of percutaneous adhesiolysis and caudal epidural steroid injections in low back and/or lower extremity pain without post surgery syndrome or spinal stenosis. *Pain Physician*. 2010;13(2):E91–E110.
- 9 Racz GB, Holubec JT. Lysis of adhesions in the epidural space. In: Racz GB, ed. *Techniques of Neurolysis*. Boston, MA: Springer US; 1989:57–72. https://doi.org/10.1007/978-1-4899-6721-3_6.
- 10 Racz GB, Heavner JE, Raj P. Percutaneous epidural neuroplasty: Prospective one-year follow-up. *Pain Digest*. 1999;9:97–102.
- 11 Manchikanti L, Pampati V, Fellows B, et al. Effectiveness of percutaneous adhesiolysis with hypertonic saline neurolysis in refractory spinal stenosis. *Pain Physician*. 2001;4(4):366–373.
- 12 Shin DA. Percutaneous epidural neuroplasty. In: Kim J-S, Lee JH, Ahn Y, eds. *Endoscopic Procedures on the Spine*. Singapore: Springer Singapore; 2020:353–359. https://doi.org/10.1007/978-981-10-3905-8_28.
- 13 Manchikanti L, Bakhit CE. Percutaneous lysis of epidural adhesions. *Pain Physician*. 2000;3(1):46–64.
- 14 Karnezis IA. Minimally invasive therapeutic interventional procedures in the spine: an evidence-based review. *Surg Technol Int*. 2008;17:259–268.
- 15 Manchikanti L, Saini B, Singh V. Spinal endoscopy and lysis of epidural adhesions in the management of chronic low back pain. *Pain Physician*. 2001;4(3):240–265.
- 16 Hayek SM, Helm S, Benyamin RM, Singh V, Bryce DA, Smith HS. Effectiveness of spinal endoscopic adhesiolysis in post lumbar surgery syndrome: a systematic review. *Pain Physician*. 2009;12(2):419–435.
- 17 Shin J-W, Kim S-H, Choi W-J, et al. Effects of Transforaminal Balloon Treatment in Patients with Lumbar Foraminal Stenosis: A Randomized, Controlled, Double-Blind Trial. <https://www.painphysicianjournal.com>. Accessed March 15, 2021.
- 18 Rapčan R, Kočan L, Mláka J, et al. A randomized, multicenter, double-blind, parallel pilot study assessing the effect of mechanical adhesiolysis vs adhesiolysis with corticosteroid and hyaluronidase administration into the epidural space during epiduroscopy. *Pain Med (United States)*. 2018;19(7):1436–1444. <https://doi.org/10.1093/pm/pnx328>.
- 19 Karm M-H, Choi S-S, Kim D-H, et al. Percutaneous Epidural Adhesiolysis Using Inflatable Balloon Catheter and Balloon-less Catheter in Central Lumbar Spinal Stenosis with Neurogenic Claudication: A Randomized Controlled Trial. *Pain Physician*. 2018;21(6):593–606.
- 20 Anderson SR, Racz GB, Heavner J. Evolution of epidural lysis of adhesions. *Pain Physician*. 2000;3(3):262–270.
- 21 Castillo M, Ortiz O. Handbook of Diagnostic and Therapeutic Spine Procedures. *Acad Radiol*. 2002;9(12):1437. [https://doi.org/10.1016/s1076-6332\(03\)80675-x](https://doi.org/10.1016/s1076-6332(03)80675-x).
- 22 Hasenbring M, Kraemer R, Taub E, Theodoridis T, Wilke HJ. Intervertebral Disk Diseases. Kraemer J, ed. *Causes, Diagnosis, Treat Prophyl*. 2009. doi:10.1055/b-002-59223
- 23 Kehr P. Theodoridis Theodoros and Krämer Jürgen (eds.): Spinal injection techniques. *Eur J Orthop Surg Traumatol*. 2010;20. <https://doi.org/10.1007/s00590-010-0621-9>.
- 24 Vad VB, Bhat AL, Lutz GE, Cammisa F. Transforaminal epidural steroid injections in lumbosacral radiculopathy: A prospective randomized study. *Spine (Phila Pa 1976)*. 2002;27(1):11–15. <https://doi.org/10.1097/00007632-200201010-00005>.
- 25 Manchikanti L, Pampati V, Sc M, et al. Role of One Day Epidural Adhesiolysis in Management of Chronic Low Back Pain: A Randomized Clinical Trial. *Pain Physician*. 4(2):153–166.
- 26 Veihelmann A, Devens C, Trouillier H, Birkenmaier C, Gerdesmeyer L, Refior HJ. Epidural neuroplasty versus physiotherapy to relieve pain in patients with sciatica: A prospective randomized blinded clinical trial. *J Orthop Sci*. 2006;11(4):365–369. <https://doi.org/10.1007/s00776-006-1032-y>.
- 27 Akbas M, Elawamy AR, Salem HH, Fouad AZ, Abbas NA, Dagistan G. Comparison of 3 Approaches to Percutaneous Epidural Adhesiolysis and Neuroplasty in Post Lumbar Surgery Syndrome. *Pain Physician*. 2018;21(5):E501–E508.
- 28 Choi EJ, Yoo YJ, Lee PB, Kim YC, Lee SC, Moon JY. A retrospective study to evaluate the effect of concentration of hypertonic saline on efficacy and safety of epidural adhesiolysis. *Anesth Analg*. 2017;124(6):2021–2029. <https://doi.org/10.1213/ANE.0000000000001925>.

- ²⁹ Kim DH, Abdi S, Schütze G, eds. Transforaminal and interlaminar approaches in epiduroscopy. In: *Epiduroscopy*. Stuttgart: Georg Thieme Verlag; 2017. <https://doi.org/10.1055/b-0037-145261>.
- ³⁰ Helm S 2nd, Racz GB, Gerdsmeyer L, et al. Percutaneous and Endoscopic Adhesiolysis in Managing Low Back and Lower Extremity Pain: A Systematic Review and Meta-analysis. *Pain Physician*. 2016;19(2):E245–82.
- ³¹ Manchikanti L, Singh V, Cash KA, Pampati V, Datta S. A comparative effectiveness evaluation of percutaneous adhesiolysis and epidural steroid injections in managing lumbar post surgery syndrome: a randomized, equivalence controlled trial. *Pain Physician*. 2009;12(6):E355–68.
- ³² Jamison DE, Hsu E, Cohen SP. Epidural adhesiolysis: an evidence-based review. *J Neurosurg Sci*. 2014;58(2):65–76.
- ³³ Gerdsmeyer L, Wagenpfeil S, Birkenmaier C, et al. Percutaneous epidural lysis of adhesions in chronic lumbar radicular pain: a randomized, double-blind, placebo-controlled trial. *Pain Physician*. 2013;16(3):185–196.
- ³⁴ Manchikanti L, Cash KA, McManus CD, Pampati V, Singh V, Benyamin R. The preliminary results of a comparative effectiveness evaluation of adhesiolysis and caudal epidural injections in managing chronic low back pain secondary to spinal stenosis: a randomized, equivalence controlled trial. *Pain Physician*. 2009;12(6):E341–354. <http://europepmc.org/abstract/MED/19935991>. Accessed: 04.04.2021.
- ³⁵ Oh Y, Shin DA, Kim DJ, et al. Effectiveness of and Factors Associated with Balloon Adhesiolysis in Patients with Lumbar Post-Laminectomy Syndrome: A Retrospective Study. *J Clin Med*. 2020;9(4):1144. <https://doi.org/10.3390/jcm9041144>.
- ³⁶ Manchikanti L, Rivera JJ, Pampati V, et al. One day lumbar epidural adhesiolysis and hypertonic saline neurolysis in treatment of chronic low back pain: a randomized, double-blind trial. *Pain Physician*. 2004;7(2):177–186.
- ³⁷ Manchikanti L, Knezevic NN, Sanapati MR, Boswell M V, Kaye AD, Hirsch JA. Effectiveness of Percutaneous Adhesiolysis in Managing Chronic Central Lumbar Spinal Stenosis: A Systematic Review and Meta-Analysis. *Pain Physician*. 2019;22(6):E523–E550.
- ³⁸ Park CH, Lee SH, Lee SC. Preliminary results of the clinical effectiveness of percutaneous adhesiolysis using a Racz catheter in the management of chronic pain due to cervical central stenosis. *Pain Physician*. 2013;16(4):353–358.
- ³⁹ Ji GY, Oh CH, Won KS, et al. Randomized Controlled Study of Percutaneous Epidural Neuroplasty Using Racz Catheter and Epidural Steroid Injection in Cervical Disc Disease. *Pain Physician*. 2016;19(2):39–48.
- ⁴⁰ Amirdelfan K, Webster L, Poree L, Sukul V, McRoberts P. Treatment Options for Failed Back Surgery Syndrome Patients with Refractory Chronic Pain: An Evidence Based Approach. *Spine (Phila Pa 1976)*. 2017;42:S41–S52. <https://doi.org/10.1097/BRS.0000000000002217>.
- ⁴¹ Chun-Jing H, Hao-Xiong N, Jia-Xiang N. A aplicação da lise percutânea de aderências epidurais em pacientes com síndrome pós- Laminectomia. *Acta Cir Bras*. 2012;27(4):357–362. <https://doi.org/10.1590/S0102-86502012000400013>
- ⁴² Manchikanti L, Knezevic NN, Sanapati SP, Sanapati MR, Kaye AD, Hirsch JA. Is Percutaneous Adhesiolysis Effective in Managing Chronic Low Back and Lower Extremity Pain in Post-surgery Syndrome: a Systematic Review and Meta-analysis. *Curr Pain Headache Rep*. 2020;24(6):1–19. <https://doi.org/10.1007/s11916-020-00862-y>.