

## Case report

# A cadaveric analysis of anatomical variations of the musculocutaneous nerve

*Ewa Toruńska, Mikołaj Jerzy Konopka, Jerzy Gielecki, Łukasz Klepacki*

*Department of Anatomy, School of Medicine, Collegium Medicum, University of Warmia and Mazury in Olsztyn, Poland*

### ARTICLE INFO

#### Article history

Received: May 7, 2022

Accepted: July 15, 2022

Available online: September 20, 2022

#### Keywords

Anatomical variation  
Musculocutaneous nerve  
Brachial plexus  
Brachialis

#### Doi

<https://doi.org/10.29089/paom/152136>

#### User license

This work is licensed under a  
Creative Commons Attribution –  
NonCommercial – NoDerivatives  
4.0 International License.



### ABSTRACT

**Introduction:** Variations within musculocutaneous nerve (MCN) are very frequent. Such cases should be discussed extensively to reduce the risk of iatrogenic damage during surgery.

**Aim:** In this paper, we wanted to present the unusual variability within the brachial plexus, which is the double MCN.

**Case study:** We present a case of accessory MCN found during the cadaveric dissection.

**Results and discussion:** In this paper we encountered two musculocutaneous nerves, of which MCN proper runs as standard innervating the biceps brachii and the coracobrachialis muscle, while MCN accessory extending distally from MCN proper and innervates the brachialis.

**Conclusions:** The case analysed by us is rare in the literature. Brachial plexus variations are very common and clinically important.

## 1. INTRODUCTION

During the routine preparation of the cadaver at the Department of Anatomy, School of Medicine, Collegium Medicum, University of Warmia and Mazury in Olsztyn, Poland, after visualization of the brachial plexus, attention was drawn to unusual variability within the musculocutaneous nerve (MCN) in the left upper limb. In this case, there are two separate MCNs. Such variability has only been observed in a few studies.<sup>1-4</sup>

The MCN is a mixed nerve. It comes from the lateral bundle of the brachial plexus within the axillary cavity (C5–C7). Moving from the axillary cavity, it pierces the coracobrachialis muscle, going between the biceps brachii and the brachialis. Within the neurovascular bundle, this nerve runs laterally from the axillary artery and the median nerve (MN), and forward from the radial and axillary nerves. Along its entire length, this nerve gives off motor and sensory branches: motor – to the coracobrachialis, biceps brachii and brachialis, sensory – branches supplying the skin of the lateral part of the forearm and hand. The final branch of this nerve is the lateral antebrachial cutaneous nerve, which pierces the fascia of the arm in the area of the ulnar flexion.<sup>5-8</sup>

The embryological basis for the formation of the MCN covers the 4th to 7th week of gestation. Between 49th and 50th day, the final orientation and structure of the brachial plexus is similar to that seen in adults. This period is significant for the formation of any variability.<sup>8-10</sup>

The double MCN is rarity. In the literature the most common cases presence accessory branch connecting the MCN with the MN.

## 2. AIM

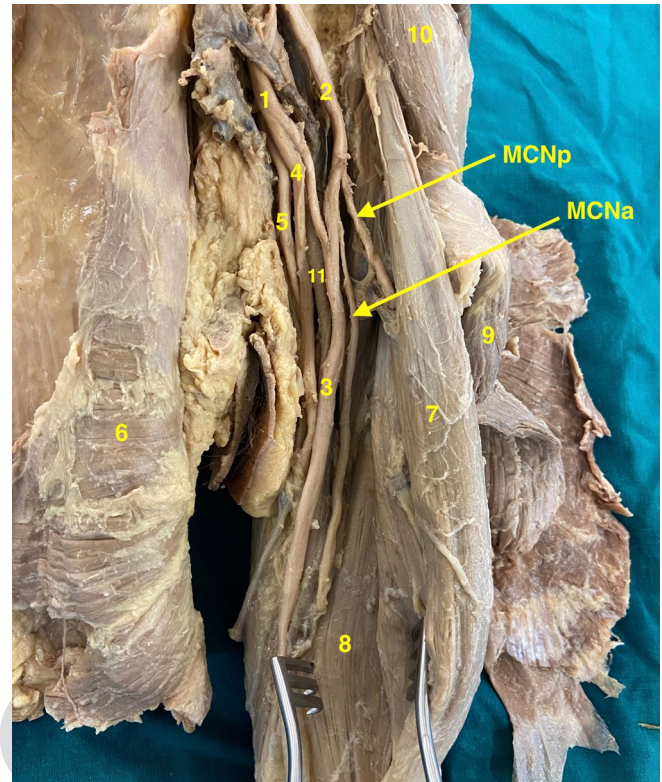
Our purpose is to present a very unusual variability – the double MCN. And also the analysis of the clinical consequences of such a case.

## 3. CASE STUDY

During the dissection at the Department of Anatomy, School of Medicine, Collegium Medicum, University of Warmia and Mazury in Olsztyn, Poland, a 50-year-old woman was diagnosed with double MCN. After careful analysis, the course of both MCNs in relation to each other and other anatomical structures was assessed. The extent of motor innervation was also specified (Figure).

## 4. RESULTS

MCN proper (MCNp) runs in a standard way, piercing the coracobrachialis muscle (length up to the muscle 5 cm) going between the biceps brachii and brachialis. MCN acces-



**Figure. Musculocutaneous nerve: MCNp – musculocutaneous nerve proper; MCNa – musculocutaneous nerve accessory; 1 – medial cord of brachial plexus; 2 – lateral cord of brachial plexus; 3 – median nerve; 4 – ulnar nerve; 5 – radial nerve 6 – serratus anterior; 7 – coracobrachialis; 8 – brachialis; 9 – biceps brachii; 10 – deltoid.**

sory (MCNa) departs from the lateral bundle 1.7 cm below the MCNp. Then MCNa goes to the brachialis (the length to the brachialis is 13.5 cm) and innervates it. MCNp innervates the coracobrachialis muscle and both heads of the biceps brachii.

## 5. DISCUSSION

There are many different classifications of variability of MCN. This is due to the fact that variations within this structure are very frequent. In a study carried out on 200 brachial plexuses, 53.5% of the samples taken showed anatomical variations.<sup>11</sup> However, in a study on 167 upper limbs, 2 cases of a double MCN were reported, which together account for 1.2% of all samples tested.<sup>3</sup>

One form of classification was proposed, among others, by Le Minor identifying 5 types of variation:

- (1) involves the lack of communication between the MCN nerve and the MN;
- (2) some of the MCN fibers connect to the MN;
- (3) the lateral root of the MN departs from the MCN;
- (4) all MCN fibers are bonded to the MN;
- (5) all MCN fibers are fully bonded to the MN along the entire length of this nerve.

Which means no proper MCN.<sup>12</sup> Another classification proposed by the authors in 2009 is the definition of 4 consecutive steps:

- (1) first step: 0 – no nerve, 1 i MCN present;
- (2) second step: A – MCN passes through the coracobrachialis muscle, B – does not pass through the coracobrachialis muscle;
- (3) third step: 0 – no connecting branches; 1 – one connecting branch, 2 – at least two connecting branches; 3 – MCN connects to MN; 4 – MCN distal beginning of the nerve;
- (4) fourth step: P – The branch connecting the MCN with the MN is before the puncture of the coracobrachialis muscle; D – The branch connecting the MCN with the MN is distal to the puncture of the coracobrachialis muscle; PD – Presence of the distal and proximal branches connecting the MCN to the MN.

The author, in case of the absence of MCN, took into account two options for the place of departure of the branches to coracobrachialis, biceps brachii and brachialis: 1 – the branches depart from the common trunk of the MN; 2 – branches depart from MN.<sup>13</sup>

This is an inaccurate classification taking into account the vast majority of variability, but it ignores the classification due to the number of MCN nerves with which we come into contact with our case.

Accurate knowledge of the course and variability of the position of the brachial plexus nerves and their branches is important in traumatology of the shoulder joint, during surgery, anesthesia, etc. It has been found that over 50% of all anatomical variations within the nervous system concern the brachial plexus.<sup>14,15</sup> Intra-bundle distance of each MCN branches is important in microsurgical procedures, which helps to avoid iatrogenic damage. On the other hand, an abnormal MCN lesion can lead to paralysis or loss of sensation in the skin of the lateral part of the forearm, the lateral withers of the thumb and the elbow area. Paralysis may involve the coracobrachialis, biceps brachii and brachialis muscles. The above damage may lead to impaired pronation and supination of the wrist and supination of the forearm.<sup>2,3,8,16–20</sup>

In our case, MCNp motor innervates the coracobrachialis muscle and both heads of the biceps brachii muscle. On the other hand, MCNa innervates the brachialis muscle.

In such a situation, with an isolated MCNp lesion, the function of the coracobrachialis and biceps brachii muscles will be impaired. In contrast, the function of the brachialis muscle should be preserved. This enables innervation with MCNa fibers. On the other hand, damage to an isolated MCNa can lead to the abolition or weakening of the function of the brachialis muscle.

Understanding of the variability within the brachial plexus and its branches can be critical in upper limb anesthesia. To block the nerves of the brachial plexus, it is necessary to distribute the drug around each of the nerves. In our case, due to the presence of additional MCNa, additional drug administration is necessary.<sup>18</sup>

## 6. CONCLUSION

- (1) Variations within the brachial plexus are encountered more often than the anatomically described course.
- (2) We have presented a situation that describes a rare double MCN.
- (3) Each different course of the brachial plexus nerves is important in performing microsurgical procedures and is very significant in the case of upper limb anesthesia.
- (4) The block of the brachial plexus, compared to the brachial anesthesia, allows for better pain control, less need for opioids and an improvement in the range of functions after the procedures.

### Conflict of interest

None declared.

### Funding

None declared.

### References

- <sup>1</sup> Pontell M, Scali F, Marshall E. A unique variation in the course of the musculocutaneous nerve. *Clin Anat.* 2011;24(8):968–970. <https://doi.org/10.1002/ca.21173>.
- <sup>2</sup> Abu-Hijleh MF. Three-headed biceps brachii muscle associated with duplicated musculocutaneous nerve. *Clin Anat.* 2005;18(5):376–379. <https://doi.org/10.1002/ca.20100>.
- <sup>3</sup> Claassen H, Schmitt O, Wree A, Schulze M. Variations in brachial plexus with respect to concomitant accompanying aberrant arm arteries. *Ann Anat.* 2016;208:40–48. <https://doi.org/10.1016/j.aanat.2016.07.007>.
- <sup>4</sup> Yamamoto M, Kojyo U, Yanagisawa N, et al. Morphology and relationships of the biceps brachii and brachialis with the musculocutaneous nerve. *Surg Radiol Anat.* 2018;40(3):303–311. <https://doi.org/10.1007/s00276-017-1919-7>.
- <sup>5</sup> Leinberry CF, Wehbé MA. Brachial plexus anatomy. *Hand Clin.* 2004;20(1):1–5. [https://doi.org/10.1016/s0749-0712\(03\)00088-x](https://doi.org/10.1016/s0749-0712(03)00088-x).
- <sup>6</sup> Hayashi M, Shionoya K, Hayashi S, et al. A novel classification of musculocutaneous nerve variations: The relationship between the communicating branch and transposed innervation of the brachial flexors to the median nerve. *Ann Anat.* 2017;209:45–50. <https://doi.org/10.1016/j.aanat.2016.08.004>.
- <sup>7</sup> Benes M, Kachlik D, Belbl M, et al. A meta-analysis on the anatomical variability of the brachial plexus: Part I – Roots, trunks, divisions and cords. *Ann Anat.* 2021;238:151751. <https://doi.org/10.1016/j.aanat.2021.151751>.
- <sup>8</sup> Radunovic M, Vukasanovic-Bozanic A, Radojevic N, Vukadinovic T. A new anatomical variation of the musculocutaneous and the median nerve anastomosis. *Folia Morphol.* 2013;72(2):176–179. <https://doi.org/10.5603/FM.2013.0030>.

- <sup>9</sup> Nasrabadi HT, Abedelahi A, Shoorei H, et al. A variation of Musculocutaneous nerve without piercing the coracobrachialis muscle while communicating to the median nerve: A case report and literature review. *Int J Surg Case Rep.* 2017;41:453–455. <https://doi.org/10.1016/j.ijscr.2017.11.020>.
- <sup>10</sup> Benes M, Kachlik · David. Atypical branching of the musculocutaneous and median nerves with associated unusual innervation of muscles in the anterior compartment of the arm: case report and plea for extension of the current classification system. *Surg Radiol Anat.* 2021;43(5):671–678. <https://doi.org/10.1007/s00276-021-02731-8>.
- <sup>11</sup> Johnson EO, Vekris M, Demesticha T, Soucacos PN. Neuroanatomy of the brachial plexus: normal and variant anatomy of its formation. *Surg Radiol Anat.* 2010;32(3):291–297. <https://doi.org/10.1007/s00276-010-0646-0>.
- <sup>12</sup> Sirico F, Castaldo C, Baiocco V, et al. Prevalence of musculocutaneous nerve variations: Systematic review and meta-analysis. *Clin Anat.* 2019;32(2):183-195. <https://doi.org/10.1002/ca.23256>.
- <sup>13</sup> Guerri-Guttenberg RA, Ingolotti M. Classifying musculocutaneous nerve variations. *Clin Anat.* 2009;22(6):671–683. <https://doi.org/10.1002/ca.20828>.
- <sup>14</sup> Emamhadi M, Chabok SY, Samini F, et al. Anatomical variations of brachial plexus in adult cadavers; a descriptive study. *Arch Bone Jt Surg.* 2016;4(3):253–258.
- <sup>15</sup> Tuyakov B, Braczkowska M, Mieszkowski M, Onichimowski D, Mayzner-Zawadzka E. Training in regional anesthesia. *Polish Ann Med.* 2016;23(1):80–85. <https://doi.org/10.1016/j.poamed.2015.12.005>.
- <sup>16</sup> Bhattarai C, Poudel PP. Unusual variation in musculocutaneous nerves. *Kathmandu Univ Med J.* 2009;7(28):408–410. <https://doi.org/10.3126/kumj.v7i4.2763>.
- <sup>17</sup> Goel S, Rustagi SM, Kumar A, Mehta V, Suri RK. Multiple unilateral variations in medial and lateral cords of brachial plexus and their branches. *Anat Cell Biol.* 2014;47(1):77–80. <https://doi.org/10.5115%2Facb.2014.47.1.77>.
- <sup>18</sup> Orebaugh SL, Williams BA. Brachial plexus anatomy: Normal and variant. *ScientificWorldJournal.* 2009;9:300–312. <https://doi.org/10.1100/tsw.2009.39>.
- <sup>19</sup> Mavishettar SM, Iddalagave S. Musculocutaneous nerve and its variations. *Int J Gen Med Pharm.* 2013;2(4):53–64.
- <sup>20</sup> Feigl GC, Litz RJ, Marhofer P. Anatomy of the brachial plexus and its implications for daily clinical practice : regional anesthesia is applied anatomy. *Reg Anesth Pain Med.* 2020;45(8):620–627. <https://doi.org/10.1136/rapm-2020-101435>.