



Case Report

Combined right and left sided endocarditis in a hemodialysis patient: A cautionary tale

*Erjola Bolleke (Likaj)¹, Ermal Likaj², Saimir Seferi¹, Kristi Saliaj¹, Fjorba Mana²,
Selman Dumanj², Alma Idrizi¹*

¹ Department of Nephrology, Dialysis and Transplantation, University Hospital Center 'Mother Theresa', Tirana, Albania

² Department of Cardiac Surgery, University Hospital Center 'Mother Theresa', Tirana, Albania

ARTICLE INFO

Article history

Received: July 16, 2023

Accepted: December 2, 2023

Available online: February 2, 2024

Keywords

Critical care medicine

Nephrology

Cardiology and cardiovascular systems

Infectious diseases and tropical medicine

Doi

<https://doi.org/10.29089/paom/176244>

User license

This work is licensed under a
Creative Commons Attribution –
NonCommercial – NoDerivatives
4.0 International License.



ABSTRACT

Introduction: Infective endocarditis is a potentially life-threatening condition, more prevalent among chronic maintenance hemodialysis patients, as opposed to the general population.

Aim: Combined involvement of both the right and left heart chambers is exceptionally rare.

Case study: Herein, we present the case of a patient on long-term maintenance hemodialysis with right and left sided infective endocarditis.

Results and discussion: We discuss potential risk factors leading to the widespread infection and emphasize the importance of an early diagnosis and prompt treatment in yielding better outcomes.

Conclusions: The patient was treated successfully by a multidisciplinary team.

1. INTRODUCTION

Infective endocarditis (IE) is an uncommon, life-threatening infection of the endocardium, affecting native or prosthetic valves, cardiovascular devices and potentially any endothelium-lined structure.¹ Patients on hemodialysis are especially susceptible to healthcare-associated IE, largely due to their vascular access.²⁻⁸ Additionally, the presence of preexisting comorbidities including, the higher prevalence of degenerative heart valve diseases among hemodialysis patients, compared to the general population, as well as cardiac valve calcification owing to the dysregulation of the calcium and phosphate metabolism and chronic micro inflammation, diabetes mellitus and immune dysfunction, makes end-stage renal disease patients particularly vulnerable to frequent and prolonged bacteremia, catheter related bloodstream infections and IE.²⁻⁵

Patients typically present with fever and rigors. Additional symptoms include fatigue, malaise, night sweats, joint and muscle pain, hypotension, vascular and immunological phenomena, exit-site drainage.^{4,7} However, atypical presentations with lack of fever and rigors are commonly encountered among hemodialysis patients, due to their immunocompromised status.⁵ Diagnosis can be established using the modified Duke's criteria.^{2,7} Nevertheless, the frequent presence of atypical findings and recurrent episodes of bacteremia makes it difficult to heavily rely on the modified Duke's criteria, thus a high index of clinical suspicion is warranted in this population.⁵ Treatment consists of antibiotic therapy, surgery and potential removal of the infected vascular access.^{4,7}

2. AIM

We present a case of combined involvement of both the right and left heart chambers which is exceptionally rare.

3. CASE STUDY

A 51-year-old woman presented to the Emergency Department with a 2 month history of recurrent fever, dyspnea, chest pain and refractory anemia. The patient was diagnosed with end-stage renal disease 3 years prior to presentation and she started chronic maintenance hemodialysis. The patient underwent thrice weekly sessions via a subclavian central venous catheter, placed on the superior vena cava 1 year before. She had previous vascular access failures, including an arteriovenous fistula and an arteriovenous graft that had failed 5 months after its initial use, due to thrombosis. Her past medical history was significant for type 2 diabetes mellitus, arterial hypertension, heart failure NYHA Class III and *hepatitis B* infection.

On physical examination, her vital signs were as follows, heart rate 100–115 beats/min; respiratory rate 27 breaths/min; blood pressure 160/80 mmHg; oxygen saturation (SPO₂): 90% while on oxygen therapy; temperature 38°C. On auscultation,

a new, harsh diastolic murmur and bibasilar crackles were noted. Bilateral lower limb edema was also present.

Routine laboratory studies including a complete blood count, comprehensive metabolic panel, electrolyte panel and arterial blood gas test were ordered. They showed anemia (RBC $2.34 \times 10^6/L$), neutrophilic leukocytosis (WBC $13.0 \times 10^3/L$, neutrophils – 77%), as well as elevated C-reactive protein (18.84 mg/L), ferritin (1079.7 ng/mL) and NT-pro BNP (44050.40 pg/mL) levels. The rest of her workup included elevated BUN, creatinine, phosphorous, triglyceride, ALP and PTH levels, along with low calcium levels. The polymerase chain reaction test for COVID-19 was negative. Her blood cultures grew gram positive cocci, namely methicillin-resistant *Staphylococcus epidermidis*.

Both a transthoracic and transesophageal echocardiography, revealed a mobile density on the aortic valve, consistent with a vegetation about 18 mm, with evidence of severe aortic regurgitation. It also showed the central dialysis catheter extending in the right atrium, with several masses in the superior vena cava, possible vegetations or thrombi about 38 mm, in addition to a tricuspid valve vegetation of approximately 11 mm, with moderate tricuspid insufficiency requiring surgical treatment.

In view of the clinical and radiological findings, as well as the long-term use of the hemodialysis catheter, a diagnosis of IE associated with catheter related bloodstream infections was established. The patient started on triple antibiotic and anticoagulation therapy.

On the second day of admission, the patient developed pulmonary edema with shortness of breath, tachypnea and low oxygen saturation levels, requiring CPAP support. She was transferred to the Cardiac Surgery Department, where she underwent a successful aortic valve replacement with a mechanical valve and removal of the central venous catheter, as well as removal of the vegetations on the superior vena cava, right atrium and tricuspid valve (Figure 1).

The postoperative period was uneventful and the patient made a full recovery. She was discharged and continued her hemodialysis sessions at the dialysis unit.

4. DISCUSSION

As cardiovascular and metabolic disorders are on the rise, so is the incidence of chronic kidney disease.²⁻⁷ Adding to this, the improved survival rates and life-expectancy of end-stage renal disease patients, there is currently a growing population of patients undergoing renal replacement therapy, including chronic hemodialysis.

Patients on chronic hemodialysis are more prone to developing infectious complications including IE, with an estimated risk 17–18 times higher, compared to that of the general population.^{3,5} The incidence of IE among hemodialysis patients has been reported to be 1092 per 100 000 persons annually.⁶ Mortality has also been found to be substantially higher in maintenance hemodialysis patients, compared to the general population, with studies reporting

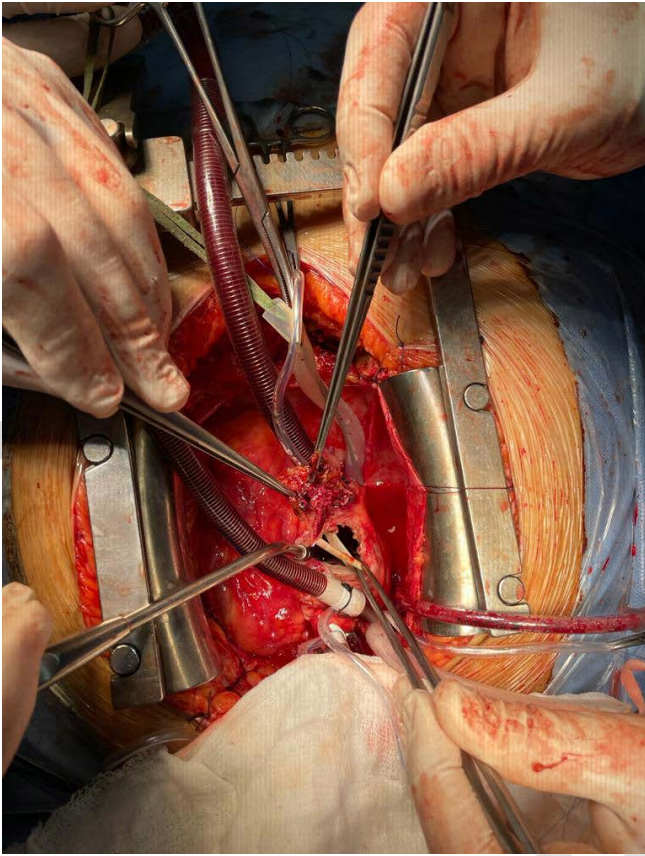


Figure 1. Permanent catheter with vegetations exposed after opening the right atrium.

a mortality up to 30% in the first 30 days of hospital admission and late mortality at approximately 64%, 1–2 years after admission.^{3,5,7}

Staphylococcus aureus has been identified as the leading causative organism of IE in the chronic hemodialysis population, with a majority of cases being methicillin-resistant.^{2–4} Coagulase-negative *Staphylococcus*, *Enterococcus*, *Staphylococcus epidermidis* and *Aspergillus* species account for the remaining cases.^{2,4,8}

The type of vascular access is the most important risk factor for the development of infective endocarditis in hemodialysis patients.^{2–8} Numerous studies have found that short-term and permanent central venous catheters are associated with higher rates of bacteremia and IE, compared to arteriovenous fistulas and arteriovenous grafts.^{2–8} Several studies postulate that arteriovenous fistulas may also predispose for episodes of bacteremia and IE, due to repeated vascular access during hemodialysis sessions.² Nevertheless, current literature overwhelmingly points to central venous catheters as the type of vascular access associated with a higher incidence of infective endocarditis, compared to both arteriovenous fistulas and grafts.^{2–7}

Chronic inflammation, atherosclerosis and impairment of the calcium and phosphate metabolism present in chronic kidney disease patients, predispose for valvular anomalies.^{2–5,9} On top of them, the type of vascular access, the recurrent vascular manipulation and associated bacteremia, in the context

of significant immune dysfunction and underlying valvular heart disease and calcifications, make chronic hemodialysis patients highly susceptible to IE, as opposed to the general population.^{2–6,9}

In chronic hemodialysis patients, as in the general the the population, left-sided IE is more prevalent, accounting for more than 80% of the reports.⁹ Established risk factors implicating the left side of the heart, include the higher pressures contributing to a turbulent flow and endothelial damage of the mitral and aortic valves, higher oxygen levels predisposing to better bacterial growth and higher prevalence of preexisting left valvular lesions.⁹ Mitral valve is more commonly involved, followed by the aortic valve, whereas concomitant involvement of both mitral and aortic valves is less frequent, accounting for 20% of reported cases.^{2,5} Right-sided IE in maintenance hemodialysis is rare, occurring in less than 26% of cases.⁹ Additional risk factors playing a role in right-sided involvement in hemodialysis patients, include placement of central venous catheters and the lower pressures on the right side of the heart, promoting larger vegetations and the presence of pulmonary hypertension that may lead to turbulent flow and endothelial damage.⁹

Combined right and left sided endocarditis is rare and particularly underestimated among maintenance hemodialysis patients. It has been associated with a higher index of pre-operative complications, including a higher degree of hemodynamic instability, increased incidence of abscess formation and septic shock at presentation.¹⁰ Higher mortality rates and overall worse postoperative outcomes have been reported in cases of combined right and left sided endocarditis.¹⁰

Our patient presented with both an aortic and tricuspid valve involvement, severe aortic regurgitation, as well as tricuspid valve vegetation and moderate regurgitation, a rare and uncommon presentation, possibly precipitated by the presence of the central venous catheter in the subclavian vein.

Early antibiotic therapy, covering both Gram-positive and Gram-negative organisms should be initiated empirically, to reduce morbidity and mortality rates associated with IE.^{4,7} Blood culture remains the reference method in laboratory diagnostics of blood stream infections, while molecular techniques available at present are a valuable addition to it.¹¹

Surgery and removal of the infected vascular access are essential in ensuring definitive treatment.

5. CONCLUSIONS

- (1) IE is a potentially fatal condition, significantly more prevalent among hemodialysis patients.
- (2) A high index of clinical suspicion is paramount to ensure prompt treatment and reduce mortality rates.

Conflict of interest

The authors have no conflict of interest to declare.

Funding

No funding was received to aid in the preparation of this article.

Ethics

Informed consent was obtained from the patient regarding the publication of this report.

References

- ¹ Walsh MJ, Shetty AK. Infective endocarditis. In: Ungerleider RM, Meliones JN, McMillan KN, Cooper DS, Jacobs JP, ed. *Critical Heart Disease in Infants and Children*. 3rd Ed. Philadelphia: Elsevier; 2019:823–835.
- ² Pericàs JM, Llopis J, Jiménez-Exposito MJ, et al. Infective endocarditis in patients on chronic hemodialysis. *J Am Coll Cardiol*. 2021;77(13):1629–1640. <https://doi.org/10.1016/j.jacc.2021.02.014>.
- ³ Doulton T, Sabharwal N, Cairns HS, et al. Infective endocarditis in dialysis patients: new challenges and old. *Kidney Int*. 2003;64(2):720–727. <https://doi.org/10.1046/j.1523-1755.2003.00136.x>.
- ⁴ Farrington CA, Allon M. Management of the hemodialysis patient with catheter-related bloodstream infection. *Clin J Am Soc Nephrol*. 2019;14(4):611–613. <https://doi.org/10.2215%2FCJN.13171118>.
- ⁵ Nucifora G, Badano LP, Viale P, et al. Infective endocarditis in chronic haemodialysis patients: an increasing clinical challenge. *Eur Heart J*. 2007;28(19):2307–2312. <https://doi.org/10.1093/eurheartj/ehm278>.
- ⁶ Chaudry MS, Carlson N, Gislason GH, et al. Risk of infective endocarditis in patients with end stage renal disease. *Clin J Am Soc Nephrol*. 2017;12(11):1814–1822. <https://doi.org/10.2215/cjn.02320317>.
- ⁷ Rajani R, Klein JL. Infective endocarditis: A contemporary update. *Clin Med*. 2020;20(1):31–35. <https://doi.org/10.7861/clinmed.cme.20.1.1>
- ⁸ Yew MS, Leong AM. Contemporary management and outcomes of infective tunnelled haemodialysis catheter-related right atrial thrombi: a case series and literature review. *Singapore Med J*. 2020;61(6):331–337. <https://doi.org/10.11622/smedj.2019124>.
- ⁹ Bentata Y. Physiopathological approach to infective endocarditis in chronic hemodialysis patients: left heart versus right heart involvement. *Ren Fail*. 2017;39(1):432–439. <https://doi.org/10.1080/0886022x.2017.1305410>.
- ¹⁰ Musci M, Siniawski H, Pasic M, et al. Surgical treatment of right-sided active infective endocarditis with or without involvement of the left heart: 20-year single center experience. *Eur J Cardiothorac Surg*. 2007;32(1):118–125. <https://doi.org/10.1016/j.ejcts.2007.02.034>.
- ¹¹ Marchel H, Wróblewska M. Bloodstream infections – etiology and current microbiological diagnostics. *Pol Ann Med*. 2022;29(1):83–87. <https://doi.org/10.29089/2021.21.00193>.