

## Research paper

### Bronchoscopies in pediatric patients – single centre study

*Mikołaj Herba<sup>1</sup>, Katarzyna Alicja Górny<sup>1</sup>, Hanna Kubik<sup>1</sup>,  
Andrzej Grabowski<sup>2</sup>, Wojciech Korlacki<sup>2</sup>*

<sup>1</sup> Students' Scientific Association at the Department of Children's Developmental Defects Surgery and Traumatology in Zabrze,  
Faculty of Medical Sciences in Zabrze, Medical University of Silesia, Katowice, Poland

<sup>2</sup> Department of Children's Developmental Defects Surgery and Traumatology in Zabrze, Medical University of Silesia, Katowice, Poland

#### ARTICLE INFO

##### Article history

Received: August 6, 2024

Accepted: October 18, 2024

Available online: April 22, 2025

##### Keywords

Foreign body aspiration

Rigid bronchoscopy

Children health

Inflammation of the lower respiratory tract

##### Doi

<https://doi.org/10.29089/paom/194880>

##### User license

This work is licensed under a  
Creative Commons Attribution –  
NonCommercial – NoDerivatives  
4.0 International License.



#### ABSTRACT

**Introduction:** Bronchoscopy is an endoscopic examination of the trachea and major bronchi. Indications for bronchoscopy can be categorized into clinical, radiological, and therapeutic. These include airway compression, recurrent and complex pneumonia, foreign body aspiration (FBA), interstitial lung disease, endoscopic intubation, caustic ingestion, and bronchiectasis. Bronchoscopy is generally regarded as a safe procedure, with major complications being rare.

**Aim:** Determine frequency of complications and safeness of bronchoscopies among pediatric patients.

**Material and methods:** This retrospective analytical study reviewed data from patients referred for bronchoscopy at the Pediatric Departments of the Medical University of Silesia between January 2017 and June 2023. Over a 6-year period, 71 bronchoscopies were performed on 61 patients, ranging in age from 8 days to nearly 17 years (mean age: 2.24 years). The cohort included 24 girls and 37 boys; 6 children (3 boys and 3 girls) had more than 1 bronchoscopy. The study aimed to characterize the procedure and the patient population undergoing rigid bronchoscopy.

**Results and discussion:** The most common symptom prompting bronchoscopy was a cough, reported by 27 patients (38%). Foreign bodies were identified in 17 procedures (24%), with peanuts being the most frequent form of foreign body (13 cases, 76%). The average duration of the procedure was 18 minutes. Complications were observed in 5 bronchoscopies (7%).

**Conclusions:** Bronchoscopy is a safe procedure in the pediatric population. In cases of ambiguous symptoms, FBA should be ruled out. Rigid bronchoscopy under general anesthesia remains the preferred technique for managing FBA in pediatric patients.

## 1. INTRODUCTION

Bronchoscopy is an endoscopic examination of the trachea and major bronchi, performed using either a flexible or rigid bronchoscope. During the procedure, it is essential to monitor oxygen saturation, blood pressure, and electrocardiogram (ECG). To maintain an oxygen saturation level greater than 90%, oxygen is administered via a nasal catheter. Each bronchoscopy room must be equipped with resuscitation tools.<sup>1,2</sup>

Indications for bronchoscopy can be divided into clinical, radiological, and therapeutic categories.<sup>1</sup> These include airway compression, recurrent and complex pneumonia, foreign body aspiration (FBA), interstitial lung disease, endoscopic intubation, caustic ingestion, and bronchiectasis. Stridor and wheezing are among the most frequent indications for bronchoscopy.<sup>3</sup>

Contraindications for bronchoscopy include severe respiratory failure (except in therapeutic bronchoscopy), severe heart failure (NYHA class IV), recent myocardial infarction or unstable angina, severe arrhythmias (especially ventricular arrhythmias), cervical spine degeneration (related to rigid bronchoscopy), and a platelet count of 20,000/ $\mu$ L or less.<sup>1</sup>

The process of bronchoscopy is regarded as safe, and major complications are uncommon. The most frequent adverse events include infections, hypoxia, and bradycardia caused by obstruction during the procedure. Other potential side effects are laryngeal edema, laryngeal spasm, bronchospasm, bleeding in the tracheal and bronchial systems, pneumothorax, pneumomediastinum, palate trauma, and post-operative stridor.<sup>1-5</sup> An adverse event is any medical issue occurring before, during, or after a procedure, even if it is not directly related to the procedure, whereas a complication refers to an unwanted, unique, and often unanticipated result of the procedure.<sup>6</sup>

The decision to use a flexible or rigid bronchoscope depends on the bronchoscopist's experience, the type of foreign body (FB), its location, and the necessary facilities for the procedure.<sup>7</sup> At our center, rigid bronchoscopy was used for our patients. In children, rigid bronchoscopy is typically performed under general anesthesia with ventilation assistance. The risk of subglottic edema, associated with manipulation of a rigid bronchoscope inserted orally, can be mitigated by selecting the appropriately sized bronchoscope for the patient's age.<sup>8</sup>

**Table 1. Size of the rigid bronchoscope according to age.<sup>8</sup>**

Patient mean age (range), years	Size, mm	Outside diameter, mm
Premature infant	2.5	3.7
Term newborn (birth – 3 months)	3.0	4.8
6 months (3 – 18 months)	3.5	5.7
18 months (1 – 3 years)	3.7	6.3
3 years (1½ – 5 years)	4.0	6.7
5 years (3 – 10 years)	5.0	7.8
10 years (>10 years – adolescent)	6.0	8.2

The purpose of this paper is to share personal experiences in using bronchoscopy as a diagnostic and therapeutic tool for children

## 2. AIM

This study aimed to determine the retrospective comparative analysis, the frequency of complications of the procedure, and the safeness of bronchoscopies performed among pediatric patients during the last 6 years in our clinic.

## 3. MATERIAL AND METHODS

This retrospective analytical study reviewed all available data for patients referred to the Pediatric Departments of the Medical University of Silesia with symptoms that led to bronchoscopy procedures between January 2017 and June 2023.

The goal was to characterize the procedure and the patient population undergoing rigid bronchoscopy. Collected data included age, sex, BMI, and symptoms. Additionally, we examined procedural factors such as duration, bronchoscope type, findings during the procedure, and complications.

Clinical and radiological data were gathered from the hospital's computerized database, chart reviews, and radiological systems. Patients were selected for bronchoscopy based on preliminary examinations, clinical symptoms, and X-ray analyzes. Under general anesthesia, standardized procedures were used to intubate each patient with a rigid bronchoscope, employing mechanical debridement when necessary.

If a foreign body was discovered, forceps were used to grasp and remove it, guided by the bronchoscope's light. After removal, the bronchial tree was examined thoroughly. In cases of inflammation or excessive mucus or pus, these were suctioned out, and samples were taken for bacteriological analysis. Following the removal of the bronchoscope, the anesthesiologist intubated the patient to ensure safe recovery from general anesthesia. All children with complications following the bronchoscopy procedure were assessed using the Clavien-Dindo classification (Clavien I–II):

- I. Any deviation from the normal postoperative course without the need for pharmacological treatment or surgical, endoscopic, and radiological interventions.
- II. Complications requiring pharmacological treatment with drugs other than those allowed for grade I complications).

Over a period of 6 years, 71 bronchoscopies were performed in 61 patients, ranging in age from 8 days to 17 years (mean age 2.24 years). 6 children (3 boys and 3 girls) had more than 1 bronchoscopy. One boy and 1 girl underwent this procedure 4 times, 2 boys and 2 girls – 2 times. Four of the 6 children who had multiple operations were under 1 year old. The most common age group undergoing bronchoscopy was 1 to 5 years. There were 24 girls and 37 boys. The lowest body mass index (BMI) recorded was 8.84 kg/m<sup>2</sup> and the highest was 28.12 kg/m<sup>2</sup>, with an average BMI of 15.45 kg/m<sup>2</sup>.

Statistical analysis was conducted on the collected data to determine correlations between the variables. The Pearson correlation coefficient ( $R$ ) was employed for the statistical analysis. The analysis was performed using the SciPy library in Python version 3.10.

#### 4. RESULTS

Upon admission, the general condition of patients without FBA was assessed as good in 33 patients (61%), moderate in 7 patients (13%), and severe in 14 patients (26%). In contrast, the general condition of individuals with FBA was assessed as good in 16 cases and moderate in 1 case. The most frequent symptom reported was cough, observed in 27 patients (38%). Auscultatory changes (crackles, rhonchi, wheezes, unilateral decreased breath sounds, bilateral decreased breath sounds) were noted in 45 patients (63%). Suspicion of the presence of a foreign body was an indication for bronchoscopy in 34 patients (48%). A foreign body was identified in 17 procedures, representing 51% of the patients with suspected foreign body and 24% of all procedures. Among patients with a suspected foreign body, cough was reported in 21 cases (62%), making it the most frequent single symptom, and auscultatory changes were observed in 30 cases (88%). In patients with confirmed FBA, cough was the most frequent symptom, reported in 12 cases (71%), and auscultatory changes were noted in 13 cases (76%). However, statistical analysis did not reveal a significant correlation between symptom type and the presence of a foreign body ( $P = 0.5885$ ).

The average duration of the procedure was 18 minutes. The most prevalent foreign body was a peanut, found in 13 patients (76.4%), followed by a raisin, Lego block, drawing pin, residual foreign body each in 1 patient (5.9%). The right bronchus was the most common localization of foreign bodies (13 patients, 76.4%), followed by the left bronchus (3 patients, 17.6%), and the trachea (1 patient, 5.9%).

Positive bacterial cultures were obtained in 17 patients undergoing bronchoscopy, detecting 31 bacterial strains. Among these, 18 (58.1%) were gram-negative and 13 (41.9%) were gram-positive, with the most frequent strains being *Streptococcus mitis* (G+) in 10 cases (32.3%) and *Neisseria lactamica* (G-) in 6 cases (19.3%). Coinfection with different strains was present in 13 patients (76.5%). Fungal infections were observed in 3 patients (*Candida albicans* and *C. lusitaniae*). Only 1 patient undergoing bronchoscopy with the presence of a foreign body was found to have bacterial cultures. Statistical analysis did not show a significant correlation between bacterial strain type and the presence of a foreign body ( $P = 0.0608$ ), or between bacterial type and symptoms ( $P = 0.535$ ).

Complications, including regional bleeding and mucosal membrane irritation, were observed in 5 bronchoscopies (7.0%). The most common complication was bleeding, noted in 3 procedures (4.2%). No severe complications were reported during the procedures in our study group.

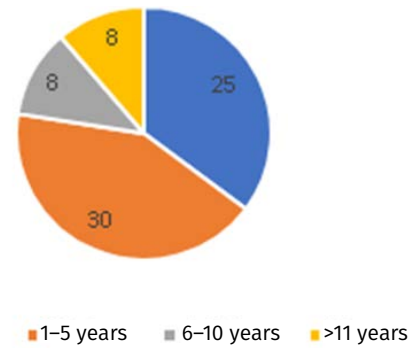


Figure 1. Age distribution of pediatric patients undergoing bronchoscopy,  $n$

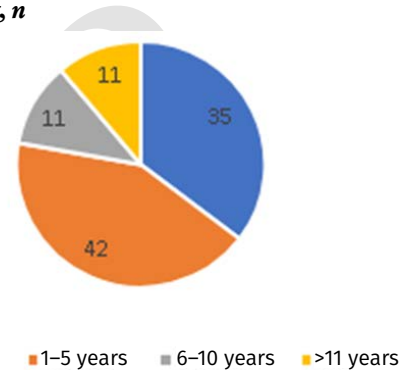


Figure 2. Age distribution of pediatric patients undergoing bronchoscopy, %

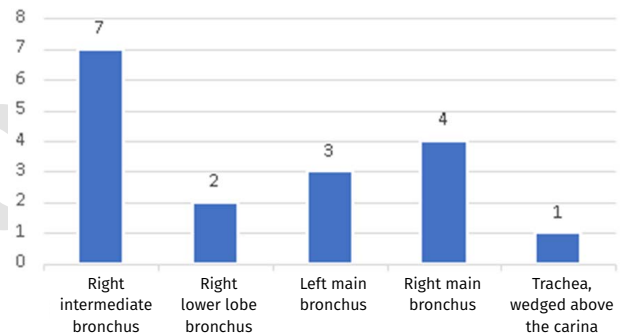


Figure 3. Location of FB detection in bronchoscopy,  $n$

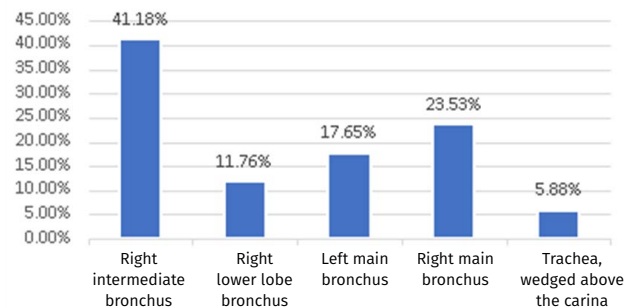


Figure 4. Location of FB detection in bronchoscopy, %

## 5. DISCUSSION

Based on the articles analyzed, the average age of patients undergoing bronchoscopy for emergency indications in the pediatric population was similar in Poland and internationally. In Poland, depending on the study, it was between 3 and 5.5 years of age, and worldwide between 1.8 and 4.1 years.<sup>4,9,10,13-15</sup> These data are in line with our analysis, where the average age of patients was 2.24 years.

In our study the right bronchus was the most common localization of FBs found in 76.4% of analyzed patients with confirmed FBA. In the general population, FBs are frequently located in the right bronchial tree, a pattern attributed to the anatomical structure of the tracheobronchial tree.<sup>16</sup> However, in the pediatric population, this correlation is not as distinctly observed. While the right bronchial tree predominated in most studies, the difference in FB location between the right and left sides rarely exceeded 10% points.<sup>3,9,15,17,18</sup> Additionally, some centers have reported a higher prevalence of foreign bodies in the left bronchial tree.<sup>10,19</sup> The variability in the position of the carina relative to the mid-trachea may explain why this right-sided preference is less pronounced in children than in adults.<sup>16</sup>

The most prevalent FBs identified during bronchoscopy were food items.<sup>15</sup> The majority of these were identified as various types of nuts, with seeds also being a common finding.<sup>9,10,17-21</sup> Similarly in our present study, a peanut represented a FB that was the most frequently found (in 13 patients; 76.4%).

Recent reports indicate that rigid bronchoscopy is preferable to flexible bronchoscopy for FBA, particularly in younger children with asphyxiating FBs or when physical examination reveals unilateral decreased breath sounds and wheezing, accompanied by hyperinflation and atelectasis on imaging. The authors recommend that flexible bronchoscopy should only be performed if there is the capability to convert to rigid bronchoscopy at any point during the procedure.<sup>17,18,21-24</sup> According to the American Thoracic Society, the presence of only one small suction channel during flexible bronchoscopy reduces the likelihood of successful FB removal and increases the risk of the FB becoming dislodged.<sup>22</sup>

Only 10.7% of the 121 patients who initially underwent flexible bronchoscopy were successfully treated using this technique. Following an attempt to extract the FB with flexible bronchoscopy, 3 patients experienced severe complications necessitating thoracotomy due to the dislodgement of the foreign body. In contrast, rigid bronchoscopy demonstrated a 98% success rate for FB removal.<sup>24</sup> The benefits of rigid bronchoscopy include the ability to secure the airway, utilize a variety of instruments, and serve as both a retrieval channel and an endotracheal rigid tube. Positive-pressure ventilation combined with appropriate anesthesia facilitates a stable airway and simplifies FB retrieval. However, this method may cause the FB to move distally, complicating its removal, and may result in ball-valve airway obstruction. Ensuring general anesthesia that is both comfortable and safe is crucial for these procedures.<sup>18</sup>

Flexible bronchoscopy is considered the gold standard for directly visualizing the airways, facilitating numerous diagnostic and therapeutic interventions.<sup>25</sup> Recent research indicates that flexible bronchoscopy is increasingly being utilized for the removal of FBs from the airway.<sup>19,21,23</sup> Suggest that flexible bronchoscopy is particularly effective for removing residual FBs following rigid bronchoscopy, especially in complex cases. This technique offers advantages such as flexibility, the ability to perform endotracheal lavage, and enhanced video imaging capabilities. Flexible bronchoscopy is thus a valuable procedure that complements rigid bronchoscopy, forming an optimal treatment strategy for FB removal in the airways.<sup>20</sup>

Rigid bronchoscopy may be indicated in several instances: retrieval of FBs, control of airway bleeding, dilation of airway strictures, and acquisition of deeper tissue biopsy specimens when the fiberoptic technique is insufficient. Additionally, rigid bronchoscopy is employed for relieving airway obstruction, inserting stents, and performing laser therapy or other mechanical tumor ablation.<sup>2,26</sup> In the studies analyzed, the most common symptoms prompting bronchoscopy in the pediatric population were cough, expectoration, breathlessness, and wheezing.<sup>3,9,18,19</sup>

Wiemers et al. conducted a comparative study on the frequency of complications associated with rigid and flexible bronchoscopy performed due to FBA. The study found that complications occurred in 19% of rigid bronchoscopies and 24.2% of flexible bronchoscopies. Respiratory complications were significantly less frequent during rigid bronchoscopy compared to flexible bronchoscopy. The incidence of cardiovascular complications, bleeding, and trauma to the mucosal wall did not differ significantly between the two types of procedures. Bleeding was observed in 9% of all performed procedures.<sup>27</sup>

In a large prospective study of 1,328 flexible bronchoscopies in children, complications were recorded in 6.9% of procedures, with minor complications (e.g., excessive coughing, transient desaturation) occurring in 5.2% and major complications (e.g., severe desaturation, pneumothorax) in 1.7% of cases.<sup>28</sup> Another comprehensive review reported complication rates for pediatric bronchoscopy ranging from 3.5% to 12.0%, depending on the reporting and procedures performed.<sup>29</sup> Post-bronchoscopy fever was also noted as a common complication, occurring in approximately 18.8% of cases following bronchoalveolar lavage (BAL).<sup>28</sup>

Among our patients, complications were observed in 7.0% of cases, with bleeding occurring in 4.2% and mucosal wall trauma in 2.8%. However, the analyzed group was composed of 71 patients, and only minor complications were recorded. This lower rate of major complications may be attributed to the smaller sample size and the specific population studied.

In Poland, bronchoscopy is most often performed on children aged 0–3 years due to FBA.<sup>9,10</sup> This is consistent with the results of research conducted worldwide.<sup>11,12</sup> This is the best diagnostic and therapeutic method for all suspicions of FBA.<sup>10</sup> The absence of molar teeth, a high larynx position, a defective epiglottis, an underdeveloped chewing

and swallowing reflex, and uncoordinated swallowing and breathing are anatomical and physiological factors that increase the risk of aspirating a foreign body. Additional risk factors for young children include excessive movement and exploration of the digestive system, inadequate parental supervision, availability of improper toys with small parts, and incorrect food consumption.<sup>9,13</sup> FBA in children is a severe condition that can have lethal consequences. Patients may suffer from anoxic brain damage (2.2%) and fatality (1.8%). Pediatric FBA is characterized by a child's suffocation, asphyxia, or inhalation of a solid substance into the airway tract at the level of the glottis, larynx, trachea, or bronchi. FBA symptoms include coughing, wheezing, and reduced breath sounds (the classic triad), and a delay in diagnosis can result in respiratory complications.<sup>3</sup>

## 6. CONCLUSIONS

1. Bronchoscopy is a safety procedure, complications occur in 7% of interventions.
2. Inflammation of the lower respiratory tract is one of the most common indications to perform bronchoscopy.
3. There are no specific symptoms indicating FBA, therefore it should always be considered in cases of respiratory failure in the pediatric population. A patient's favorable general condition does not preclude the potential presence of a FB within the respiratory tract.
4. Clinical management strategies ought to be guided by meticulous acquisition of patient history, comprehensive physical examination, and, when warranted, diagnostic imaging modalities to address uncertainties.
5. Rigid bronchoscopy with general anesthesia remains the preferred technique in the pediatric population.

## Conflict of interest

The authors report no conflict of interest.

## Funding

The authors declare that there are no financial interests in this manuscript.

## Ethics

All procedures performed in studies were in accordance to the ethical standards of the institutional and/or national research committee and with the 1964 Helsinki declaration and its later amendments or comparable ethical standards. The Bioethics Committee of the Medical University of Silesia in Katowice responded to the inquiry about the need for consent to conduct a retrospective study as follows: 'Retrospective data analysis is not a medical experiment and does not require evaluation by the Bioethics Committee of the Medical University of Silesia.' Decision number: BNW/NWN/0052/KB194/23.

## References

- 1 Dutau H, Vandemoortele T, Breen DP. Rigid bronchoscopy. *Clin Chest Med.* 2013;34(3):427–435. <https://doi.org/10.1016/j.ccm.2013.04.003>.
- 2 Nicastrì DG, Weiser TS. Rigid bronchoscopy: Indications and techniques. *Oper Tech Thorac Cardiovasc Surg.* 2012;17(1):44–51. <https://doi.org/10.1053/j.optechstcvs.2012.03.001>.
- 3 Mohsen F, Bakkar B, Melhem S, et al. Foreign body aspiration in a tertiary Syrian centre: A 7-year retrospective study. *Heliyon.* 2021;7(3):e06537. <https://doi.org/10.1016/j.heliyon.2021.e06537>.
- 4 Hasdiraz L, Oguzkaya F, Bilgin M, Bicer C. Complications of bronchoscopy for foreign body removal: Experience in 1035 cases. *Ann Saudi Med.* 2006;26(4):283–287. <https://doi.org/10.5144/0256-4947.2006.283>.
- 5 Kordykiewicz D, Szaj M, Pieróg J, et al. Enhancing diagnostic precision: Electromagnetic navigation bronchoscopy with cryobiopsy in pulmonary and mediastinal lesions – A case study. *Pol Ann Med.* 2024;31(1):45–48. <https://doi.org/10.29089/paom/175728>.
- 6 Attard TM, Grima AM, Thomson M. Pediatric Endoscopic Procedure Complications. *Curr Gastroenterol Rep.* 2018;20(10):48. <https://doi.org/10.1007/s11894-018-0646-5>.
- 7 Moslehi MA. Failures in emergency management of pediatric airway foreign bodies by rigid bronchoscopy: We have yet to complete our learning. *World J Pediatr Surg.* 2022;5(2). <https://doi.org/10.1136/wjps-2021-000321>.
- 8 de Azevedo Sias SM, Barbosa Domingues AC, Mannarino RV. (2012). Pediatric Bronchoscopy. In: Haranath SP, Razvi S, eds. *Global Perspectives on Bronchoscopy*. London: InTech. 2012. <https://doi.org/10.5414/ATX02449>.
- 9 Pietraś A, Markiewicz M, Mielnik-Niedzielska G. Rigid bronchoscopy in foreign body aspiration diagnosis and treatment in children. *Children.* 2021;8(12):1206. <https://doi.org/10.3390/children8121206>.
- 10 Korlacki W, Korecka K, Dzielicki J. Foreign body aspiration in children: Diagnostic and therapeutic role of bronchoscopy. *Pediatr Surg Int.* 2011;27(8):833–837. <https://doi.org/10.1007/s00383-011-2874-8>.
- 11 Handa A, Dhooria S, Sehgal IS, Agarwal R. Primary cavitary sarcoidosis: A case report, systematic review, and proposal of new diagnostic criteria. *Lung India.* 2018;35(1):41–46. [https://doi.org/10.4103/lungindia.lungindia\\_225\\_17](https://doi.org/10.4103/lungindia.lungindia_225_17).
- 12 Wanstreet T, Ramadan J, Carr MM. Airway foreign bodies in pediatric patients: An analysis of composition and age via HCUP KID. *Int J Pediatr Otorhinolaryngol.* 2021;142:110559. <https://doi.org/10.1016/j.ijporl.2020.110559>.
- 13 Cutrone C, Pedruzzi B, Tava G, et al. The complimentary role of diagnostic and therapeutic endoscopy in foreign body aspiration in children. *Int J Pediatr Otorhinolaryngol.* 2011;75(12):1481–1485. <https://doi.org/10.1016/j.ijporl.2011.08.014>.

- <sup>14</sup> Haller L, Barazzone-Argiroffo C, Vidal I, Corbelli R, Anooshiravani-Dumont M, Mornand A. Safely decreasing rigid bronchoscopies for foreign-body aspiration in children: An algorithm for the Emergency Department. *Eur J Pediatr Surg*. 2018;28(3):273–278. <https://doi.org/10.1055/s-0037-1603523>.
- <sup>15</sup> Paap MK, Leuin S, Carvalho D. Pediatric foreign body aspiration: Time of occurrence and factors affecting outcomes. *Pediatr Emerg Care*. 2022;38(2):e958–e960. <https://doi.org/10.1097/pec.0000000000002503>.
- <sup>16</sup> Tahir N, Ramsden WH, Stringer MD. Tracheobronchial anatomy and the distribution of inhaled foreign bodies in children. *Eur J Pediatr*. 2009;168(3):289–295. <https://doi.org/10.1007/s00431-008-0751-9>.
- <sup>17</sup> Swanson KL, Prakash UBS, Midthun DE, et al. Flexible bronchoscopic management of airway foreign bodies in children. *Chest*. 2002;121(5):1695–1700. <https://doi.org/10.1378/chest.121.5.1695>.
- <sup>18</sup> Sahin A, Meteroglu F, Eren S, Celik Y. Inhalation of foreign bodies in children: Experience of 22 years. *J Trauma Acute Care Surg*. 2013;74(2):658–663. <https://doi.org/10.1097/ta.0b013e3182789520>.
- <sup>19</sup> Xu B, Wu L, Jin Z, et al. Residual airway foreign bodies in children who underwent rigid bronchoscopy. *Int J Pediatr Otorhinolaryngol*. 2019;118:170–176. <https://doi.org/10.1016/j.ijporl.2019.01.007>.
- <sup>20</sup> Tenenbaum T, Kähler G, Janke C, Schrotten H, Demirakca S. Management of Foreign Body Removal in Children by Flexible Bronchoscopy. *J Bronchol Interv Pulmonol*. 2017;24(1):21–28. <https://doi.org/10.1097/lbr.0000000000000319>.
- <sup>21</sup> Hata A, Nakajima T, Ohashi K, et al. Mini grasping basket forceps for endobronchial foreign body removal in pediatric patients. *Pediatr Int*. 2017;59(11):1200–1204. <https://doi.org/10.1111/ped.13384>.
- <sup>22</sup> Faro A, Wood RE, Schechter MS, et al. Official American Thoracic Society technical standards: Flexible airway endoscopy in children. *Am J Respir Crit Care Med*. 2015;191(9):1066–1080. <https://doi.org/10.1164/rccm.201503-0474st>.
- <sup>23</sup> Kazachkov M, Vicencio A. Foreign body removal is getting “cooler.” *Pediatr Pulmonol*. 2016;51(9):886–888. <https://doi.org/10.1002/ppul.23521>.
- <sup>24</sup> Schramm D, Ling K, Schuster A, Nicolai T. Foreign body removal in children: Recommendations versus real life – A survey of current clinical management in Germany. *Pediatr Pulmonol*. 2017;52(5):656–661. <https://doi.org/10.1002/ppul.23609>.
- <sup>25</sup> José RJ, Shaefi S, Navani N. Sedation for flexible bronchoscopy: Current and emerging evidence. *Eur Respir Rev*. 2013;22(128):106–116. <https://doi.org/10.1183/09059180.00006412>.
- <sup>26</sup> Ernst A, Silvestri GA, Johnstone D. Interventional pulmonary procedures: Guidelines from the American College of Chest Physicians. *Chest*. 2003;123(5):1693–1694. <https://doi.org/10.1378/chest.123.5.1693>.
- <sup>27</sup> Wiemers A, Vossen C, Lücke T, et al. Complication rates in rigid vs. flexible endoscopic foreign body removal in children. *Int J Pediatr Otorhinolaryngol*. 2023;166:111474. <https://doi.org/10.1016/j.ijporl.2023.111474>.
- <sup>28</sup> de Blic J, Marchac V, Scheinmann P. Complications of flexible bronchoscopy in children: Prospective study of 1,328 procedures. *Eur Respir J*. 2002;20(5):1271–1276. <https://doi.org/10.1183/09031936.02.02072001>.
- <sup>29</sup> Du Rand IA, Blaikley J, Booton R, et al. British Thoracic Society guideline for diagnostic flexible bronchoscopy in adults. *Thorax*. 2013;68(Suppl 1):i1–i44. <https://doi.org/10.1136/thoraxjnl-2013-203618>.