



Case Report

Rare but real: A case report of appendiceal atresia

Jin-Jiun Mah¹, Sentilnathan Subramaniam¹, Firdaus Hayati^{2,3} 

¹ Department of Surgery, Queen Elizabeth Hospital, Kota Kinabalu, Sabah, Malaysia

² Department of Surgery, Faculty of Medicine and Health Sciences, Universiti Malaysia Sabah, Kota Kinabalu, Sabah, Malaysia

³ Ministry of Health, Malaysia

ARTICLE INFO

Article history

Received: April 23, 2024

Accepted: November 14, 2024

Available online: May 22, 2025

Keywords

Appendix

Atresia

Appendiceal atresia

Atretic appendix

Case report

Doi

<https://doi.org/10.29089/paom/195979>

User license

This work is licensed under a
Creative Commons Attribution –
NonCommercial – NoDerivatives
4.0 International License.



ABSTRACT

Introduction: One of the most common presentations with acute abdomen is acute appendicitis. Although rare, appendiceal anomalies can significantly complicate clinical presentations. These anomalies can include structural abnormalities, such as duplication, triplication, horseshoe appendix, congenital stenosis, and atresia, which can cause right lower quadrant pain and lead to misdiagnosis in patients with an acute abdomen.

Aim: This case study aims to describe a rare case of vermiform appendiceal atresia in a middle-aged woman with an acute abdomen.

Case study: A 40-year-old woman with no significant medical history presented with abdominal pain, vomiting, and fever. The clinical examination revealed dehydration, tachycardia, and rebound tenderness. Upon exploratory laparotomy, the appendix appeared inflamed with an atretic segment in the distal portion of the appendix. An appendectomy was performed and she had a smooth recovery. Histopathological examination revealed a fibrous band connecting the tip and body of the appendix with the lumen completely obliterated.

Results and discussion: Appendiceal atresia is an infrequent surgical entity whose pathogenesis and clinical implications remain largely unknown. Similar to intestinal atresia, which is primarily attributed to vascular accidents during foetal development, the aetiology of appendiceal atresia is presumed to follow the same pathogenesis. Additionally, more understanding of this clinical rarity's long-term implications and prognosis must be understood, including its potential associations with other medical conditions.

Conclusions: Appendiceal atresia is rare and may complicate the clinical picture of a patient with an acute abdomen. The pathophysiology and long-term consequences of this clinical rarity remain unclear.

Corresponding author: Firdaus Hayati; Department of Surgery, Faculty of Medicine and Health Sciences, Universiti Malaysia Sabah, 88400 Kota Kinabalu, Sabah, Malaysia.
E-mail address: firdaushayati@gmail.com, m_firdaus@ums.edu.my

1. INTRODUCTION

Acute appendicitis is the most common acute surgical condition and appendectomy is the most frequently performed emergency surgery. Acute appendicitis occurs when inflammation of the appendix is caused by lymphoid hyperplasia, appendicoliths, parasites, or foreign bodies obstructing the lumen. However, it is imperative to recognise that appendiceal anomalies, although rare, have the potential to complicate the clinical landscape significantly. Structural anomalies of the appendix, such as horseshoe appendix, congenital absence of the appendix, duplication of the appendix, congenital stenosis of the appendix vermiformis, triluminal septate appendix, and triplication of the appendix are exceedingly rare and typically encountered incidentally during surgical procedures or postmortem examinations.^{1–6} These conditions can cause right lower quadrant pain, leading to misdiagnosis in patients with an acute abdomen. The frequency of preoperative diagnosis of appendiceal anomalies is extremely low owing to their rarity, and most surgeons may never encounter such cases during their clinical practice. Herein, we present a rare case of vermiform appendiceal atresia in a middle-aged woman with an acute abdomen.

2. AIM

This case study aims to describe a rare case of vermiform appendiceal atresia in a middle-aged woman with an acute abdomen.

3. CASE STUDY

A 40-year-old woman presented with a 3-day history of abdominal pain. The pain was colicky and localised in the right iliac fossa. No radiation or migratory pain was noted. She also complained of vomiting of food particles and low-grade fever for 3 days. She denied loose stools or any other altered bowel habits. There were no symptoms suggestive of upper respiratory tract or urinary tract infections. She had regular menses, no vaginal discharge, and no other gynaecological symptoms. Apart from one lower segment caesarean section for breech presentation 8 years prior, there was no other surgical history. She has no known medical illnesses and no drug or food allergies.

Physical examination revealed a dehydrated lady, as evidenced by a dry-coated tongue and tachycardia of 105 bpm. Her blood pressure was 138/90 mmHg, saturating well in room air, and her body temperature was 36.5°C. Rebound tenderness was observed with guarding of the right lower abdomen and suprapubic regions, intact hernial orifices, and normal digital rectal examination. A gynaecological examination revealed a whitish curdy, non-foul-smelling vaginal discharge. No cervical or adnexal tenderness was observed. A urinary catheter was inserted for urine output

monitoring, and intravenous boluses of crystalloids were administered as part of the fluid resuscitation. The baseline haematological tests showed haemoglobin of 10.7 g/dL, total white cell counts of $10.38 \times 10^3/\mu\text{L}$ and platelet of $175 \times 10^3/\mu\text{L}$. Her biochemical tests revealed sodium of 138 mmol/L, potassium of 3.0 mmol/L, urea of 3.1 mmol/L and serum creatinine of 59.6 $\mu\text{mmol/L}$. Venous blood gas level was unremarkable.

Transabdominal ultrasonography revealed an anteverted uterus with normal endometrial thickness. There was no adnexal mass or free fluid in the pouch of Douglas. Contrast-enhanced computed tomography (CT) of the abdomen and pelvis was normal. Given the persistent pain, tenderness, and guarding on reassessment despite adequate analgesia, the patient was counselled to undergo surgery.

Due to a diagnostic dilemma and the unavailability of instruments for laparoscopic surgery, a lower midline exploratory laparotomy was performed. Upon entering the peritoneal cavity, minimal turbid ascitic fluid was noted in the pelvis. The appendix was mildly inflamed and showed no perforation or sloughing. An atretic segment, 1 cm in length, was noted in the distal portion of the appendix (Figure 1). The base of the appendix and caecum were healthy. The uterus, ovaries, and fallopian tubes were normal. The mesoappendix was dissected using diathermy, and the appendix was trans-fixed and transected at the base.

Histopathological examination revealed a central obliterative lesion with effacement of the mucosa and submucosa visualized at the distal appendix. The mucosal lining

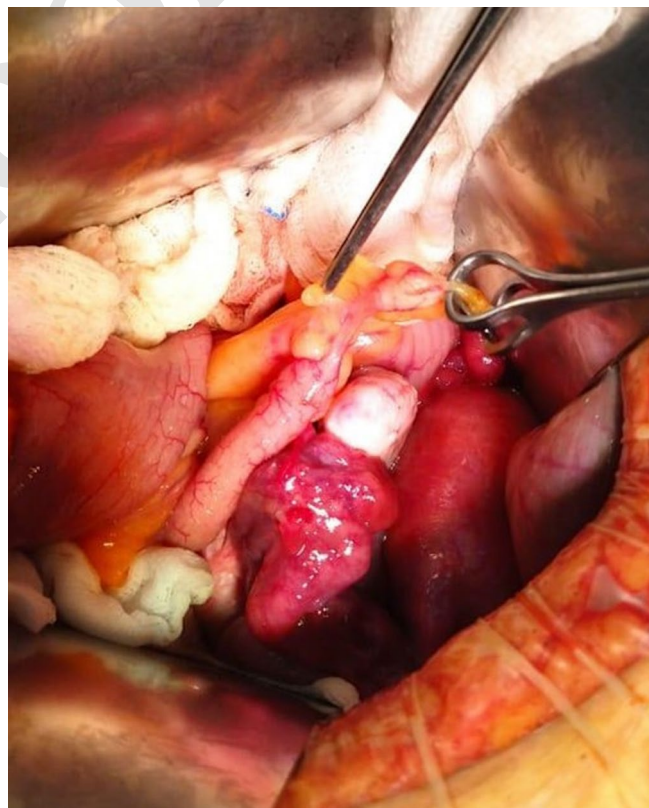


Figure 1. An atretic segment, 1 cm in length, located in the distal region of the appendix.

Table 1. Reported cases of atretic appendix.

No	Author	Country	Year	Age/Gender	Associated anomalies	Outcomes
1	Woywodt ⁷	South Africa	1998	4 day / m	Multiple jejunal atresias	Recovered post-op, lost to follow up
2	Yaylak ⁸	Turkey	2013	59 / m	None	Ischemic stroke post-operatively
3	Masood ⁹	Pakistan	2015	17 / f	None	Well
4	Ademaj ¹⁰	Kosovo	2023	15 / m	None	Well
5	Murayama ¹¹	Japan	2023	13 / f	None	Well

Comments: m – male; f – female.

of the rest of the appendix was generally intact, with mild superficial neutrophilic infiltration of the mucosa and lamina propria, associated with cryptitis and crypt abscess. The patient's recovery was uneventful. She was able to regain her usual bowel function on day 1 and was discharged on postoperative day 2. During the follow-up one month post-operatively, she was well, free of pain, and had returned to work. She underwent subsequent urinary tract ultrasonography and colonoscopy, which revealed normal result.

4. RESULTS AND DISCUSSION

Appendiceal atresia is exceptionally rare in the surgical literature, with only five documented cases reported to date, highlighting its scarcity (Table 1).^{7–11} Given its infrequent occurrence, several questions regarding appendiceal atresia's pathogenesis and clinical implications persist. Hypothetically, it is postulated that intestinal atresia happens after vascular accidents in bowel sections during foetal development. It is thought to be similar to other sites of intestinal atresia.¹¹ Ademaj et al., reported the first congenital stenosis of appendix vermiformis.¹⁰ Also, Woywodt et al. reported the first known case of appendiceal atresia in 1998, which was found alongside multiple jejunal atresias.⁷ If atresia is congenital and luminal occlusion is responsible for causing pain, when will it become symptomatic? Of the reported cases, one was found during the neonatal period, three during adolescence, and only one during adulthood. This is the second case in which an atretic appendix was found in adulthood. If the tip of the appendix is indeed a 'closed loop' due to the presence of atresia, it is intriguing how physiological mucus discharges from the appendicular mucosa drains.

Acute appendicitis is believed to be triggered by lymphoid hyperplasia, appendicoliths, parasites, or foreign bodies that cause luminal occlusion.^{12,13} Similarly, an asymptomatic Meckel's diverticulum with a narrow neck should be surgically removed to prevent future complications. If we hypothetically apply this concept to appendiceal atresia, it suggests that when the appendicular lumen is entirely occluded, increased intraluminal pressure could lead to pain, inflammation, and infection due to the triggering of an immune response. Therefore, in any patient with recurrent right lower quadrant pain of unknown aetiology, diagnostic laparoscopy is a viable option, considering the possibility of differential diagnosis of appendiceal atresia.

Congenital intestinal obstruction is a significant medical concern and can result from two primary mechanisms:

complete closure of the bowel lumen, known as atresia, or narrowing of the lumen, referred to as stenosis.¹⁴ Intestinal atresia is responsible for almost one-third of all congenital bowel obstructions and can develop anywhere in the gastrointestinal tract.^{15,16} Its incidence varies from 1.3 to 3.5 cases per 10,000 live births.^{17,18} Notably, the duodenum is the most commonly involved site (around 50% of cases), followed by the jejuno-ileal areas.¹¹

Certain conditions, including fibrous obliteration, can cause blockages in the appendix. Fibrous obliteration of the appendix is often associated with aging, although it may also be caused by repeated bouts of appendiceal inflammation.¹⁹ In contrast, some studies suggest that this condition is part of the aging process.²⁰ The condition begins at the tip or distal part of the appendix and extends proximally, causing loss of normal appendiceal mucosa and Peyer patches, ultimately replacing the mucosa and submucosa with fibrous tissue.²⁰ It can be distinguished from appendiceal atresia by the retention of muscular and serous layer structures at the site of obstruction.¹¹

Furthermore, the long-term effects and prognosis of appendiceal atresia are poorly understood. It is unclear whether appendiceal atresia is associated with any other medical conditions. Based on the reported cases, there is no evidence of long-term consequences directly linked to the atretic appendix. Identifying any genetic or familial predisposition to this condition, despite its rarity, may provide valuable information on its underlying causes.

5. CONCLUSIONS

1. This case highlights the rarity of appendiceal atresia and emphasises the importance of thorough abdominal exploration during the management of acute appendicitis.
2. This study also focuses on the importance of considering appendiceal atresia as a potential differential diagnosis in cases of right lower quadrant pain of unknown origin.

Conflict of interest

The authors have no conflicts of interest to declare.

Funding

No funding was received for this study.

Ethics

This case report is exempt from ethical approval due to the article's nature, as per our institution's ethical review board. Written informed consent was obtained from the patient for publication of this case report and accompanying images.

References

- ¹ Calotă F, Calotă F, Calotă F, et al. Horseshoe appendix: a extremely rare anomaly. *Chirurgia (Bucharest, Romania)*. 2010;105(2):271–274.
- ² Oruç C, Işık O, Üreyen O, Kahyaoglu OS, Köseoğlu A. An extremely rare appendiceal anomaly: horseshoe appendicitis. *Ulus Travma Acil Cerrahi Derg*. 2013;19(4):385–386. <https://doi.org/10.5505/tjtes.2013.67424>.
- ³ Sarkar A. Congenital absence of the vermiform appendix. *Singapore Med J*. 2012;53(9):e189–191.
- ⁴ Tutcu Şahin S, Erhan Y, Aydede H. Double acute appendicitis in appendical duplication. *Ulus Travma Acil Cerrahi Derg*. 2013;19(1):83–85. <https://doi.org/10.5505/tjtes.2013.80557>.
- ⁵ Sánchez NG, Estrada-Ortíz FA, Peñarrieta-Daher AA, Padilla-Rodríguez AL. Tri-luminal septate appendix: A morphologic variant of septa with muscularis propria. *Rev Gastroenterol Mex (Engl Ed)*. 2023;88(3):289–290. <https://doi.org/10.1016/j.rgmex.2023.04.005>.
- ⁶ Jo AH, Beardsley B. Triplication of the appendix: A case report. *Pathology*. 2016;48(S1).
- ⁷ Woywodt A, Verhaart S, Kiss A. Atresia of the appendix. *J Pediatr Surg*. 1998;33(9):1423–1425. [https://doi.org/10.1016/s0022-3468\(98\)90026-4](https://doi.org/10.1016/s0022-3468(98)90026-4).
- ⁸ Yaylak F, Algin MC, Gungor Y, Korkmaz M. Atresia of the appendix vermiformis: A rare case of developmental abnormality. *World J Gastroenterol*. 2013;19(1):122–124. <https://doi.org/10.3748/wjg.v19.i1.122>.
- ⁹ Masood I, Majid Z, Rafiq A, Fatima S, Bin Zia Siddiqui O. Appendicitis with appendicular atresia: A rare presentation. *Pan Afr Med J*. 2015;20:57. <https://doi.org/10.11604/pamj.2015.20.57.4500>.
- ¹⁰ Ademaj I, Kurshumliu F, Sylva A. Congenital stenosis of appendix vermiformis: A case report. *J Pediatr Surg Case Rep*. 2023;92:102619. <https://doi.org/10.1016/j.epsc.2023.102619>.
- ¹¹ Murayama M, Inoue M, Naoe A, Yasui T, Suzuki T. Appendiceal atresia causing recurrent right lower quadrant pain without inflammation. *Clin J Gastroenterol*. 2023;16(5):685–688. <https://doi.org/10.1007/s12328-023-01818-6>.
- ¹² Banieghbal BB, Lakhoo K. CAppendicitis. In: Ameh EA, Bickler SW, Lakhoo K, Nwomeh BC, Poenaru D, eds. *Pediatric Surgery: A Comprehensive Textbook for Africa*. 2nd Ed. Cham: Springer; 2020:775–779.
- ¹³ Jones BA, Demetriades D, Segal I, Burkitt D. The prevalence of appendiceal fecaliths in patients with and without appendicitis. A comparative study from Canada and South Africa. *Ann Surg*. 1985;202(1):80–82. <https://doi.org/10.1097/00000658-198507000-00013>.
- ¹⁴ Millar AJW, Cox S, Gosche JR, Lakhoo K. Intestinal atresia and stenosis. In: Ameh EA, Bickler SW, Lakhoo K, Nwomeh BC, Poenaru D, eds. *Pediatric Surgery: A Comprehensive Textbook for Africa*. 2nd Ed. Cham: Springer; 2020:663–670.
- ¹⁵ Anatol TI, Hariharan S. Congenital intrinsic intestinal obstruction in a Caribbean country. *Int Surg*. 2009;94(3):212–216.
- ¹⁶ Walker K, Badawi N, Hamid CH, et al. A population-based study of the outcome after small bowel atresia/stenosis in New South Wales and the Australian Capital Territory, Australia, 1992–2003. *J Pediatr Surg*. 2008;43(3):484–488. <https://doi.org/10.1016/j.jpedsurg.2007.10.028>.
- ¹⁷ Stallings EB, Isenburg JL, Short TD, et al. Population-based birth defects data in the United States, 2012–2016: A focus on abdominal wall defects. *Birth Defects Res*. 2019;111(18):1436–1447. <https://doi.org/10.1002/bdr2.1607>.
- ¹⁸ Best KE, Tennant PW, Addor MC, et al. Epidemiology of small intestinal atresia in Europe: a register-based study. *Arch Dis Child Fetal Neonatal Ed*. 2012;97(5):F353–358. <https://doi.org/10.1136/fetalneonatal-2011-300631>.
- ¹⁹ Olsen B, Holck S. Neurogenous hyperplasia leading to appendiceal obliteration: an immunohistochemical study of 237 cases. *Histopathology*. 1987;11(8):843–849. <https://doi.org/10.1111/j.1365-2559.1987.tb01887.x>.
- ²⁰ Choi SJ, Jang YJ, Lee D, et al. Two cases of fibrous obliteration of the appendix, mimicking acute appendicitis. *J Korean Soc Radiol*. 2014;70(6):430–434. <http://dx.doi.org/10.3348/jksr.2014.70.6.430>.