



## Case Report

**Ventricular septal defect and free wall rupture as mechanical complications of myocardial infarction: case reports**

**Natalia Ogorzelec<sup>1</sup> , Maciej Bartczak<sup>1</sup>, Wojciech Sarnowski<sup>1</sup>, Radosław Smoczyński<sup>1</sup>,  
Jakub Brączkowski<sup>1</sup>, Robert Julian Gil<sup>2</sup>, Piotr Suwalski<sup>1</sup>**

<sup>1</sup> Department of Cardiac Surgery and Transplantology, National Medical Institute of the Ministry of Interior and Administration, Warsaw, Poland

<sup>2</sup> Department of Cardiology, National Medical Institute of the Ministry of Interior and Administration, Warsaw, Poland

## ARTICLE INFO

## Article history

Received: July 28, 2024

Accepted: January 23, 2025

Available online: April 22, 2025

## Keywords

pseudoaneurysm

VSD

Dor procedure

Asai technique

FWR

## Doi

<https://doi.org/10.29089/paom/200437>

## User license

This work is licensed under a  
Creative Commons Attribution –  
NonCommercial – NoDerivatives  
4.0 International License.



## ABSTRACT

**Introduction:** Mechanical complications of myocardial infarction (MI), such as free wall rupture (FWR) and post-myocardial infarction ventricular septal defect (post-MI VSD), are associated with a high mortality rate. In most cases, urgent surgical treatment is necessary.

**Aim:** This publication aims to present the surgical methods of treating post-MI VSD and chronic FWR.

**Case report:** We present the case of a 74-year-old patient with post-MI VSD who underwent VSD closure using the Asai technique and a 59-year-old patient with chronic FWR and left ventricular pseudoaneurysm who underwent aneurysm resection and the Dor procedure for left ventricular reconstruction.

**Results and discussion:** The choice of optimal timing and treatment method depends on the damage type and the patient's hemodynamic stability.

**Conclusions:** The treatment of choice is urgent cardiac surgery. In hemodynamically stable patients, deferred surgery may be performed to improve intraoperative conditions.

## 1. INTRODUCTION

Mechanical complications of myocardial infarction (MI), although rare, are associated with a high mortality rate.<sup>1</sup> These include, among others, post-myocardial infarction ventricular septal defect (post-MI VSD) and free wall rupture (FWR). Ventricular septal rupture occurs in approximately 1% of patients with STEMI and is the cause of death in approximately 5% of patients with MI.<sup>2</sup> The rupture is generally associated with full-thickness MI, and most often occurs within the 1st week after infarction. The damage is usually located at the border between the healthy and ischaemic parts of the septum. The treatment of choice is surgical closure of the VSD. In hemodynamically unstable patients with features of acute heart failure, urgent surgery is indicated, whereas, in hemodynamically stable patients, surgery may be postponed to optimize intraoperative conditions and improve prognosis.<sup>3</sup> The mortality rate without surgical intervention is approximately 90%.<sup>2</sup>

FWR is one of the most fatal complications of MI. The rupture most frequently involves the anterior wall and is associated with extensive full-thickness MI.<sup>4</sup> In the acute type, the mortality rate is nearly 100%, and the diagnosis is often made at post-mortem examination.<sup>5</sup> The treatment of choice is surgical management. Nevertheless, the operative mortality rate is high.<sup>6</sup> In the chronic FWR, a pseudoaneurysm is formed, and the condition may be asymptomatic.

Commonly, surgical management is recommended for large and symptomatic pseudoaneurysms detected up to 3 months after MI.<sup>7</sup>

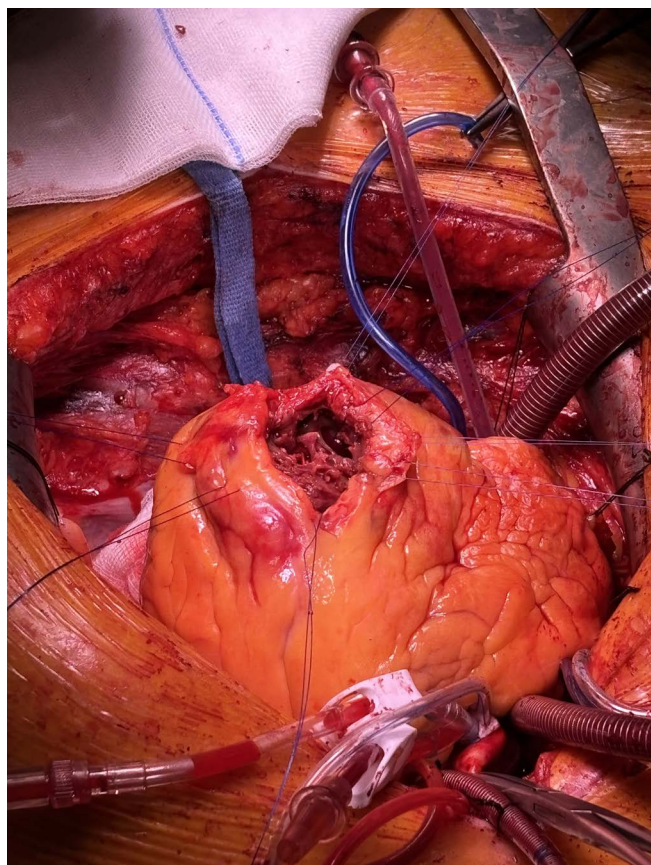
## 2. AIM

This publication aims to present the surgical methods of treating mechanical complications of MI, such as post-infarction VSD and chronic FWR.

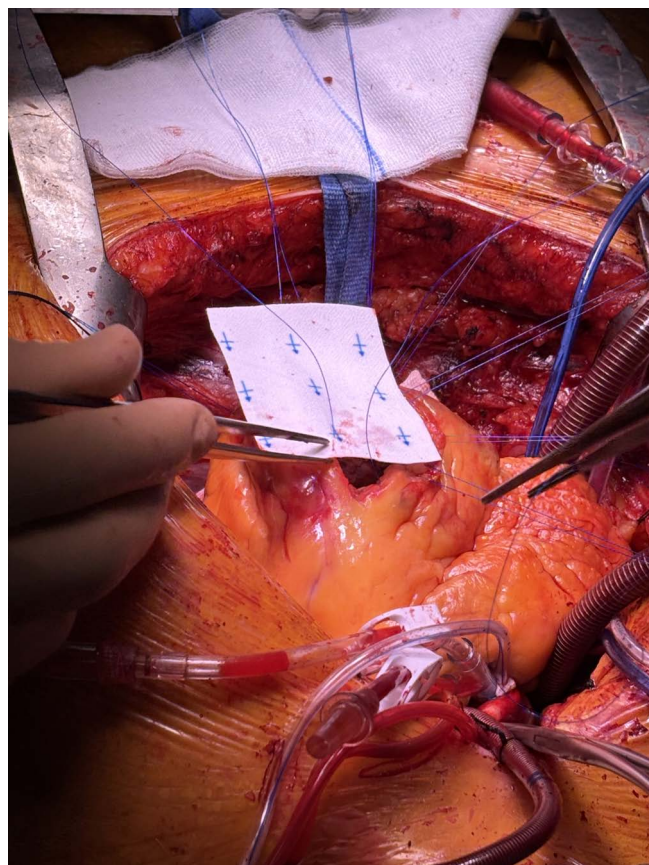
## 3. CASE REPORTS

### 3.1. Case 1

A 74-year-old patient was urgently referred to the Department of Cardiac Surgery from an external center due to a post-infarction defect in the apical part of the interventricular septum. The patient's medical history included single-vessel coronary artery disease, full-thickness anterior wall MI, and left anterior descending artery angioplasty with implantation of two drug-eluting stents. A transthoracic echocardiogram visualized a periapical area of contractile dysfunction. In the apical segment of the interventricular septum, an approximately 11 mm VSD with a left-right shunt was visualized. The left ventricle ejection fraction was 60%, and no significant valvular abnormalities were revealed.



**Figure 1.** The right ventricle incision over the systolic murmur and visualization of the VSD.

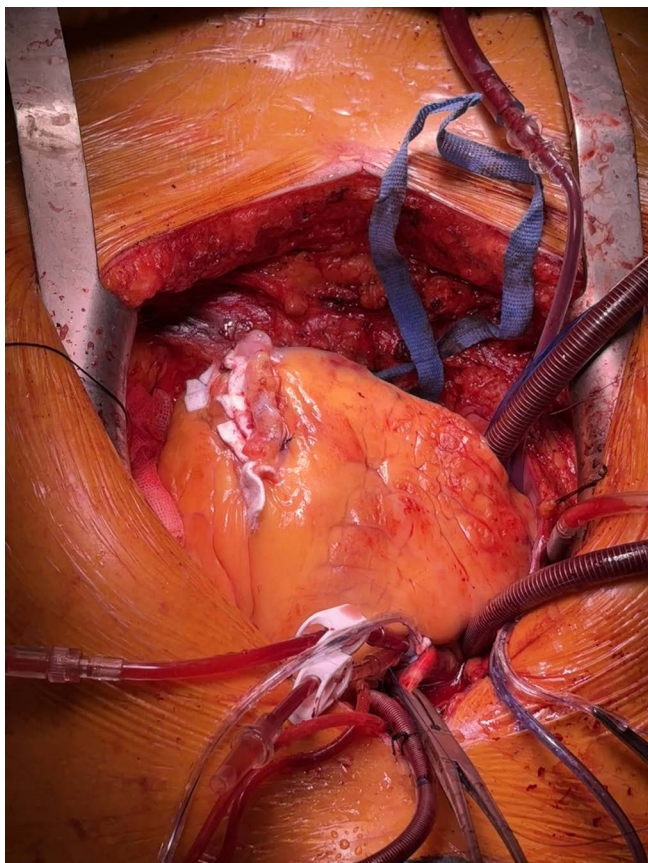


**Figure 2.** Placement of the second patch from the right ventricular side.

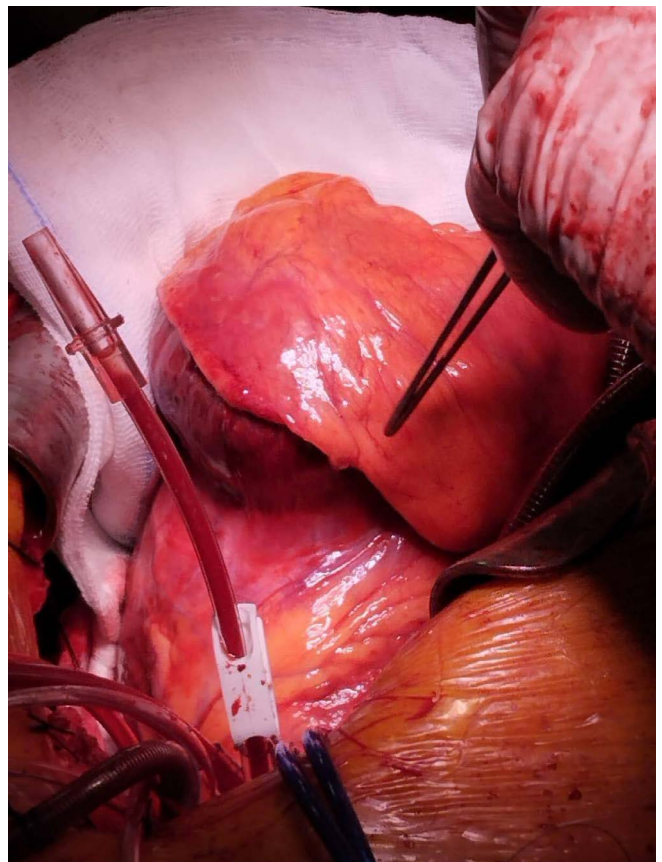


Due to hemodynamic stability, the patient was qualified for deferred VSD closure surgery (2 weeks after MI). The procedure was carried out with extracorporeal circulation and Del Nido cardioplegia. The right ventricle was incised over the systolic murmur. VSD was visualized going from the apex, spiraling upwards (Figure 1). The septal necrosis was excised. Using the Asai technique, a Gore-Tex patch was sewn from the left ventricular side. A second patch was placed on the right ventricular side, and tissue glue was administered in between (Figure 2). The right ventricle was closed with felt strips (Figure 3). Intraoperative transoesophageal echocardiography did not visualize any signs of leakage.

The patient was extubated on the 2nd postoperative day. During the stay in the intensive care unit, the patient received catecholamines, diuretics, prophylactic doses of low molecular weight heparin, acetylsalicylic acid, clopidogrel, proton pump inhibitors, and antihypertensive medications; moreover respiratory physiotherapy and rehabilitation were initiated. In the postoperative period, the patient developed pneumonia, successfully treated with antibiotics. There were no other significant postoperative complications. The patient was transferred to the Cardiology Department on the 8th postoperative day in good general condition. During the 10-month follow-up, the patient reported no procedure-related complications and maintained good general condition.



**Figure 3.** Final result: Closure of the right ventricle with felt strips and sutures.



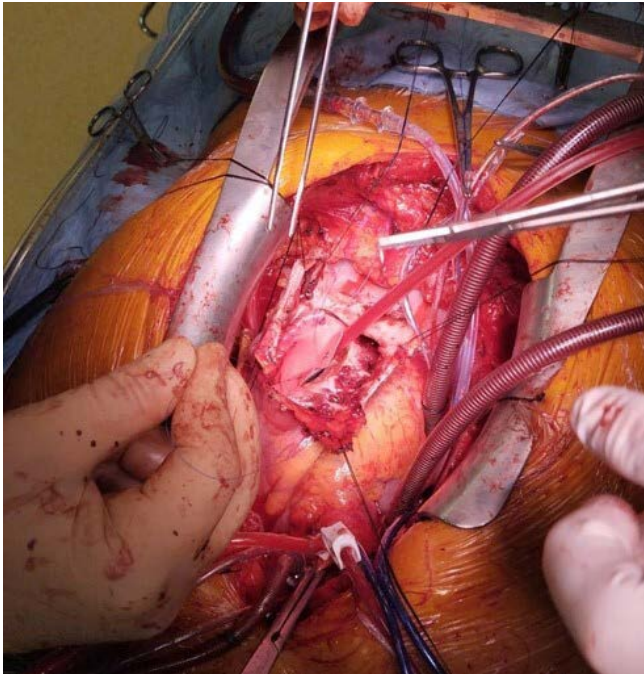
**Figure 4.** Giant left ventricular pseudoaneurysm the size of a man's fist with a fibrotic entrance to the left ventricle.

### 3.2. Case 2

A 59-year-old patient was referred to the Department of Cardiac Surgery from an external center due to a post-infarction left ventricular pseudoaneurysm. The patient's medical history included an anterior wall MI treated conservatively, as well as deterioration of exercise tolerance and episodes of dyspnoea following MI. Computed tomography of the chest revealed a left ventricular wall rupture with a  $73 \times 68 \times 61$  mm apical bulge, consistent with a pseudoaneurysm, along with a 35 mm entry and simultaneous contrast of the left ventricle and aneurysm lumen. Transthoracic echocardiography did not reveal any significant valvular abnormalities, left ventricle ejection fraction was 43%.

The patient was qualified for aneurysm resection and the Dor procedure for left ventricular reconstruction. The procedure was carried out with extracorporeal circulation and Del Nido cardioplegia. Intraoperatively, a giant left ventricular pseudoaneurysm extending to the left pleura was visualized (Figure 4). The aneurysm was incised at the apex, and thrombi adhering to its walls were removed. At the base, a fibrotic entrance to the left ventricle was visualized. The aneurysm was removed, then the sutures surrounding the transition zone between the contractile myocardium and the pseudoaneurysm tissue were placed, and the Gore-Tex patch was sewn. The left ventricular opening was closed with sutures and felt strips (Figures 5 and 6).





**Figure 5. Sewing of the patch.**

The patient was extubated on the 1st postoperative day. During the stay in the intensive care unit, the patient received catecholamines, beta-blockers, diuretics, prophylactic doses of low molecular weight heparin, acetylsalicylic acid, clopidogrel, proton pump inhibitors, and antihypertensive medications; likewise the previous patient, the respiratory physiotherapy and rehabilitation were initiated. In the postoperative transthoracic echocardiography, no features of cardiac tamponade were visualized, and no impaired cardiac valves function was revealed. On the 6th postoperative day, the patient was discharged in good general condition with a therapeutic regimen including hypolipidemic, antihypertensive, and antiplatelet agents. During the 10-month follow-up, the patient reported no procedure-related complications and maintained good general condition.

#### 4. RESULTS AND DISCUSSION

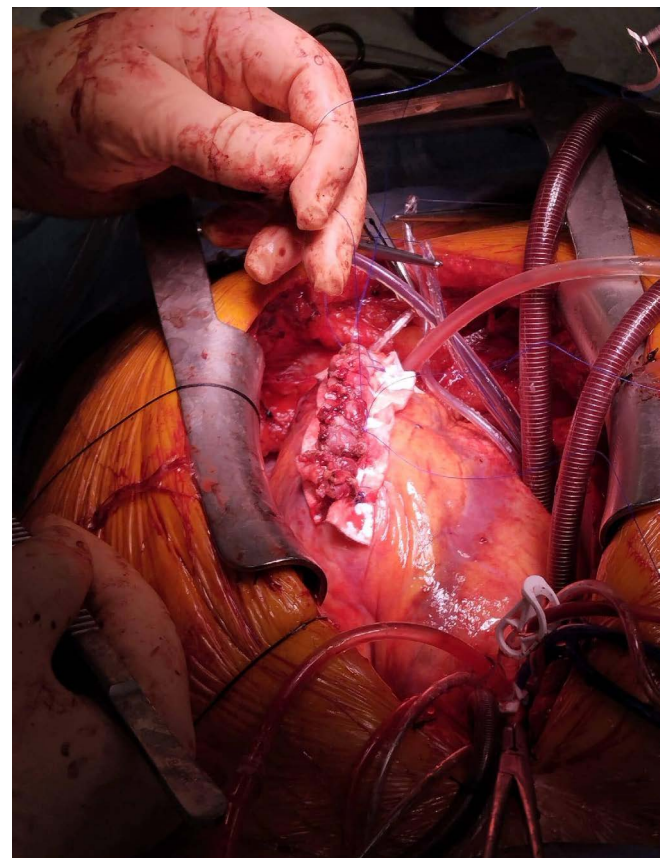
The optimal surgical timing depends mostly on the patient's hemodynamic stability. The procedure deferment improves intraoperative conditions as the myocardium tissue is of poor quality directly after the MI. However, in the majority of cases, the patient's initial condition is severe, and the operation must be performed urgently.

VSD repair method is determined by the location and size of the defect. Small defects can be closed with sutures, while larger ones require a patch. The Asai technique allows VSD closure through the right ventricular approach, without incising the left ventricular wall. Closure of the VSD is provided by creating a 'sandwich' double patch using mattress sutures. The method is safe and effective, and shunt recurrence is rare.<sup>8,9</sup>

In FWR, the method of choice is closing the rupture with sutures and prosthetic patches. The use of surgical glues and collagen sponge patches is also possible.<sup>10</sup> The Dor Procedure is a surgical option in patients with post-infarction left ventricular pseudoaneurysms. The method is based on reshaping the left ventricle with a suture surrounding the transition zone between the contractile myocardium and the pseudoaneurysm tissue and reconstructing the continuity of the wall with a patch.<sup>11</sup> The early and long-term results of the Dor Procedure in treating post-infarction pseudoaneurysms are relatively good as Sartipy et al. reported early mortality rate of 8%, and actuarial survival rates of 88%, 79%, and 65% consecutively at 1, 3 and 5-year follow-up.<sup>12</sup>

#### 6. CONCLUSIONS

1. The treatment of choice for mechanical complications of MI is urgent cardiac surgery. Nevertheless, the prognosis in hemodynamically unstable patients with features of acute heart failure is poor.
2. The optimal management strategy, under feasible conditions, is preoperative stabilization of the patient's condition.
3. In hemodynamically stable patients, deferred surgery may be performed to improve intraoperative conditions, tissue quality, and prognosis.



**Figure 6. Final result: Reshaped left ventricle and reconstructed wall continuity.**

## Conflict of interest

The authors declare no conflict of interest.

## Funding

None declared.

## References

- <sup>1</sup> Bajaj A, Sethi A, Rathor P, Suppogu N, Sethi A. Acute Complications of Myocardial Infarction in the Current Era: Diagnosis and Management. *J Investig Med*. 2015;63(7):844–855. <https://doi.org/10.1097/jim.0000000000000232>.
- <sup>2</sup> Topaz O, Taylor AL. Interventricular septal rupture complicating acute myocardial infarction: From pathophysiologic features to the role of invasive and noninvasive diagnostic modalities in current management. *Am J Med*. 1992;93(6):683–688. [https://doi.org/10.1016/0002-9343\(92\)90203-n](https://doi.org/10.1016/0002-9343(92)90203-n).
- <sup>3</sup> Staromłyński J, Bartczak M, Suwalski P. Mechanical complications of myocardial infarction [in Polish]. *Kardiologia Inwazyjna*. 2017;12(6):19–23.
- <sup>4</sup> Griffith GC, Hegde B, Oblath RW. Factors in myocardial rupture. *Am J Cardiol*. 1961;8(6):792–798. [https://doi.org/10.1016/0002-9149\(61\)90241-7](https://doi.org/10.1016/0002-9149(61)90241-7).
- <sup>5</sup> Kerr F, Haywood LJ. Myocardial rupture in acute myocardial infarction: report of experience and review. *J Natl Med Assoc*. 1978;70(5):325–330.
- <sup>6</sup> Matteucci M, Formica F, Kowalewski M, et al. Meta-analysis of surgical treatment for postinfarction left ventricular free-wall rupture. *J Card Surg*. 2021;36(9):3326–3333. <https://doi.org/10.1111%2Fjocs.15701>.
- <sup>7</sup> Iosifescu AG, Iosifescu TA, Timisescu AT, Antohi EL, Iliescu VA. Left Ventricular Pseudoaneurysms Discovered Early After Acute Myocardial Infarction: The Surgical Timing Dilemma. *Tex Heart Inst J*. 2022;49(5):e207462. <https://doi.org/10.14503/thij-20-7462>.
- <sup>8</sup> Asai T, Hosoba S, Suzuki T, Kinoshita T. Postinfarction Ventricular Septal Defect: Right Ventricular Approach—The Extended “Sandwich” Patch. *Semin Thorac Cardiovasc Surg*. 2012;24(1):59–62. <https://doi.org/10.1053/j.semtcvs.2011.12.005>.
- <sup>9</sup> Asai T, Kinoshita T, Oishi A, Hachiro K, Suzuki T, Vigers P. Extended sandwich patch technique to repair ventricular septal rupture. *Ann Cardiothorac Surg*. 2022;11(3):337–339. <https://doi.org/10.21037/acs-2021-ami-164>.
- <sup>10</sup> Matteucci M, Fina D, Jiritano F, et al. Treatment strategies for post-infarction left ventricular free-wall rupture. *Eur Heart J Acute Cardiovasc Care*. 2019;8(4):379–387. <https://doi.org/10.1177/2048872619840876>.
- <sup>11</sup> Menicanti L, Di Donato M. The Dor procedure: What has changed after fifteen years of clinical practice? *J Thorac Cardiovasc Surg*. 2002;124(5):886–890. <https://doi.org/10.1067/mtc.2002.129140>.
- <sup>12</sup> Sartipy U, Albage A, Lindblom D. The Dor procedure for left ventricular reconstruction. Ten-year clinical experience. *Eur J Cardiothorac Surg*. 2005;27(6):1005–1010. <https://doi.org/10.1016/j.ejcts.2005.01.055>.