



Case Report

A novel modification of negative pressure wound therapy in the management of enteroatmospheric fistulas

Kenny Yao Choong Ng¹, Firdaus Hayati², Khairul Hazim Bin Hamdan¹

¹Department of Surgery, Selayang Hospital, Malaysia

²Department of Surgery, Faculty of Medicine and Health Science, Universiti Malaysia Sabah, Malaysia

ARTICLE INFO

Article history

Received: December 16, 2024

Accepted: March 25, 2025

Available online: December 8, 2025

Keywords

Enterocutaneous fistula

Negative-pressure wound therapy

Occlusive dressing

Wound closure techniques

Doi

<https://doi.org/10.29089/paom/203320>

User license

This work is licensed under

a [Creative Commons Attribution –](#)

[NonCommercial – NoDerivatives](#)

[4.0 International License](#).



ABSTRACT

Introduction: Enteroatmospheric fistula (EAF) is a serious postoperative complication encountered by surgeons all over the world. This condition brings upon a lot of physical, mental and emotional distress to the patients. The management of EAF is often multimodal and requires careful planning.

Aim: We would like to report a case of EAF post laparotomy successfully treated with a novel technique of the standard negative-pressure wound therapy (NPWT).

Case study: Our patient is a 58-year-old woman who developed an EAF after undergoing two laparotomies with bowel resections for colonic polyps. Her wound was assessed and she was deemed unsuitable for further surgeries due to her frail condition and the condition of the wound. We opted for a conservative treatment. She was then managed in our centre with NPWT dressings.

Results and discussion: After undergoing multiple cycles of NPWT dressings, the patient's wound improved considerably with satisfying results. Her general well being and septic parameters had improved. The NPWT assisted in the decrease in size and closure of the abdominal wound, allowing for easier isolation and handling of the fistula.

Conclusions: NPWT has been proven to be a valuable and effective treatment in the management of complex abdominal fistulas. In patients who are not suitable for surgical closure, NPWT should be considered as an adjunct in the management of their wounds.

1. INTRODUCTION

An enteroatmospheric fistula (EAF) is a rare but serious postoperative complication of a burst abdomen where there is a direct pathway of communication between the bowel and environment with the absence of surrounding skin.¹ It is also known as an open abdominal fistula. Unlike enterocutaneous fistulae, EAFs have neither overlying soft tissue nor a real fistula tract, which reduces the likelihood of their spontaneous closure.^{1,2} EAFs often present a big challenge to the surgeon with regards to its management and the subsequent rehabilitation of the patient. The increasingly widespread use of open abdomen techniques for the initial treatment of abdominal sepsis and trauma has led to the increase in the incidence of EAF. Various factors can contribute to the development of wound dehiscence. In this case, we believe an anastomotic leak itself was a main trigger. It subsequently led to a stormy recovery complicated with acute renal failure, sepsis, and multiorgan dysfunction. Because of their clinical complexity, the proper management of enteric fistula requires a multidisciplinary team.

Negative-pressure wound therapy (NPWT) has been gaining popularity as an adjunct in the management of patients with EAF. Even NPWT is contraindicated in certain conditions, including the presence of malignancy within the wound, necrotic tissue, active bleeding, inadequate tissue perfusion, and severe infection. Additionally, NPWT is not recommended for cases involving unexposed anatomical structures, particularly anastomotic sites and underlying bowel. Our technique, however, challenges this conventional limitation. We present a case of EAF treated successfully with a novel modification of the NPWT, avoiding the need for surgical intervention.

2. AIM

This article highlights the multimodal treatment strategy to treat EAF post laparotomy using NPWT.

3. CASE STUDY

Our patient is a 58-year-old woman who was referred from another centre after undergoing multiple surgeries for suspicious colonic polyps. She initially had a laparoscopic converted to open total colectomy with ileorectal anastomosis. Post operatively she developed an anastomotic leak and underwent a relaparotomy with end ileostomy and rectal stump. She had a stormy recovery in intensive care post operatively complicated with acute renal failure, sepsis, multi organ dysfunction and developed an EAF (Figure 1). After a few days in her treatment centre, she was then facing substantial financial difficulties. The patient was then transferred to our centre for further management and care.

We continued with a third surgery for her which was a wound debridement, washout and vacuum dressing.

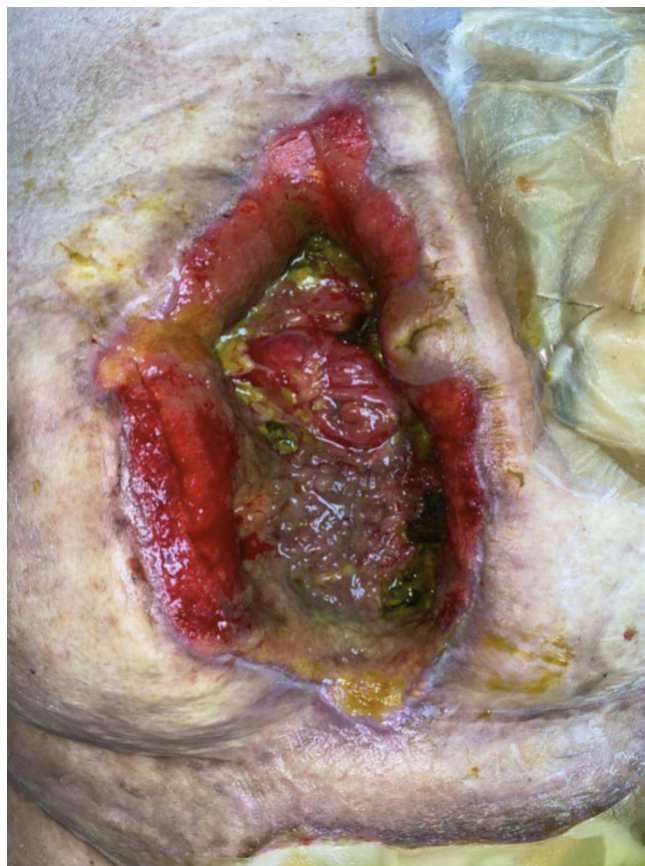


Figure 1. There was a huge defect from previous laparotomy wound with exposed small bowel openings and presence of bilious discharge suggestive of an EAF.

Intraoperative findings noted bile contamination in laparotomy wounds. We found a cocoon abdomen with a sloughy surface all over the wound. Intraoperatively, it was discovered that she had EAF with multiple openings at the open abdomen. We were then able to divert the opening of the EAF away from the open abdomen via a combination of Foley's catheters and a modified milk bottle teat NPWT system (Figure 2). This prevents faecal contamination onto the open abdomen wound which can negatively affect the healing process.

After a total of 6 cycles of NPWT, her wound is healing well with healthy granulation tissue forming. Clinically, the patient has also improved as seen with better lab parameters and improving nutritional status. Her septic parameters such as her white cell count, and CRP are improving and we were able to wean her off inotropic support. The patient's wound healed considerably with reasonable healing and decrease in size of the fistula. The open abdominal wound has decreased in size and can be managed with simple gauze and normal saline dressing. At the time of writing, the patient's EAF is now drained and diverted from the open abdominal wound with a simple corrugated sheet drain.³ The midline abdominal wound that was left open previously was then able to be closed with secondary suturing, providing a more cosmetically satisfying result.

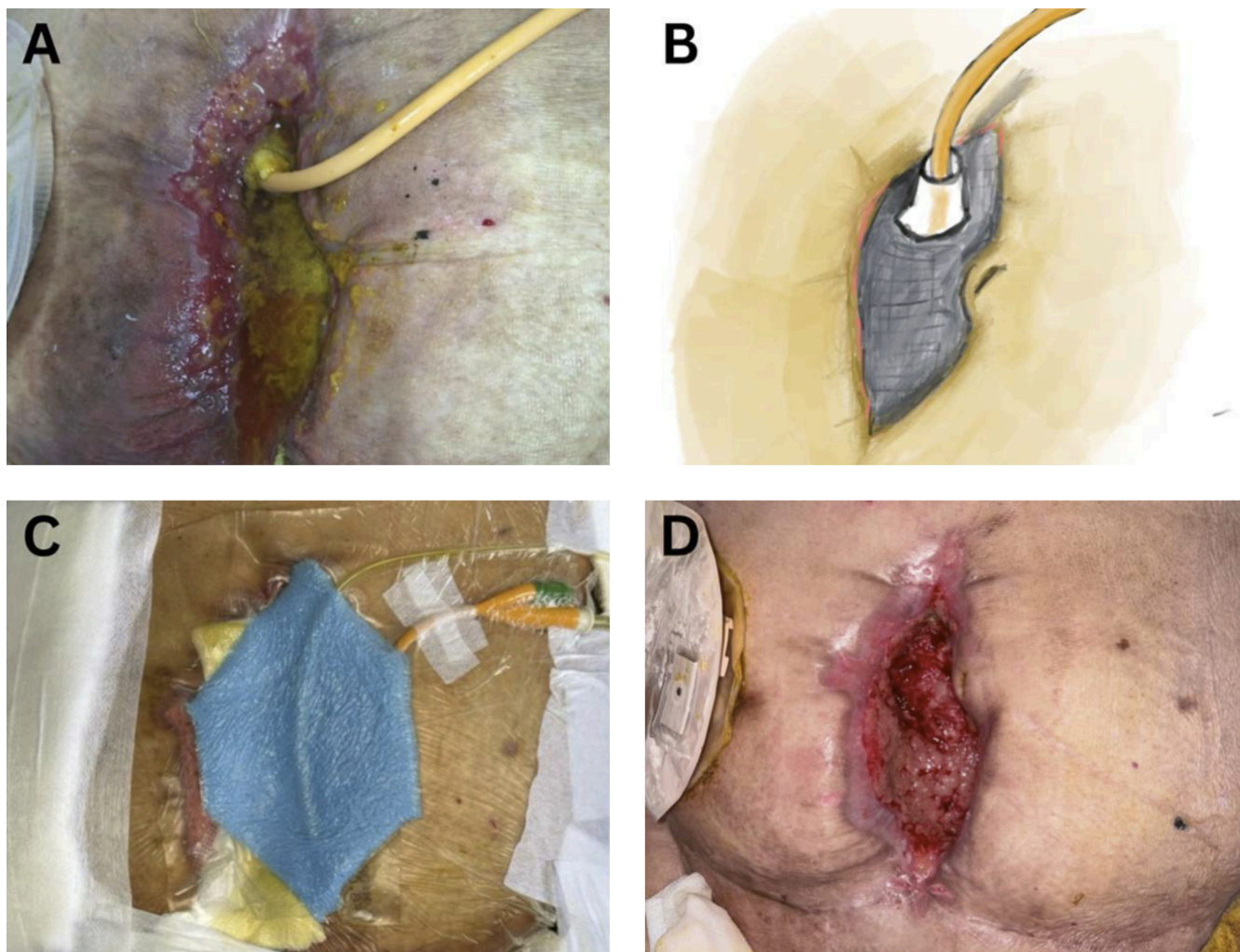


Figure 2. The bilious contamination created by the EAF was controlled by inserting Foley's catheter into the small bowel openings (A). The schematic diagram showed a combination of Foley's catheters, modified milk bottle teat and polyurethane ether sponge to create a functional NPWT (B). The final result of the NPWT (C). The EAF defect had shrunk remarkably after a few cycles of NPWT (D).

4. RESULTS AND DISCUSSION

EAF poses a large challenge for surgeons as it requires meticulous planning and complex wound management techniques.³ The fundamental pillars for fistula, initially described by Chapman, can be characterised by the SOWATS acronym: management of the septic condition, optimisation of the nutritional status, surgical wound care, fistula anatomy, right timing for surgery, and Surgical strategy.¹ By adopting this strategy, EAF mortality was reduced from 40% down to 15%.⁴ The management strategy in EAF should include temporary local control of effluent to prevent spillage of enteric contents on the surrounding tissues, good nutritional support, and optimisation of the patient for a major and complex surgeries.⁵

Local control and containment of contamination is difficult for EAF as it is hard to apply an effective collective system such as an ostomy bag around the wound. The constant

leakage of bowel effluents onto the surrounding granulation tissue can present wide variation of adverse effects such as worsening infections and the formation of new fistulas.⁶ In this patient, we manage to circumvent this issue by placing a baby bottle nipple VAC around the EAF and passing a catheter through the tip of the nipple. This helps to ensure that effluent spillage onto surrounding granulation tissue is kept to a minimum and the wound bed is kept as clean as possible. Furthermore, we also adopted a multidisciplinary whole patient approach in the management of this patient. She was started on parenteral nutrition in order to boost her nutritional status which will then aid in wound healing and resolution of the fistulas.

Despite advances in perioperative care and nutritional support, the mortality of EAFs remains in the range of 15 to 30%.⁴ In more recent years, the use of negative pressure wound therapy for the resolution of enteric fistulas improved the outcomes, so patients can be successfully treated with

a non-operative approach, further reducing the mortality and morbidity associated with open abdominal surgeries.⁵ NPWT uses the application of negative pressure through an abdominal sponge to remove fluid and infectious material away from the surgery wound. In cases where the abdomen is left open post-operatively, the NPWT system consists of a sterile abdominal sponge with overlying fenestrated plastic covering which is fitted inside the peritoneal cavity covering the abdominal contents. Next, another sponge is applied according to the size of the wound. The final layer consists of an adherent dressing over the sponge and a tubing which connects to a portable suction device. In this patient, we were able to avoid another laparotomy by utilising the principles of NPWT. A conservative approach was then successfully adopted in the treatment course of this patient.

The NPWT system has many proven benefits over conventional dressing methods. NPWT has been proven to promote faster wound healing as well as reduce exudates and edema, improving the viability of the wound bed. In recent years, NPWT has been gaining traction and popularity in the management and dressing of the open abdomen and healing by secondary intention. However, it is also important to note that the NPWT system too has its disadvantages such as bleeding, prolonged hospital stay, skin irritation and increased care complexity due to the nature of NPWT. NPWT has also been explored as a preventive measure in certain cases. It can help reduce surgical site infections, particularly in high-risk patients, minimise seroma and haematoma formation by managing post-surgical drainage, and improve wound healing by enhancing blood flow and oxygenation. However, NPWT is not suitable for all patients, especially those with poor tissue perfusion, active infections, or exposed vital structures. Its cost-effectiveness and long-term benefits as a prophylactic tool are still being studied, and more research is needed to establish standardised guidelines for its use.

5. CONCLUSIONS

- (1) NPWT can be used to manage EAF in patients who are not suitable for surgical intervention, promoting wound healing and reducing morbidity.
- (2) Innovative NPWT techniques, such as using a baby bottle nipple and Foley's catheter to divert effluent, help prevent contamination and enhance healing.

- (3) Successful EAF management requires a holistic approach, including infection control, nutritional optimisation, and wound care, as outlined by the SOWATS strategy.

Conflict of interest

Authors declare that there is no conflict of interest.

Funding

None declared.

Acknowledgements

We would like to thank our colleagues from the surgical department of Hospital Selayang for their continuous and unwavering support in the publishing of this article.

References

- 1 Scott-Conner CEH, Kaiser AM, Nguyen NT, Sarpel U, Sugg SL. *Chassin's Operative Strategy in General Surgery, An Expositive Atlas*. 5th Ed. Cham: Springer; 2022:355–365.
- 2 Przudzik M, Derkaczew M, Hofman R, Roslan M. Therapeutic difficulties in vesicorectal fistula treatment using several techniques in one center. *Pol Ann Med*. 2022; 29(2):131–135. <https://doi.org/10.29089/2021.21.00209>.
- 3 Brunnicardi F, Andersen DK, Billiar TR, et al. *Schwartz's Principles of Surgery*. 11th Ed. Columbus, OH: McGraw Hill; 2019:1240–1242.
- 4 English CJ, Sodade OE, Austin CL, Hall JL, Draper BB. Management of Enteroatmospheric Fistula (EAF) Using a Fistula-Vacuum Assisted Closure (VAC) in a Complicated Abdominal Trauma Case. *Cureus*. 2023;15(4):e37668. <https://doi.org/10.7759/cureus.37668>.
- 5 Marinis A, Gkiokas G, Argyra E, Fragulidis G, Polymeneas G, Voros D. 'Enteroatmospheric fistulae' – gastrointestinal openings in the open abdomen: A review and recent proposal of a surgical technique. *Scand J Surg*. 2013;102(2): 61–68. <https://doi.org/10.1177/1457496913482252>.
- 6 Wirth U, Renz BW, Andrade D, et al. Successful treatment of enteroatmospheric fistulas in combination with negative pressure wound therapy: Experience on 3 cases and literature review. *Int Wound J*. 2018;15(5):722–730. <https://doi.org/10.1111/iwj.12916>.